



PATIENT

Lexi Berkovic

SPECIES

Canine

BREED

Lab x

SEX

Spayed Female

AGE

12 Years

WEIGHT

41 kg

INTERPRETED BY

Dr Brittany Sinclair,
 BVSc(hons),
 DACVECC

IMAGING PERFORMED BY

Kelly Reschny

HOSPITAL NAME

Snelgrove VS

REFERRING VET

Dr. JI

INVOICE

71625

DATE

11/6/25

PRESENTING CLINICAL SIGNS

Went to King Animal hospital for severe diarrhea. They palpated a large mass in the abdomen. Current Medications Metacam

Abnormal PE/Chem/CBC/UA Results: Slight increase in ALK

ULTRASONOGRAPHIC EXAMINATION OF THE ABDOMEN

Urinary System

The urinary bladder, trigone, and visible pelvic urethra were of normal thickness. The ureters were not visible which is normal. There was normal wall layering with no masses, uroliths or abnormal thickening visualized. Urine was anechoic. No evidence of inflammatory or neoplastic changes were noted.

The left kidney presents normal size and structure, with smooth capsule and normal corticomedullary definition and ratio. Medullary structure differed distinctly from that of the cortex. No evidence of pelvic dilation was present. Hyperechoic, shadowing foci present in renal parenchyma and calyces consistent with nephrocalcinosis. Left kidney measures 7.22 cm.

The kidneys have an irregular capsule and with hazing of corticomedullary definition to the point of inability to determine cortical/medullary ratio. No evidence of pelvic dilation was present. Area of indentation in renal capsule with underlying triangular shaped hyperechoic parenchyma consistent with an area of previous infarct. Right kidney measured significantly smaller than the left kidney at 5.52 cm, consistent with atrophy.

Adrenal Glands

The left adrenal gland is visualized and recognized as having normal shape, size, position and echogenicity for this breed and age. The visible phrenic vasculature was unremarkable. Left measures 3.12 cm in length x 0.80 cm at the caudal pole and 0.94 cm at the cranial pole.

The right adrenal gland is visualized and measured on still images only. Resolution is inadequate to assess glandular detail or confirm measurement. Right measures 2.15 cm in length x 1.02 cm at the caudal pole and 1.85 cm at the cranial pole.

Spleen

The spleen was normal in size with a mottled parenchyma and smooth capsule. Normal splenic vasculature with no signs of congestion or thrombosis.

Liver

The liver is subjectively normal in size with normal contours and structure. The parenchyma is heterogenous with a coarse appearance. There are multifocal hyperechoic and hypoechoic nodules in the liver lobes. There are no distinct masses seen. Vascular and biliary tracts are of normal volume with no evidence of congestion. No pathological hepatic lymphadenopathy observed.

Gall bladder is moderately distended with normal wall thickness and anechoic contents. Common bile duct is non-distended and tapers normally.



PATIENT

Lexi Berkovic

Gastrointestinal

The stomach is not distinctly visualized. There is a mass effect in the area of the stomach, but it also goes more caudally than normal stomach and may not be gastric in origin.

SPECIES

Canine

The visualized areas of duodenum, jejunum and ileum have a relatively uniform diameter with minimal fluid distension. Wall thickness is normal. Bowel loops follow a curvilinear path with distinct wall layering maintaining the typical 1:3 muscularis:mucosa layer ratio. There were no focal lesions consistent with obstruction or a mass effect observed.

BREED

Lab x

The ileocecal junction was not visualized. Sections of colon are visualized with gas shadowing distally. There is no observed focal or generalized colon wall thickening or loss of layering.

SEX

Spayed Female

Pancreas

The pancreas is not distinctly visualized.

AGE

12 Years

Lymph Nodes

No clinically significant lymphadenopathy or abnormalities noted.

WEIGHT

41 kg

Free Abdomen

In the cranial to mid abdomen there is a complex mass effect that measures approximately 6.6 cm in diameter. There is irregular, layered, hyperechoic striations throughout the mass, which are causing distal shadowing, obstructing full visualization of the margins of the mass. Definitive organ of origin is not determined.

INTERPRETED BY

Dr Brittany Sinclair,
 BVSc(hons),
 DACVECC

ULTRASONOGRAPHIC FINDINGS

- Complex mid abdominal mass – organ of origin not determined.
- Mottled spleen – likely aging change.
- Atrophied right kidney – incidental chronic change.
- Coarse liver with nodules.

IMAGING PERFORMED BY

Kelly Reschny

INTERPRETATION OF THE FINDINGS & FURTHER RECOMMENDATIONS

HOSPITAL NAME

Snelgrove VS

The organ of origin of the mid abdominal mass is not identified. It has some features consistent with a GI mass including significant shadowing and distal attenuation of ultrasound beam, but a distinct lumen or intestinal attachment could not be identified. FNA of the mass is recommended to further define. Abdominal CT and/or abdominal explore could also be considered.

REFERRING VET

Dr. JI

Liver changes are a common benign age related change and may also represent infiltrative inflammatory or regenerative nodules. They don't have an overt appearance of metastatic nodules, but this cannot be definitively ruled out. Liver aspirates should be considered. If surgery is pursued, liver biopsy is recommended.

INVOICE

71625

DATE

11/6/25

Splenic changes are a common benign age related change, but infiltrative disease (lymphoma, MCT, other) cannot be definitively ruled out. No significant disruption of architecture noted to suggest significant pathology. Fine needle aspirate could be considered to further characterize parenchymal changes if clinically indicated, especially if any weight loss is noted or for baseline cytological assessment.



PATIENT

Lexi Berkovic

SPECIES

Canine

BREED

Lab x

SEX

Spayed Female

AGE

12 Years

WEIGHT

41 kg

INTERPRETED BY

Dr Brittany Sinclair,
BVSc(hons),
DACVECC

IMAGING PERFORMED BY

Kelly Reschny

HOSPITAL NAME

Snelgrove VS

REFERRING VET

Dr. JI

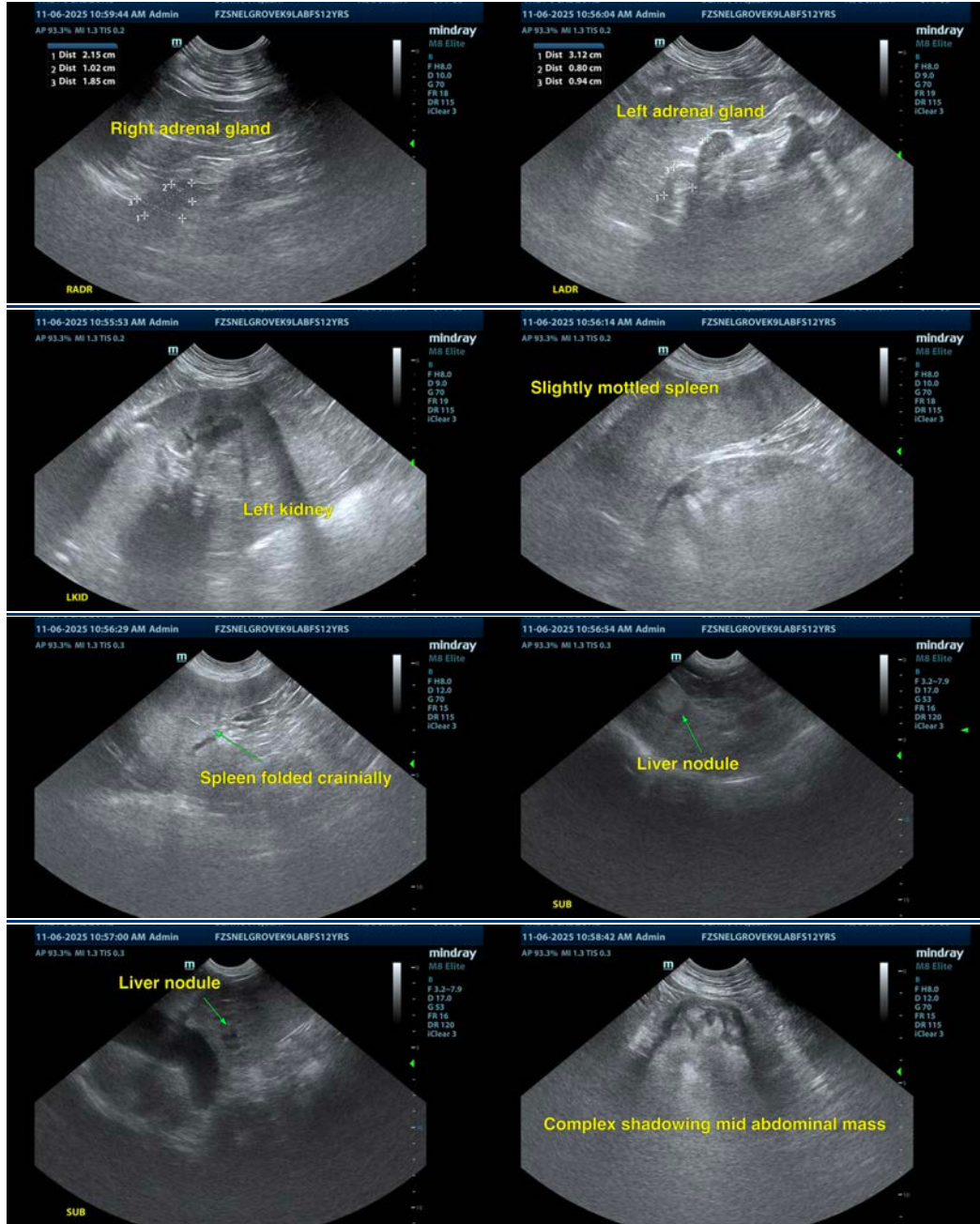
INVOICE

71625

DATE

11/6/25

Right renal atrophy is likely due to previous renal insult. In the absence of azotemia, it is likely an incidental finding. Continue to correlate clinical significance with semiannual bloodwork and urinalysis.





PATIENT

Lexi Berkovic

SPECIES

Canine

BREED

Lab x

SEX

Spayed Female

AGE

12 Years

WEIGHT

41 kg

INTERPRETED BY

Dr Brittany Sinclair,
BVSc(hons),
DACVECC

IMAGING PERFORMED BY

Kelly Reschny

HOSPITAL NAME

Snelgrove VS

REFERRING VET

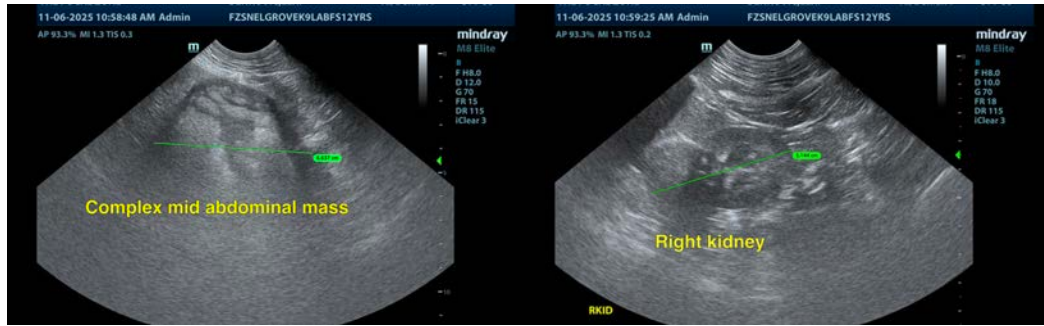
Dr. JI

INVOICE

71625

DATE

11/6/25



The information and recommendations provided are based on the images presented by the referring veterinarian/sonographer. No evaluation can be communicated regarding pathology that was not visible in the image/video clips provided.

Thank you for this referral. If the clinical or image interpretation does not parallel your findings or if I can be of any further assistance please contact me.

Dr Brittany Sinclair, BVSc(hons), DACVECC

info@SonoPath.com