



PATIENT

Romeo DaCosta

SPECIES

Canine

BREED

Doberman

SEX

Neutered Male

AGE

4 Years

WEIGHT

32.7 kg

INTERPRETED BY

Dr Brittany Sinclair,
 BVSc(hons),
 DACVECC

IMAGING PERFORMED BY

Amanda Stewart

HOSPITAL NAME

Wellington Animal
 Hospital

REFERRING VET

Dr. Dennis

INVOICE

71990

DATE

11/20/25

PRESENTING CLINICAL SIGNS

Intermittent episodes of gulping, which then seem to drive him to chew random things (blankets) and then his flanks Frequency has improved with change in diet to RC GI, last episode was after grabbing a cracker from the ground Current Medications None

Abnormal PE/Chem/CBC/UA Results: Primary Question to Be Answered in This Exam Reasons for GI issues, have discussed with owner that this is likely IBD or a diet sensitivity See attached

ULTRASONOGRAPHIC EXAMINATION OF THE ABDOMEN

Urinary System

The urinary bladder, trigone, and visible pelvic urethra were of normal thickness. The ureters were not visible which is normal. There was normal wall layering with no masses, uroliths or abnormal thickening visualized. Urine was anechoic. No evidence of inflammatory or neoplastic changes were noted.

The kidneys were both normal size and structure, with smooth capsule and normal corticomedullary definition and ratio. Medullary structure differed distinctly from that of the cortex. No evidence of pelvic dilation was present. Left kidney measures 6.5 cm. Right kidney measures 6.44 cm.

Adrenal Glands

The left adrenal gland is visualized and recognized as having normal shape, size, position and echogenicity for this breed and age. The visible phrenic vasculature was unremarkable. Left measures 2.38 cm in length x 0.54 cm at the caudal pole and 0.63 cm at the cranial pole.

The right adrenal gland is visualized on still images only. It appears to have normal shape, size, position and echogenicity for this breed and age though this could not be confirmed on cine loops. Right measures 1.81 cm in length x 0.74 cm at the caudal pole and 1.73 cm at the cranial pole.

Spleen

The spleen was normal with age appropriate homogeneous parenchyma and a smooth capsule with normal splenic vasculature with no signs of congestion or thrombosis. No sonographic evidence of acute or chronic inflammatory, neoplastic, or infarct changes were noted.

Liver

The liver is subjectively normal in size with normal contours and structure. There is age appropriate echogenicity and echotexture. No overt structural evidence of inflammatory, infiltrative or regenerative pathology is evident. Vascular and biliary tracts are of normal volume with no evidence of congestion.

Gall bladder is moderately distended with normal wall thickness and anechoic contents. Common bile duct is non-distended and tapers normally.

Gastrointestinal

The stomach contains minimal luminal contents. It measures at a normal thickness of with some variability due to the presence of rugal folds. The distinction of the gastric wall layers is adequate. No masses or focal lesions were observed.

The visualized areas of duodenum, jejunum and ileum have a relatively uniform diameter with minimal fluid distension. Wall thickness is normal. Bowel loops follow a curvilinear path with distinct wall



PATIENT

Romeo DaCosta

SPECIES

Canine

BREED

Doberman

SEX

Neutered Male

AGE

4 Years

WEIGHT

32.7 kg

INTERPRETED BY

Dr Brittany Sinclair,
 BVSc(hons),
 DACVECC

IMAGING PERFORMED BY

Amanda Stewart

HOSPITAL NAME

Wellington Animal
 Hospital

REFERRING VET

Dr. Dennis

INVOICE

71990

DATE

11/20/25

layering maintaining the typical 1:3 muscularis:mucosa layer ratio. There were no focal lesions consistent with obstruction or a mass effect observed.

The ileocecal junction was not visualized. Sections of colon are visualized with formed fecal material and gas shadowing distally. There is no observed focal or generalized colon wall thickening or loss of layering.

Pancreas

The area of the pancreas was isoechoic to surrounding tissue with no overt inflammation. Pancreatic tissue was not distinctly visualized which is common.

Lymph Nodes

No clinically significant lymphadenopathy or abnormalities noted.

Free Abdomen

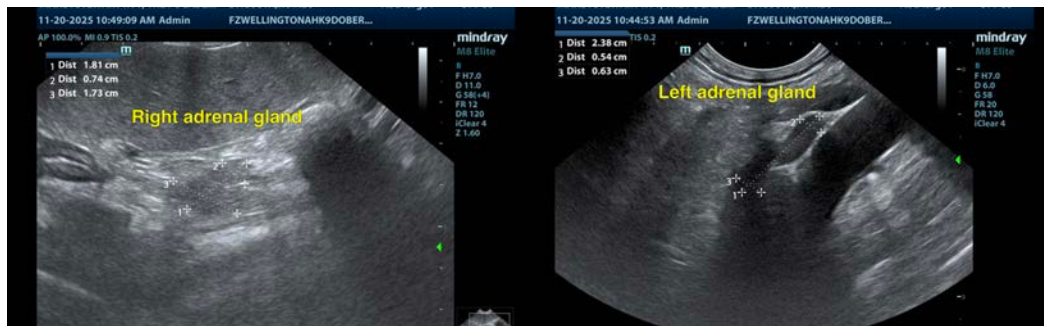
No masses or free fluid were noted.

ULTRASONOGRAPHIC FINDINGS

- Unremarkable abdomen.

INTERPRETATION OF THE FINDINGS & FURTHER RECOMMENDATIONS

There is no ultrasonographically evident cause of reported GI signs in this abdominal study. Pancreas and GI tract are within normal limits. Consideration for dietary indiscretion, infectious etiologies (bacterial, viral, parasitic), food sensitivity/allergy or mild inflammatory bowel disease is reasonable. While not sonographically evident, pancreatitis cannot be completely ruled out. Empiric treatment for GI signs including anti-nausea, appetite stimulant and fluid support as clinically indicated is warranted. A diet trial with hydrolyzed protein or select protein diet could be considered if food sensitivity is suspected clinically. If signs are persistent or recurrent, additional diagnostics to be considered include baseline cortisol +/- ACTH stimulation test, GI panel (TLI/PLI/cobalamin/folate), fecal pathogen panel, thyroid testing, bile acid profile, and thoracic radiographs to rule out occult neoplasia, cardiac disease and esophageal disease as potential causes. Ultimately GI biopsy may be required for more definitive diagnosis if the patient is not responsive to medical treatment.





PATIENT

Romeo DaCosta

SPECIES

Canine

BREED

Doberman

SEX

Neutered Male

AGE

4 Years

WEIGHT

32.7 kg

INTERPRETED BY

Dr Brittany Sinclair,
 BVSc(hons),
 DACVECC

IMAGING PERFORMED BY

Amanda Stewart

HOSPITAL NAME

Wellington Animal
 Hospital

REFERRING VET

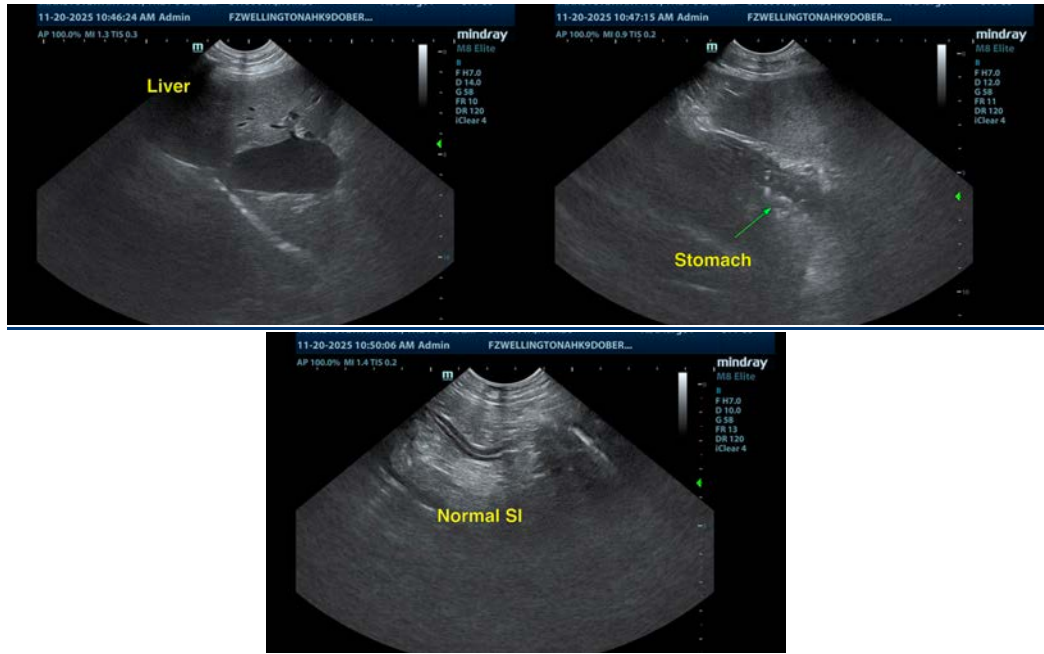
Dr. Dennis

INVOICE

71990

DATE

11/20/25



The information and recommendations provided are based on the images presented by the referring veterinarian/sonographer. No evaluation can be communicated regarding pathology that was not visible in the image/video clips provided.

Thank you for this referral. If the clinical or image interpretation does not parallel your findings or if I can be of any further assistance please contact me.

Dr Brittany Sinclair, BVSc(hons), DACVECC

info@SonoPath.com