



PATIENT

Murdock Chinn

SPECIES

Canine

BREED

Havanese

SEX

Neutered Male

AGE

12 Years 5 Months

WEIGHT

4.3 kg

INTERPRETED BY

Dr Brittany Sinclair,
BVSc(hons),
DACVECC

IMAGING PERFORMED BY

Dr. Brian Barnes

HOSPITAL NAME

Westview Veterinary
Hospital

REFERRING VET

Dr. Brian Barnes

INVOICE

71767

DATE

11/13/25

PRESENTING CLINICAL SIGNS

1) Mild bilateral elbow arthritis. 2) Mild arthritis of the left radiocarpal joint with synovitis. 3) Progressive lameness with CP deficit Right front leg 3) Focal tracheal collapse in an otherwise unremarkable geriatric thorax. 4) Cystic calculi in an otherwise unremarkable abdomen. 5) Mild anemia 6) Hematuria 7) Calcium oxalate crystalluria 9) CP deficits RF and RRleg 10) Apparent resolution of the bladder stones, were small passed 11) Increasing Liver enzymes ALT and ALKP

Abnormal PE/Chem/CBC/UA Results: Dogs RF leg has got progressively worse in the last few days. Now has a CP deficit moderate RF, and mild RR The bladder stones that were present on last Xray Sept 26, 2025 are now gone. Suspect a very slight cardiac murmur

ULTRASONOGRAPHIC EXAMINATION OF THE ABDOMEN

Urinary System

The urinary bladder, trigone, and visible pelvic urethra were of normal thickness. The ureters were not visible which is normal. There was normal wall layering with no masses, uroliths or abnormal thickening visualized. Urine was anechoic. No evidence of inflammatory or neoplastic changes were noted.

The kidneys were both normal size and structure, with smooth capsule and normal corticomedullary definition and ratio. Medullary structure differed distinctly from that of the cortex. No evidence of pelvic dilation was present. The left kidney measures 3.94 cm in length. The right kidney measures 4.27 cm in length.

Adrenal Glands

The kidneys have a smooth capsule and with hazing of corticomedullary definition to the point of inability to determine cortical/medullary ratio. No evidence of pelvic dilation was present. Hyperechoic, shadowing foci present bilaterally in renal parenchyma and calyces consistent with nephrocalcinosis. Left measures 1.44 cm in length x 0.49 cm at the caudal pole and 0.46 cm at the cranial pole. Right measures 1.63 cm in length x 0.37 cm at the caudal pole and 0.52 cm at the cranial pole.

Spleen

The spleen was normal with age appropriate homogeneous parenchyma and a smooth capsule with normal splenic vasculature with no signs of congestion or thrombosis. No sonographic evidence of acute or chronic inflammatory, neoplastic, or infarct changes were noted.

Liver

The liver is subjectively normal in size with normal contours and structure. There is age appropriate echogenicity and echotexture. No overt structural evidence of inflammatory, infiltrative or regenerative pathology is evident. Vascular and biliary tracts are of normal volume with no evidence of congestion.

The gall bladder is moderately distended with anechoic fluid, with hyperechoic non-shadowing gravity dependent debris present. There is no surrounding free fluid or signs of active inflammation.

Gastrointestinal

The stomach contains minimal luminal contents. It measures at a normal thickness of with some variability due to the presence of rugal folds. The distinction of the gastric wall layers is adequate. No masses or focal lesions were observed.



PATIENT

Murdock Chinn

SPECIES

Canine

BREED

Havanese

SEX

Neutered Male

AGE

12 Years 5 Months

WEIGHT

4.3 kg

INTERPRETED BY

Dr Brittany Sinclair,
BVSc(hons),
DACVECC

IMAGING PERFORMED BY

Dr. Brian Barnes

HOSPITAL NAME

Westview Veterinary
Hospital

REFERRING VET

Dr. Brian Barnes

INVOICE

71767

DATE

11/13/25

The visualized areas of duodenum, jejunum and ileum have a relatively uniform diameter with minimal fluid distension. Wall thickness is normal. Bowel loops follow a curvilinear path with distinct wall layering maintaining the typical 1:3 muscularis:mucosa layer ratio. There were no focal lesions consistent with obstruction or a mass effect observed.

The ileocecal junction was not visualized. Visible descending colon contains echogenic material with small hyperechoic shadowing foci consistent with diarrhea with mineralized particles. There is no visible wall thickening or loss of wall layering.

Pancreas

The visible pancreas was observed to be largely isoechoic to surrounding omental fat.

Lymph Nodes

No clinically significant lymphadenopathy or abnormalities noted.

Free Abdomen

No masses or free fluid were noted.

ULTRASONOGRAPHIC FINDINGS

- Degenerative renal changes with mild nephrocalcinosis.
- Gallbladder debris.
- Normal liver parenchyma.
- Diarrhea in colon.

INTERPRETATION OF THE FINDINGS & FURTHER RECOMMENDATIONS

Gall bladder debris may be an incidental finding given lack of surrounding inflammation. In the face of elevated ALKP ursodiol could be given as a choleric and empiric treatments (SAM-E, milk thistle, Vitamin E) could be tried. If liver supportive medications do not improve liver enzymes, a course of empiric antibiotics (clavamox, enrofloxacin) could be considered to cover for infectious cholangiohepatitis, though the lack of surrounding inflammation makes this less likely. Imaging should be rechecked on a routine basis for monitoring (q3-6mo) or if further significant increase in liver enzymes and/or new clinical signs are noted. If otherwise clinically indicated, investigation for endocrinopathy such as hyperadrenocorticism or hypothyroidism could be considered as an underlying cause predisposing to gall bladder debris accumulation. Liver FNA should be considered given reported elevation in ALT despite normal parenchymal appearance.

Renal changes are likely age related degenerative changes. Correlate clinical significance with blood work/urinalysis findings and clinical signs. Nephroliths may act as a nidus of infection and predispose to urinary tract infections. They can also cause sterile inflammation leading to renal hematuria. They have the potential to move into the ureters or bladder causing obstructive uropathy.

Clinical significance of diarrhea is uncertain. GI panel (TLI/PL/cobalamin/folate/cortisol), fecal pathogen PCR, and empiric broad spectrum deworming and treatment with probiotics should be considered. An easily digestible GI diet with consideration for addition of extra fiber could be considered. If initial treatments are unsuccessful, treatment for dietary sensitivity/allergy could be considered which includes diet trial with either hydrolyzed or select protein diet, vitamin b-12 supplementation, and continued GI support as needed. Colonoscopy may reveal pathology not visible on ultrasound.



PATIENT

Murdock Chinn

SPECIES

Canine

BREED

Havanese

SEX

Neutered Male

AGE

12 Years 5 Months

WEIGHT

4.3 kg

INTERPRETED BY

Dr Brittany Sinclair,
BVSc(hons),
DACVECC

IMAGING PERFORMED BY

Dr. Brian Barnes

HOSPITAL NAME

Westview Veterinary
Hospital

REFERRING VET

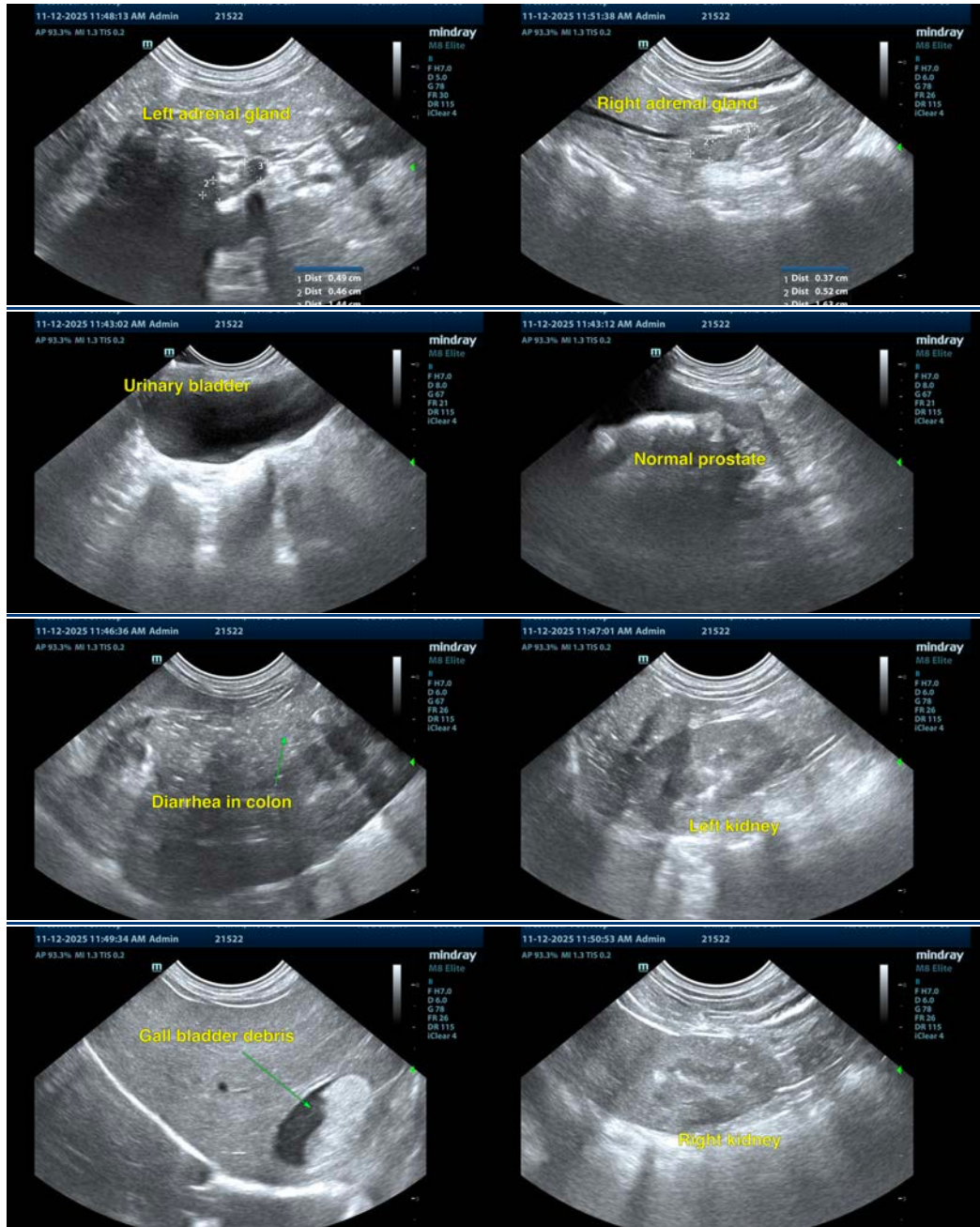
Dr. Brian Barnes

INVOICE

71767

DATE

11/13/25



The information and recommendations provided are based on the images presented by the referring veterinarian/sonographer. No evaluation can be communicated regarding pathology that was not visible in the image/video clips provided.

Thank you for this referral. If the clinical or image interpretation does not parallel your findings or if I can be of any further assistance please contact me.

Dr Brittany Sinclair, BVSc(hons), DACVECC info@SonoPath.com