



PATIENT

Kali Dell

SPECIES

Canine

BREED

Shepherd x

SEX

Spayed Female

AGE

7 Years

WEIGHT

42 kg

INTERPRETED BY

Dr Brittany Sinclair,
 BVSc(hons),
 DACVECC

IMAGING PERFORMED BY

Kelly Reschny

HOSPITAL NAME

Headon Forest Animal
 Hospital

REFERRING VET

Dr. Short

INVOICE

71728

DATE

11/12/25

PRESENTING CLINICAL SIGNS

Large swelling with heat appreciated with palpation at level of carpus -distal radius/ulna OVC is having a clinical trial for osteosarcomas and they require an abdominal ultrasound prior to starting. Current Medications amantadine, gaba, traz, Metacam

ULTRASONOGRAPHIC EXAMINATION OF THE ABDOMEN

Urinary System

The urinary bladder, trigone, and visible pelvic urethra were of normal thickness. The ureters were not visible which is normal. There was normal wall layering with no masses, uroliths or abnormal thickening visualized. Urine was anechoic. No evidence of inflammatory or neoplastic changes were noted.

The kidneys were both normal size and structure, with smooth capsule and normal corticomedullary definition and ratio. Medullary structure differed distinctly from that of the cortex. No evidence of pelvic dilation was present. Hyperechoic, shadowing foci present in renal parenchyma and calyces bilaterally, consistent with nephrocalcinosis. Left kidney measures 6.71 cm. Right kidney measures 7.12 cm. Visualization of the right kidney was significantly limited by overlying gas-filled GI tract.

Adrenal Glands

The left adrenal gland is visualized on still images only. It appears to have normal shape, size, position and echogenicity for this breed and age though this could not be confirmed on cine loops. Left adrenal gland measures 2.44 cm in length x 0.58 cm at the caudal pole and 0.73 cm at the cranial pole.

The right adrenal gland is visualized and measured on still images only. Resolution is inadequate to assess glandular detail or confirm measurement. Right adrenal gland measures 2.38 cm in length x 0.62 cm at the caudal pole and 1.35 cm at the cranial pole.

Spleen

The spleen was normal with age appropriate homogeneous parenchyma and a smooth capsule with normal splenic vasculature with no signs of congestion or thrombosis. No sonographic evidence of acute or chronic inflammatory, neoplastic, or infarct changes were noted.

Liver

The liver is subjectively normal in size with normal contours and structure. There is age appropriate echogenicity and echotexture. No overt structural evidence of inflammatory, infiltrative or regenerative pathology is evident. Vascular and biliary tracts are of normal volume with no evidence of congestion.

Gall bladder is moderately distended with normal wall thickness and anechoic contents. Common bile duct is non-distended and tapers normally.

Gastrointestinal

The stomach contains minimal luminal contents. It measures at a normal thickness of with some variability due to the presence of rugal folds. The distinction of the gastric wall layers is adequate. No masses or focal lesions were observed.

The visualized areas of duodenum, jejunum and ileum have a relatively uniform diameter with gas throughout with no overt distention. Wall thickness is normal. Bowel loops follow a curvilinear path



PATIENT

Kali Dell

SPECIES

Canine

BREED

Shepherd x

SEX

Spayed Female

AGE

7 Years

WEIGHT

42 kg

INTERPRETED BY

Dr Brittany Sinclair,
BVSc(hons),
DACVECC

IMAGING PERFORMED BY

Kelly Reschny

HOSPITAL NAME

Headon Forest Animal
Hospital

REFERRING VET

Dr. Short

INVOICE

71728

DATE

11/12/25

with distinct wall layering maintaining the typical 1:3 muscularis:mucosa layer ratio. There were no focal lesions consistent with obstruction or a mass effect observed.

The ileocecal junction was not visualized. Sections of colon are visualized with formed fecal material and gas shadowing distally. There is no observed focal or generalized colon wall thickening or loss of layering.

Pancreas

The area of the pancreas was isoechoic to surrounding tissue with no overt inflammation. Pancreatic tissue was not distinctly visualized which is common.

Lymph Nodes

No clinically significant lymphadenopathy or abnormalities noted.

Free Abdomen

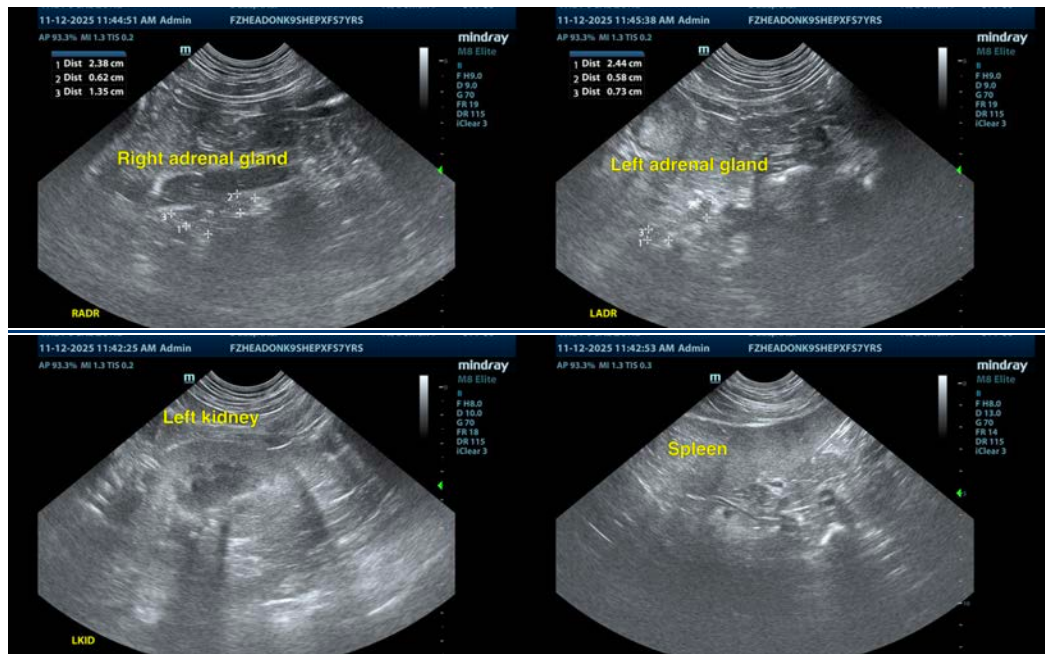
No masses or free fluid were noted.

ULTRASONOGRAPHIC FINDINGS

- Mild nephrocalcinosis bilaterally.
- Otherwise normal abdomen.

INTERPRETATION OF THE FINDINGS & FURTHER RECOMMENDATIONS

Renal changes are likely age related degeneration. Correlate clinical significance with semi-annual blood work/urinalysis findings and clinical signs.





PATIENT

Kali Dell

SPECIES

Canine

BREED

Shepherd x

SEX

Spayed Female

AGE

7 Years

WEIGHT

42 kg

INTERPRETED BY

Dr Brittany Sinclair,
BVSc(hons),
DACVECC

IMAGING PERFORMED BY

Kelly Reschny

HOSPITAL NAME

Headon Forest Animal
Hospital

REFERRING VET

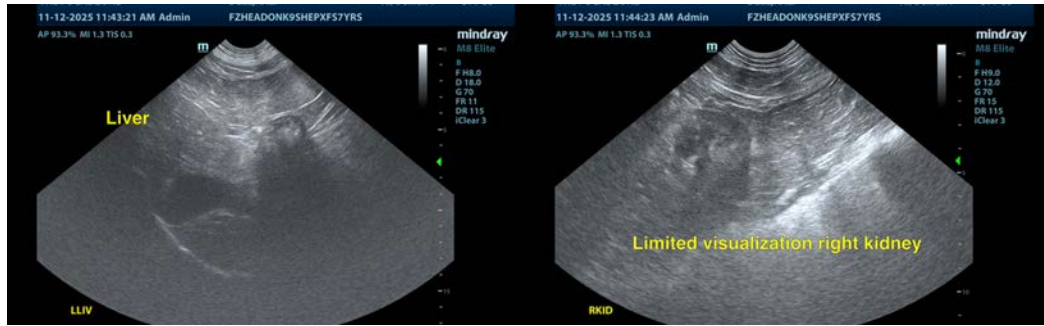
Dr. Short

INVOICE

71728

DATE

11/12/25



The information and recommendations provided are based on the images presented by the referring veterinarian/sonographer. No evaluation can be communicated regarding pathology that was not visible in the image/video clips provided.

Thank you for this referral. If the clinical or image interpretation does not parallel your findings or if I can be of any further assistance please contact me.

Dr Brittany Sinclair, BVSc(hons), DACVECC

info@SonoPath.com