



## PATIENT

Dexter Fidler

## SPECIES

Canine

## BREED

Mini Australian Shepherd

## SEX

Neutered Male

## AGE

12 years

## WEIGHT

26.3 kg

## INTERPRETED BY

Dr Brittany Sinclair,  
BVSc(hons),  
DACVECC

## IMAGING PERFORMED BY

Dr. Meghan Myers

## HOSPITAL NAME

Hershey Animal  
Emergency Center

## REFERRING VET

Dr. Cara Sinopoli

## INVOICE

11072

## DATE

1/9/2026

## PRESENTING CLINICAL SIGNS

Newly diagnosed diabetic (diagnosed 1/5/26). Started on Humulin N @ 7units. Unable to give consistently due to lack of appetite. 1/5/26 bloodwork also showed elevated ALT. Suspected pancreatitis but not confirmed. Anxious SNP on abdominal palpation. Inappetence. Painful and resistant to extension of hips, very still gait and doesn't want to walk far.

Abnormal PE/Chem/CBC/UA Results: EPOC- BG 653 Ketones at presentation- 0.8 Pancreatic lipase: 890 H.

## ULTRASONOGRAPHIC EXAMINATION OF THE ABDOMEN

### Urinary System

The urinary bladder, trigone, and visible pelvic urethra were of normal thickness. The ureters were not visible which is normal. There was normal wall layering with no masses, uroliths or abnormal thickening visualized. Urine was anechoic. No evidence of inflammatory or neoplastic changes were noted.

The left kidney has a smooth capsule and with hazing of corticomedullary definition to the point of inability to determine cortical/medullary ratio. No evidence of pelvic dilation was present. Hyperechoic, shadowing foci present in renal parenchyma and calyces consistent with nephrocalcinosis. Spherical anechoic fluid accumulation consistent with cortical cyst. The left kidney measures 6.41 cm in length.

The right kidney was normal in size and structure, with a smooth capsule and normal corticomedullary definition and ratio. Medullary structure differed distinctly from that of the cortex. No evidence of pelvic dilation was present. The right kidney measures 6.88 cm in length.

### Adrenal Glands

Both adrenal glands were visualized and recognized as having normal shape, size, position and echogenicity for this breed and age. The visible phrenic vasculature was unremarkable. Left adrenal gland measures 2.8 cm in length, 0.68 cm at the caudal pole and 0.52 cm at the cranial pole. Right adrenal gland measures 2.35 cm in length, 0.79 cm at the cranial pole and 0.40 cm at the caudal pole.

### Spleen

The spleen was normal with age appropriate homogeneous parenchyma and a smooth capsule with normal splenic vasculature with no signs of congestion or thrombosis. No sonographic evidence of acute or chronic inflammatory, neoplastic, or infarct changes were noted.

### Liver

The liver is subjectively enlarged with normal margins. Parenchyma is diffusely abnormal with multifocal variably sized hypoechoic nodules throughout. No specific masses are visualized.

Gall bladder is moderately distended with normal wall thickness and anechoic contents. Common bile duct is non-distended and tapers normally.

### Gastrointestinal



## PATIENT

Dexter Fidler

The stomach contains minimal luminal contents. It measures at a normal thickness of with some variability due to the presence of rugal folds. The distinction of the gastric wall layers is adequate. No masses or focal lesions were observed.

## SPECIES

Canine

The visualized areas of duodenum, jejunum and ileum have a relatively uniform diameter with minimal fluid distension. Wall thickness is normal. Bowel loops follow a curvilinear path with distinct wall layering maintaining the typical 1:3 muscularis:mucosa layer ratio. There were no focal lesions consistent with obstruction or a mass effect observed.

## BREED

Mini Australian Shepherd

The ileocecal junction was not visualized. Sections of colon are visualized with formed fecal material and gas shadowing distally. There is no observed focal or generalized colon wall thickening or loss of layering.

## SEX

Neutered Male

## Pancreas

The visible pancreas is diffusely enlarged and hypoechoic with an irregular capsular margin. The parenchyma is diffusely heterogenous with multifocal hypoechoic nodules throughout. Most consistent with cystic or nodular pancreatitis.

## AGE

12 years

## ULTRASONOGRAPHIC FINDINGS

## WEIGHT

26.3 kg

- Nodular/cystic pancreatitis.
- Diffusely abnormal liver parenchyma with diffuse liver nodules.
- Mild aging renal changes.

## INTERPRETED BY

Dr Brittany Sinclair,  
BVSc(hons),  
DACVECC

## INTERPRETATION OF THE FINDINGS & FURTHER RECOMMENDATIONS

Liver changes may represent reactive, regenerative or inflammatory changes, or infiltrative disease (lymphoma, MCT, other). They are likely at least partially chronic in nature but may represent an acute on chronic hepatopathy. Evaluation of a bile acid profile is recommended to further define the degree of liver dysfunction. Liver FNA is recommended to further characterize parenchymal changes. Ultimately liver biopsy is often required for more definitive diagnosis. Empiric treatments (SAM-E, milk thistle, Vitamin E, ursodiol) could be tried and liver enzymes re-evaluated, especially if liver FNA does not show significant pathology before more invasive liver sampling is pursued. Empiric antibiotic therapy is not unreasonable given severity of elevations and antibiotics that are effective against gram-negative, aerobic, enteric bacteria and excreted into the bile are recommended. Amoxicillin, amoxicillin-clavulanic acid, cephalosporins, and fluoroquinolones are suggested first choices. Metronidazole (7.5 mg/kg PO, IV q 12 hrs) may be added for extra anaerobe coverage.

## IMAGING PERFORMED BY

Dr. Meghan Myers

Pancreatic changes are consistent with severe pancreatitis. The severity of pancreatic changes may also reflect chronic episodes of pancreatitis with significant remodeling. Pancreatic neoplasia cannot be completely excluded but there are no focal lesions consistent with pancreatic mass visible. The prognosis of acute pancreatitis is largely dependent on the severity of clinical signs and response to treatment. Mortality is reported as high as 25% and secondary organ dysfunction and systemic inflammatory response syndrome can occur as inflammation progresses. Ultrasonographically, pancreatic inflammation is severe in this patient. Ultimately the need for hospitalization for treatment is based on the patient's cardiovascular stability, pain and appetite. Hydration and enteral nutrition are key factors in positive outcomes and if these cannot be achieved on an outpatient basis, hospitalization for 24 hour care is strongly recommended.

## HOSPITAL NAME

Hershey Animal  
Emergency Center

## REFERRING VET

Dr. Cara Sinopoli

## INVOICE

11072

## DATE

1/9/2026

Treatment for pancreatitis is entirely supportive and involves fluid support, GI support - anti-nausea (ondansetron, cerenia 2mg/kg PO SID), appetite stimulation (mirtazapine, elura), analgesia



## PATIENT

Dexter Fidler

## SPECIES

Canine

## BREED

Mini Australian Shepherd

## SEX

Neutered Male

## AGE

12 years

## WEIGHT

26.3 kg

## INTERPRETED BY

Dr Brittany Sinclair,  
BVSc(hons),  
DACVECC

## IMAGING PERFORMED BY

Dr. Meghan Myers

## HOSPITAL NAME

Hershey Animal  
Emergency Center

## REFERRING VET

Dr. Cara Sinopoli

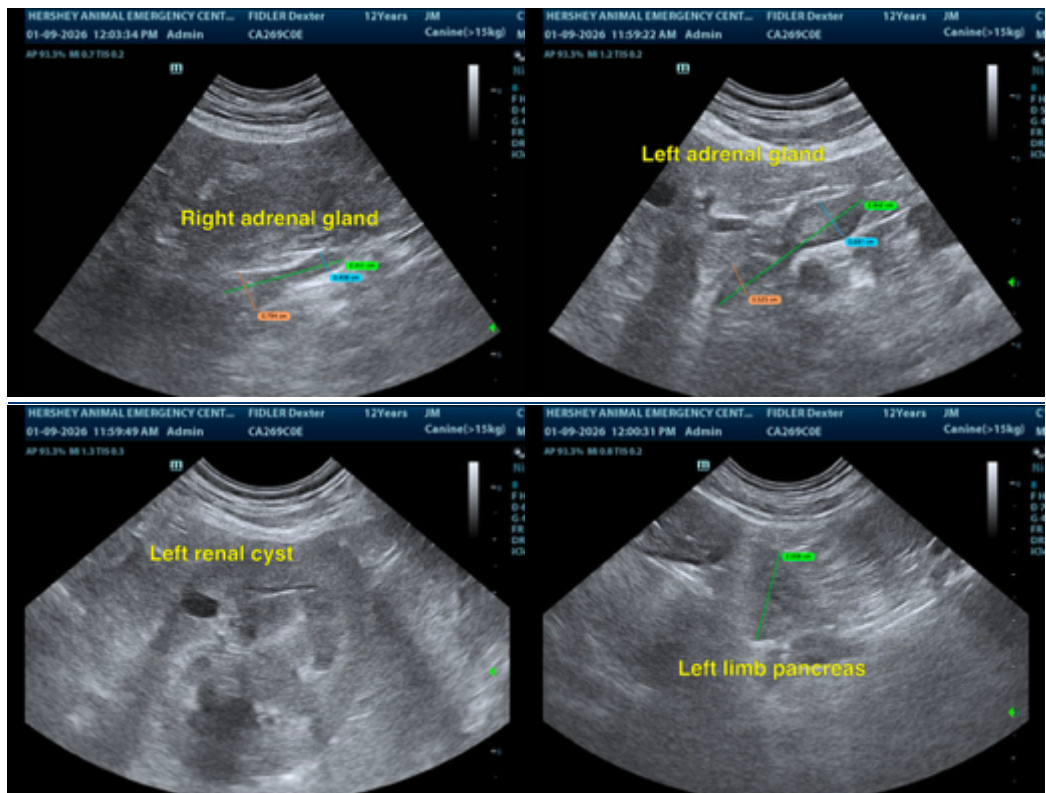
## INVOICE

11072

## DATE

1/9/2026

(buprenorphine, gabapentin) and enteral nutrition as needed (syringe feeding, NG tube placement, etc). Given diabetic ketosis, glucose management with insulin therapy is indicated. Panoquel could be considered if available and deemed clinically warranted. Antibiotics are generally not warranted for acute pancreatitis as it is usually sterile, however given the severity of inflammation and presence of possible fluid accumulation, I would use antibiotics (ex unasyn +/- fluoroquinolone) in this case. Intravenous antibiotics are preferred to ensure absorption and decrease GI side effects of oral antibiotics which can lower appetite compromising treatment and recovery. Anti-inflammatory steroids may be tried in an attempt to reduce inflammation if traditional supportive care is inadequate. Serial imaging is indicated to monitor response to treatment.





## PATIENT

Dexter Fidler

## SPECIES

Canine

## BREED

Mini Australian Shepherd

## SEX

Neutered Male

## AGE

12 years

## WEIGHT

26.3 kg

## INTERPRETED BY

Dr Brittany Sinclair,  
BVSc(hons),  
DACVECC

## IMAGING PERFORMED BY

Dr. Meghan Myers

## HOSPITAL NAME

Hershey Animal  
Emergency Center

## REFERRING VET

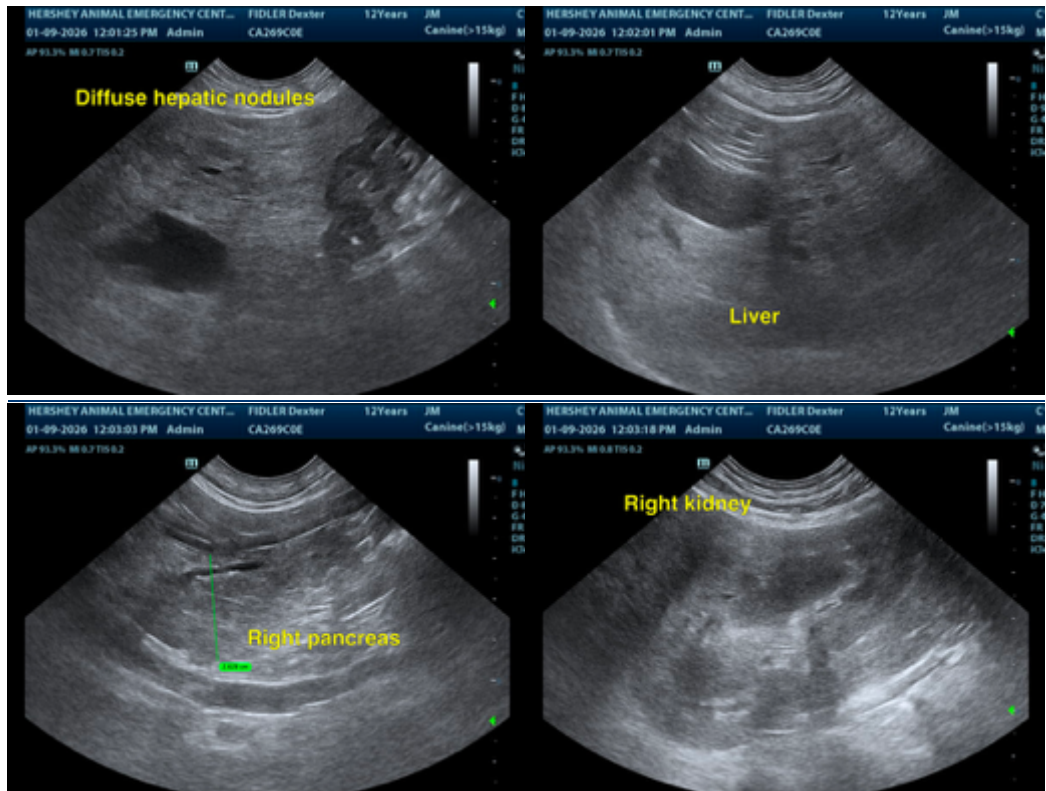
Dr. Cara Sinopoli

## INVOICE

11072

## DATE

1/9/2026



The information and recommendations provided are based on the images presented by the referring veterinarian/sonographer. No evaluation can be communicated regarding pathology that was not visible in the image/video clips provided.

Thank you for this referral. If the clinical or image interpretation does not parallel your findings or if I can be of any further assistance please contact me.

Dr Brittany Sinclair, BVSc(hons), DACVECC

info@SonoPath.com