



PATIENT

Amy Winehouse
 Ferrara

SPECIES

Canine

BREED

Maltese

SEX

Spayed Female

AGE

15 Years

WEIGHT

15.8 pounds

INTERPRETED BY

Dr Brittany Sinclair,
 BVSc(hons), DACVECC

IMAGING PERFORMED BY

Kelly Reschny

HOSPITAL NAME

Dog and Cat Clinic of
 Niagara

REFERRING VET

Dr. Snieder

INVOICE

13403

DATE

01/26/26

PRESENTING CLINICAL SIGNS

- in for bloodwork which shows elevation in kidney and liver values, also elevation in ALT/ALP/Phosphorus
- Current Medications: Metronidazole 50 mg, Ursodiol 75 mg, Aventi Kidney, Denamarin 225 mg

Abnormal PE/Chem/CBC/UA Results: labs attached

ULTRASONOGRAPHIC EXAMINATION OF THE ABDOMEN

Urinary System

The urinary bladder, trigone, and visible pelvic urethra were of normal thickness. The ureters were not visible which is normal. There was normal wall layering with no masses, uroliths or abnormal thickening visualized. Urine was anechoic. No evidence of inflammatory or neoplastic changes were noted.

The kidneys were both normal size and structure, with smooth capsule and normal corticomedullary definition and ratio (cortex 1/3 of medulla). Medullary structure differed distinctly from that of the cortex. Hyperechoic, shadowing foci present in renal parenchyma and calyces consistent with nephrocalcinosis. The right kidney measured 4.54 cm in length. The left kidney measured 4.5 cm in length.

Adrenal Glands

Both adrenal glands were visualized and recognized. Both were subjectively prominent. No specific masses or nodules seen. The phrenic vasculature, glandular echogenicity and detail were unremarkable. The left adrenal gland measured 1.56 cm in length and 0.51 cm at the cranial pole and 0.57 cm at the caudal pole. The right adrenal gland measured 1.74 cm in length and 1.0 cm at the cranial pole and 0.55 cm at the caudal pole.

Spleen

The spleen had hyperechoic pinpoint foci throughout consistent with hyperechoic stippling suggestive of dystrophic mineralization. It had a smooth capsule with normal splenic vasculature with no signs of congestion or thrombosis. There were no specific masses or nodules seen.

Liver

The liver is diffusely enlarged. Echotexture is slightly heterogeneous with a coarse appearance. There are multifocal, variably sized, somewhat poorly defined hypoechoic nodules throughout parenchyma.

The gall bladder is distended with organized hyperechoic non-gravity dependent, non-shadowing debris with a stellate appearance on its periphery most consistent with a gall bladder mucocele.

Gastrointestinal

The stomach is distended with gas and ingesta. It measures at a normal thickness with some variability due to the presence of rugal folds. The distinction of the gastric wall layers is adequate and there is no impression of reduced peristaltic activity. No masses or focal lesions were observed.



PATIENT

Amy Winehouse
Ferrara

SPECIES

Canine

BREED

Maltese

SEX

Spayed Female

AGE

15 Years

WEIGHT

15.8 pounds

INTERPRETED BY

Dr Brittany Sinclair,
BVSc(hons), DACVECC

IMAGING PERFORMED BY

Kelly Reschny

HOSPITAL NAME

Dog and Cat Clinic of
Niagara

REFERRING VET

Dr. Snieder

INVOICE

13403

DATE

01/26/26

The visualized areas of duodenum, jejunum and ileum have a relatively uniform diameter with gas and ingesta throughout. Wall thickness is normal. Bowel loops follow a curvilinear path with distinct wall layering maintaining the typical 1:3 muscularis: mucosa layer ratio. Visualized peristalsis appears appropriate. There were no focal lesions consistent with obstruction or a mass effect observed.

The ileocecal junction was not visualized. Sections of colon are visualized with formed fecal material and gas shadowing distally. There is no observed focal or generalized colon wall thickening or loss of layering.

Pancreas

The area of the pancreas was isoechoic to surrounding tissue with no overt inflammation. Pancreatic tissue was not distinctly visualized which is common.

Lymph Nodes

No clinically significant lymphadenopathy or abnormalities noted.

ULTRASONOGRAPHIC FINDINGS

- Gallbladder mucocele.
- Hepatomegaly with coarse echotexture and multifocal poorly defined nodules.
- Bilaterally prominent adrenal glands.
- Nephrocalcinosis
- Hyperechoic stippling in the spleen.

INTERPRETATION OF THE FINDINGS & FURTHER RECOMMENDATIONS

Gall bladder debris is most consistent with a developing mucocele. It does not appear to be causing an active problem but can contribute to elevated liver values.

Surgical removal could be considered to prevent gall bladder rupture and subsequent bile peritonitis. Cholecystectomy surgery is not without risk, and an alternative reasonable strategy is medical management and monitoring.

Liver changes are a common benign age-related change, but infiltrative disease (lymphoma, MCT, other) cannot be definitively ruled out. No significant disruption of architecture noted to suggest significant pathology. In the face of elevated liver enzymes, fine needle aspirate is recommended to further characterize parenchymal changes, and bile acid profile to assess liver function, especially if any weight loss is noted or for baseline cytological assessment. Ultimately liver biopsy is often required for more definitive diagnosis. Empiric treatments (SAM-E, milk thistle, Vitamin E, ursodiol if bilirubin elevated or gallbladder sludge) could be tried and liver enzymes re-evaluated, especially if liver FNA does not show significant pathology before more invasive liver sampling is pursued.

Adrenomegaly is bilateral and may represent stressful illness or hormonal stimulation as is seen with pituitary dependent hyperadrenocorticism. If corresponding clinical signs are present, a urine cortisol creatinine ratio could be used as a screening test, and subsequent testing for hyperadrenocorticism should be considered (ACTH stimulation test vs LDDST).

Splenic parenchymal changes are most consistent with dystrophic mineralization which is commonly seen with hyperadrenocorticism or other causes of mineral imbalance. Splenic aspirate could be considered if clinically warranted.



PATIENT

Amy Winehouse
 Ferrara

SPECIES

Canine

BREED

Maltese

SEX

Spayed Female

AGE

15 Years

WEIGHT

15.8 pounds

INTERPRETED BY

Dr Brittany Sinclair,
 BVSc(hons), DACVECC

IMAGING PERFORMED BY

Kelly Reschny

HOSPITAL NAME

Dog and Cat Clinic of
 Nlagra

REFERRING VET

Dr. Snieder

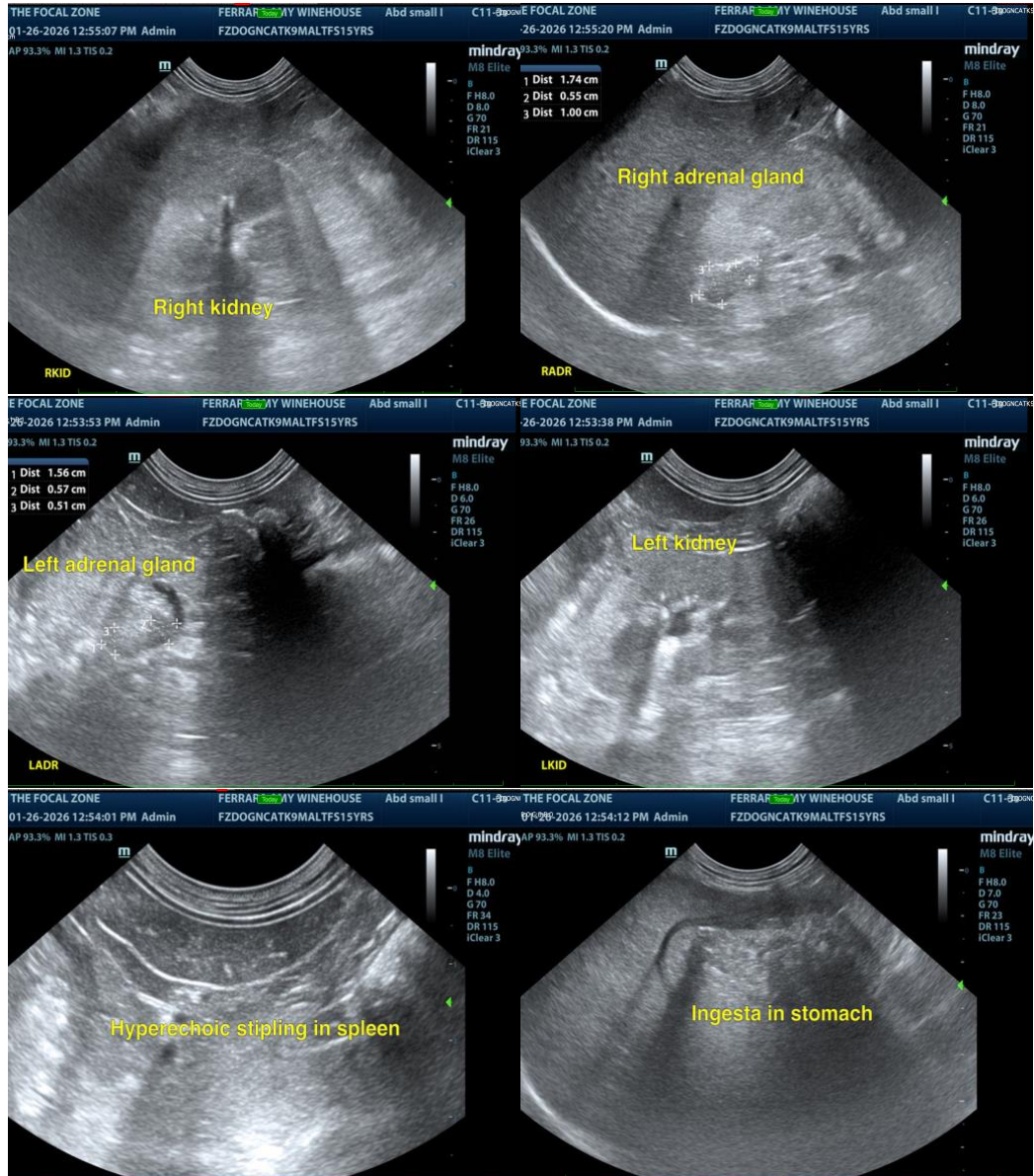
INVOICE

13403

DATE

01/26/26

Renal changes are likely age-related degenerative changes. Correlate clinical significance with blood work/urinalysis findings and clinical signs. Nephroliths may act as a nidus of infection and predispose to urinary tract infections. They can also cause sterile inflammation leading to renal hematuria. They have the potential to move into the ureters or bladder causing obstructive uropathy.





PATIENT

Amy Winehouse
 Ferrara

SPECIES

Canine

BREED

Maltese

SEX

Spayed Female

AGE

15 Years

WEIGHT

15.8 pounds

INTERPRETED BY

Dr Brittany Sinclair,
 BVSc(hons), DACVECC

IMAGING PERFORMED BY

Kelly Reschny

HOSPITAL NAME

Dog and Cat Clinic of
 Niagara

REFERRING VET

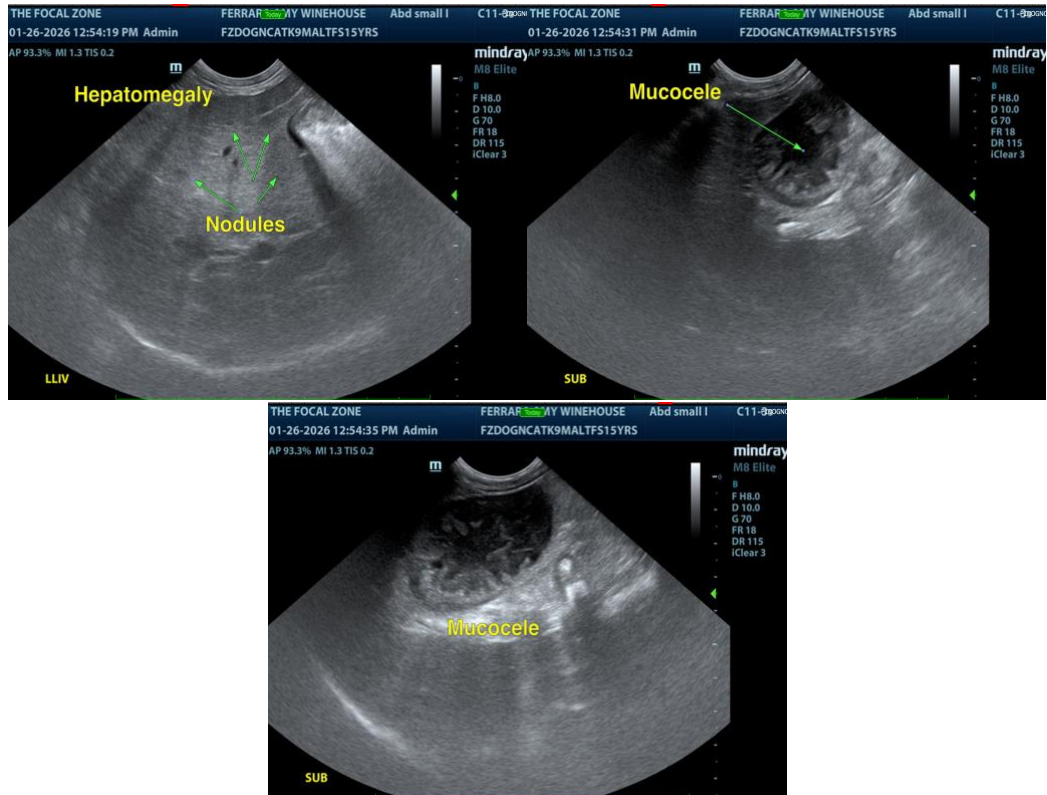
Dr. Snieder

INVOICE

13403

DATE

01/26/26



The information and recommendations provided are based on the images presented by the referring veterinarian/sonographer. No evaluation can be communicated regarding pathology that was not visible in the image/video clips provided.

Thank you for this referral. If the clinical or image interpretation does not parallel your findings or if I can be of any further assistance, please contact me.

Dr Brittany Sinclair, BVSc(hons), DACVECC

info@SonoPath.com