



PATIENT

Kenya Gillard

SPECIES

Canine

BREED

Bernadoodle

SEX

Neutered Male

AGE

10 Years

WEIGHT

34.5 kg

INTERPRETED BY

Dr Brittany Sinclair,
 BVSc(hons),
 DACVECC

IMAGING PERFORMED BY

Kelly Reschny

HOSPITAL NAME

Headon Forest Animal
 Hospital

REFERRING VET

Dr. Short

INVOICE

72334

DATE

1/21/26

PRESENTING CLINICAL SIGNS

- No changes/abnormal history, physical exam WNL.
- Current Medications - Zenronil 400mg 1.5 tabs sid

Abnormal PE/Chem/CBC/UA Results: Elevated ALT (148, RR 18-121) and ALP (339, RR 5-160) noted in Aug 2025. Values were rechecked Oct 10, 2025. ALT was WNL, ALP increased (450, RR5-160). P was started on Zentonil Oct 14 2025. Values were rechecked (fasted blood sample) Nov 21 2025. ALT still WNL. ALP increased (555, RR 5-160).

ULTRASONOGRAPHIC EXAMINATION OF THE ABDOMEN

Urinary System

The urinary bladder, trigone, and visible pelvic urethra were of normal thickness. The ureters were not visible which is normal. There was normal wall layering with no masses, uroliths or abnormal thickening visualized. Urine was anechoic. No evidence of inflammatory or neoplastic changes were noted.

The prostate is not visible.

The kidneys were both normal size and structure, with smooth capsule and normal corticomedullary definition and ratio. Medullary structure differed distinctly from that of the cortex. No evidence of pelvic dilation was present. Resolution of both kidneys is limited. Left kidney measures 6.16 cm. Right kidney measures 7.54 cm.

Adrenal Glands

The left adrenal gland is visualized and recognized as having normal shape, size, position and echogenicity for this breed and age. The visible phrenic vasculature was unremarkable. Left measures 3.19 cm in length x 0.75 cm at the caudal pole and 0.63 cm at the cranial pole.

The right adrenal gland is visualized and measured on still images only. Resolution is inadequate to assess glandular detail or confirm measurement. Right measures 2.73 cm in length.

Spleen

The spleen was normal with age appropriate homogeneous parenchyma and a smooth capsule with normal splenic vasculature with no signs of congestion or thrombosis. No sonographic evidence of acute or chronic inflammatory, neoplastic, or infarct changes were noted.

Liver

The liver is subjectively normal in size with normal contours and structure. There is age appropriate echogenicity and echotexture. No overt structural evidence of inflammatory, infiltrative or regenerative pathology is evident. Vascular and biliary tracts are of normal volume with no evidence of congestion.

Gall bladder is moderately distended with normal wall thickness and anechoic contents. Common bile duct is non-distended and tapers normally.



PATIENT

Kenya Gillard

SPECIES

Canine

BREED

Bernadoodle

SEX

Neutered Male

AGE

10 Years

WEIGHT

34.5 kg

INTERPRETED BY

Dr Brittany Sinclair,
 BVSc(hons),
 DACVECC

IMAGING PERFORMED BY

Kelly Reschny

HOSPITAL NAME

Headon Forest Animal
 Hospital

REFERRING VET

Dr. Short

INVOICE

72334

DATE

1/21/26

Gastrointestinal

The stomach contains minimal luminal contents. It measures at a normal thickness of with some variability due to the presence of rugal folds. The distinction of the gastric wall layers is adequate. No masses or focal lesions were observed.

The visualized areas of duodenum, jejunum and ileum have a relatively uniform diameter with minimal fluid distension. Wall thickness is normal. Bowel loops follow a curvilinear path with distinct wall layering maintaining the typical 1:3 muscularis:mucosa layer ratio. There were no focal lesions consistent with obstruction or a mass effect observed.

Sections of colon are visualized with formed fecal material and gas shadowing distally. There is no observed focal or generalized colon wall thickening or loss of layering.

Pancreas

The pancreas is not distinctly visualized.

Free Abdomen

No clinically significant lymphadenopathy or abnormalities noted. No free fluid noted.

ULTRASONOGRAPHIC FINDINGS

- Normal abdomen.

INTERPRETATION OF THE FINDINGS & FURTHER RECOMMENDATIONS

The liver and gallbladder appear normal in this patient. There is no obvious cause for the elevated ALP.

Induction phenomena are the most common cause for an elevation in ALP. These are systemic illnesses that 'turn on' the liver enzyme. Causes of this include Cushing's disease, dental disease, arthritis, and numerous others. In many cases the exact cause is unclear but as long as ultrasound and bile acids tests are normal most patients do not have progressive changes in their liver. While liver biopsy is not routinely performed, vacuolar hepatopathy is noted on most biopsies. This is often non-progressive but in rare cases can be more severe and lead to liver failure.

- If signs of cushings disease are present, recommend endocrine function testing to evaluate for cushing's disease.
- Consider fine needle aspirate to rule out round cell neoplasia.
- If a cause for the ALP elevation is not identified: I recommend recheck general blood work every 6 months, ultrasound once per year, and bile acids test every 1-2 years based on other results. If the ALP continues to climb a biopsy should be considered.
- Consider long term use of denamarin, and monitoring for the signs of cushings developing.



PATIENT

Kenya Gillard

SPECIES

Canine

BREED

Bernadoodle

SEX

Neutered Male

AGE

10 Years

WEIGHT

34.5 kg

INTERPRETED BY

Dr Brittany Sinclair,
 BVSc(hons),
 DACVECC

IMAGING PERFORMED BY

Kelly Reschny

HOSPITAL NAME

Headon Forest Animal
 Hospital

REFERRING VET

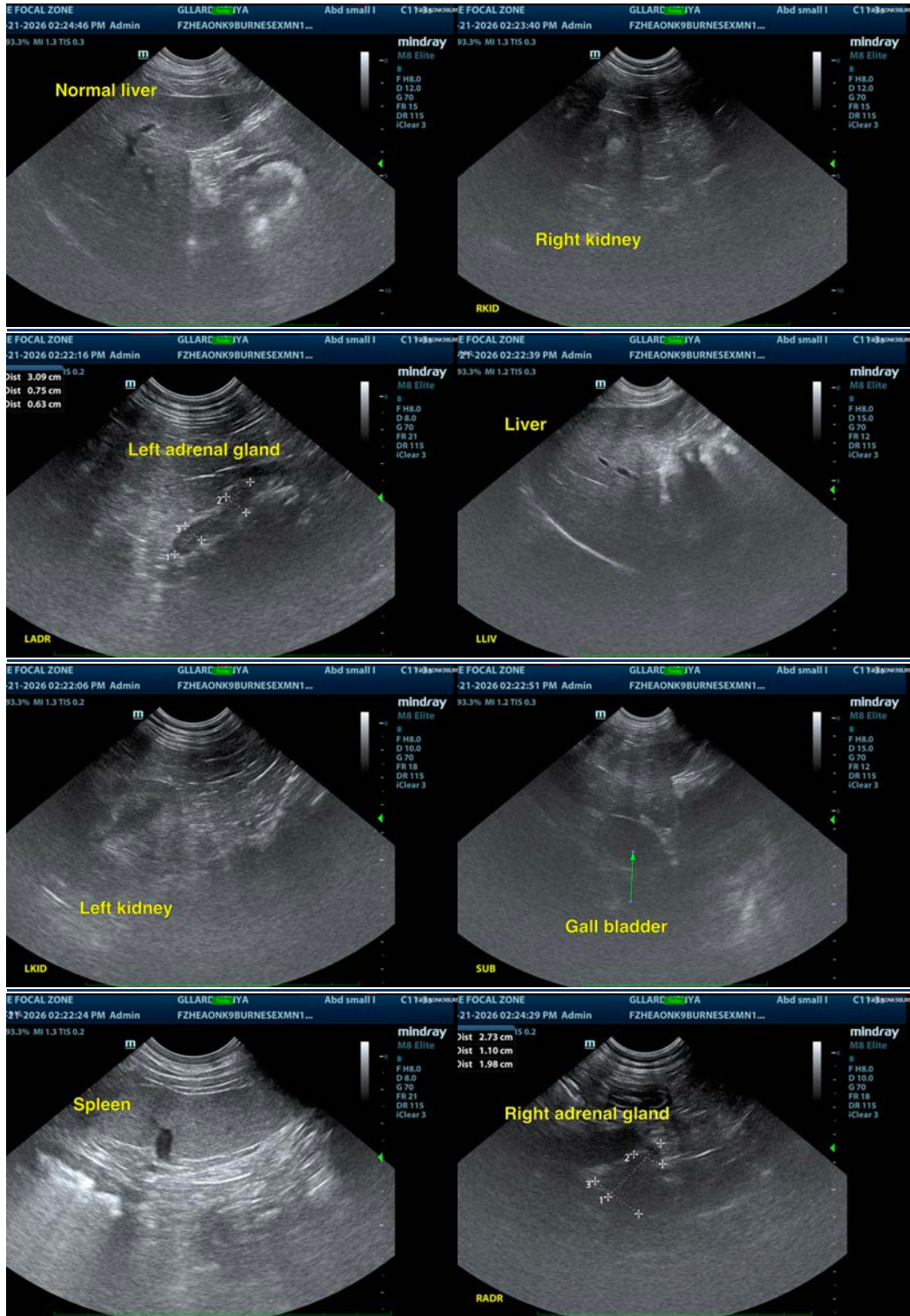
Dr. Short

INVOICE

72334

DATE

1/21/26





PATIENT

Kenya Gillard

SPECIES

Canine

BREED

Bernadoodle

SEX

Neutered Male

AGE

10 Years

WEIGHT

34.5 kg

INTERPRETED BY

Dr Brittany Sinclair,
BVSc(hons),
DACVECC

**IMAGING
PERFORMED BY**

Kelly Reschny

HOSPITAL NAME

Headon Forest Animal
Hospital

REFERRING VET

Dr. Short

INVOICE

72334

DATE

1/21/26

The information and recommendations provided are based on the images presented by the referring veterinarian/sonographer. No evaluation can be communicated regarding pathology that was not visible in the image/video clips provided.

Thank you for this referral. If the clinical or image interpretation does not parallel your findings or if I can be of any further assistance please contact me.

Dr Brittany Sinclair, BVSc(hons), DACVECC

info@SonoPath.com