



**PATIENT**

Max Kajic

**SPECIES**

Canine

**BREED**

Doberman

**SEX**

Neutered Male

**AGE**

7 Years

**WEIGHT**

85 pounds

**INTERPRETED BY**

Dr Brittany Sinclair,  
BVSc(hons), DACVECC

**IMAGING PERFORMED BY**

Kelly Reschny

**HOSPITAL NAME**

Hillview VC

**REFERRING VET**

Dr. E. Stevenson

**INVOICE**

13248

**DATE**

01/19/26

**PRESENTING CLINICAL SIGNS**

- what is going on in his GIT distal jejunum and duodenum.
- he is not absorbing.

Abnormal PE/Chem/CBC/UA Results: B12 is still low despite B12 injections.

**ULTRASONOGRAPHIC EXAMINATION OF THE ABDOMEN**

**Urinary System**

The urinary bladder, trigone, and visible pelvic urethra were of normal thickness. The ureters were not visible which is normal. There was normal wall layering with no masses, uroliths or abnormal thickening visualized. Urine was anechoic. No evidence of inflammatory or neoplastic changes were noted.

The kidneys were both normal size and structure, with smooth capsule and normal corticomedullary definition and ratio (cortex 1/3 of medulla). Medullary structure differed distinctly from that of the cortex. No evidence of pelvic dilation was present. The right kidney measured 7.44 cm in length. The left kidney measured 8.04 cm in length.

**Adrenal Glands**

The right adrenal gland was visualized and recognized as having normal shape, size, position and echogenicity for this breed. The phrenic vasculature, glandular echogenicity and detail were unremarkable. Capsule, cortex, and medullary definition were normal for this age patient. The right adrenal gland measured 2.7 cm in length and 1.95 cm at the cranial pole and 1.22 cm at the caudal pole.

The left adrenal gland was visualized and measured on still images only. Resolution is inadequate to assess glandular detail or confirm measurement. The left adrenal gland measured 2.29 cm in length and 0.53 cm at the cranial pole and 0.63 cm at the caudal pole.

**Spleen**

The spleen was normal with a smooth homogeneous parenchyma hyperechoic to liver and renal cortical parenchyma and smooth capsule, with normal splenic vasculature with no signs of congestion or thrombosis. No sonographic evidence of acute or chronic inflammatory, neoplastic, or infarct changes were noted.

**Liver**

The liver is subjectively normal in size with normal contours and structure. There is appropriate echogenicity and echotexture. No overt structural evidence of inflammatory, infiltrative or regenerative pathology is evident. Vascular and biliary tracts are of normal volume with no evidence of congestion. No pathological hepatic lymphadenopathy observed. Gallbladder is moderately distended with normal wall thickness and anechoic contents. Common bile duct is non-distended and tapers normally.

**Gastrointestinal**



**PATIENT**

Max Kajic

The stomach contains minimal luminal contents. It measures at a normal thickness with some variability due to the presence of rugal folds. The distinction of the gastric wall layers is adequate and there is no impression of reduced peristaltic activity. No masses or focal lesions were observed.

**SPECIES**

Canine

The visualized areas of duodenum, jejunum and ileum have a relatively uniform diameter with gas throughout with no overt distention. Wall thickness is normal. Bowel loops follow a curvilinear path with distinct wall layering maintaining the typical 1:3 muscularis: mucosa layer ratio. Visualized peristalsis appears appropriate. There were no focal lesions consistent with obstruction or a mass effect observed.

**BREED**

Doberman

The ileocecal junction was not visualized. Sections of colon are visualized with formed fecal material and gas shadowing distally. There is no observed focal or generalized colon wall thickening or loss of layering.

**SEX**

Neutered Male

***Pancreas***

The base and limbs of the pancreas were observed to be largely isoechoic to surrounding omental fat. Pancreatic duct and capsular contour and parenchyma were normal. No overt evidence of active inflammatory or neoplastic disease was noted.

**AGE**

7 Years

***Lymph Nodes***

No clinically significant lymphadenopathy or abnormalities noted.

**WEIGHT**

85 pounds

**ULTRASONOGRAPHIC FINDINGS**

- unremarkable abdomen.

**INTERPRETED BY**

Dr Brittany Sinclair,  
BVSc(hons), DACVECC

**INTERPRETATION OF THE FINDINGS & FURTHER RECOMMENDATIONS**

There is no ultrasonographically evident cause of reported GI signs in this abdominal study. Pancreas and GI tract are within normal limits. Consideration for dietary indiscretion, infectious etiologies (bacterial, viral, parasitic), food sensitivity/allergy or mild inflammatory bowel disease is reasonable. While not sonographically evident, pancreatitis cannot be completely ruled out. Empiric treatment for GI signs including anti-nausea, appetite stimulant and fluid support as clinically indicated is warranted. A diet trial with hydrolyzed protein or select protein diet could be considered if food sensitivity is suspected clinically. If signs are persistent or recurrent, additional diagnostics to be considered include baseline cortisol +/- ACTH stimulation test, GI panel (TLI/PLI/cobalamin/folate), fecal pathogen panel, thyroid testing, bile acid profile, and thoracic radiographs to rule out occult neoplasia, cardiac disease and esophageal disease as potential causes. Ultimately GI biopsy may be required for more definitive diagnosis if the patient is not responsive to medical treatment.

**IMAGING PERFORMED BY**

Kelly Reschny

Given the patient's reported lack of response to injectable B12, small intestinal biopsy should be strongly considered in this case.

**HOSPITAL NAME**

Hillview VC

**REFERRING VET**

Dr. E. Stevenson

**INVOICE**

13248

**DATE**

01/19/26



**PATIENT**

Max Kajic

**SPECIES**

Canine

**BREED**

Doberman

**SEX**

Neutered Male

**AGE**

7 Years

**WEIGHT**

85 pounds

**INTERPRETED BY**

Dr Brittany Sinclair,  
 BVSc(hons), DACVECC

**IMAGING PERFORMED BY**

Kelly Reschny

**HOSPITAL NAME**

Hillview VC

**REFERRING VET**

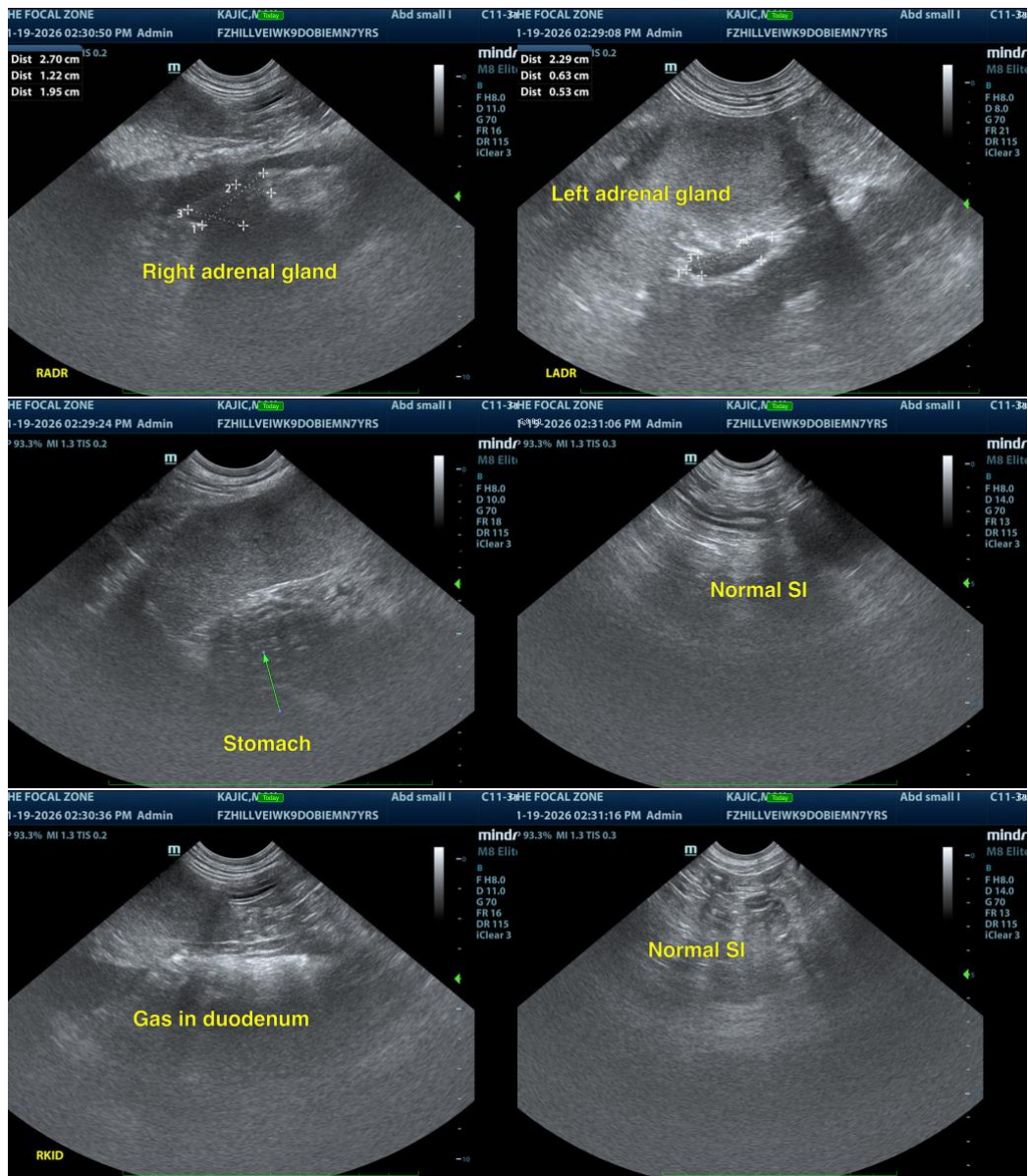
Dr. E. Stevenson

**INVOICE**

13248

**DATE**

01/19/26



The information and recommendations provided are based on the images presented by the referring veterinarian/sonographer. No evaluation can be communicated regarding pathology that was not visible in the image/video clips provided.

Thank you for this referral. If the clinical or image interpretation does not parallel your findings or if I can be of any further assistance, please contact me.

**Dr Brittany Sinclair, BVSc(hons), DACVECC**

info@SonoPath.com



**PATIENT**

Max Kajic

**SPECIES**

Canine

**BREED**

Doberman

**SEX**

Neutered Male

**AGE**

7 Years

**WEIGHT**

85 pounds

**INTERPRETED BY**

Dr Brittany Sinclair,  
BVSc(hons), DACVECC

**IMAGING  
PERFORMED BY**

Kelly Reschny

**HOSPITAL NAME**

Hillview VC

**REFERRING VET**

Dr. E. Stevenson

**INVOICE**

13248

**DATE**

01/19/26