



PATIENT	PRESENTING CLINICAL SIGNS
Luna Torres	Presented as a referral for an abdominal ultrasound to evaluate possible enlarged spleen and severe thrombocytopenia. Pt has a history of low activity and lethargy for 3-4 months. platelets. rDVM did BW and showed thrombocytopenia and radiographs showed enlarged spleen.
SPECIES	
Canine	Abnormal PE/Chem/CBC/UA Results: Bloodwork attached as supporting documents. Limited echocardiography: No pericardial effusion was seen or cardiac masses
BREED	ULTRASONOGRAPHIC EXAMINATION OF THE ABDOMEN
Miniature Schnauzer	Urinary System
SEX	The urinary bladder, trigone, and visible pelvic urethra were of normal thickness. The ureters were not visible which is normal. There was normal wall layering with no masses, uroliths or abnormal thickening visualized. Urine was anechoic. No evidence of inflammatory or neoplastic changes were noted.
Spayed Female	
AGE	The kidneys were both normal size and structure, with smooth capsule and normal corticomedullary definition and ratio. Medullary structure differed distinctly from that of the cortex. No evidence of pelvic dilation was present. Hyperechoic, shadowing foci present bilaterally in renal parenchyma and calyces consistent with nephrocalcinosis. Left kidney measures 4.37 cm. Right kidney measures 4.66 cm.
8 Years	
WEIGHT	Adrenal Glands
19.4 lbs	Both adrenal glands were visualized and recognized as having normal shape, size, position and echogenicity for this breed and age. The visible phrenic vasculature was unremarkable. Right measures 1.87 cm in length x 0.37 cm at the caudal pole and 0.39 cm at the caudal pole. Left measures 1.45 cm in length x 0.38 cm at the caudal pole and 0.39 cm at the cranial pole.
INTERPRETED BY	Spleen
Dr Brittany Sinclair, BVSc(hons), DACVECC	The head of the spleen contains a roughly spherical solid mass with small areas of cavitation measuring 4.19 cm x 4.83 cm. The remainder of the splenic parenchyma is slightly mottled.
IMAGING PERFORMED BY	Liver
Gabriel Ferrer, DVM	The liver is subjectively normal in size with normal contours and structure. The parenchyma is heterogenous with a coarse appearance. Multifocal variably sized diffuse, somewhat poorly defined hypoechoic nodules are noted throughout the liver. Vascular and biliary tracts are of normal volume with no evidence of congestion. No pathological hepatic lymphadenopathy observed.
HOSPITAL NAME	The gall bladder is moderately distended with anechoic fluid, with hyperechoic non-shadowing gravity dependent debris present. There is no surrounding free fluid or signs of active inflammation.
Pulse: Pet Ultrasound	Gastrointestinal
REFERRING VET	The stomach contains minimal luminal contents. It measures at a normal thickness of with some variability due to the presence of rugal folds. The distinction of the gastric wall layers is adequate. No masses or focal lesions were observed.
Dr. Nicole Andrea Gonzalez	The visualized areas of duodenum, jejunum and ileum have a relatively uniform diameter with minimal fluid distension. Wall thickness is normal. Bowel loops follow a curvilinear path with distinct wall
INVOICE	
72222	
DATE	
1/14/26	



PATIENT

Luna Torres

SPECIES

Canine

BREED

Miniature Schnauzer

SEX

Spayed Female

AGE

8 Years

WEIGHT

19.4 lbs

INTERPRETED BY

Dr Brittany Sinclair,
BVSc(hons),
DACVECC

IMAGING PERFORMED BY

Gabriel Ferrer, DVM

HOSPITAL NAME

Pulse: Pet Ultrasound

REFERRING VET

Dr. Nicole Andrea
Gonzalez

INVOICE

72222

DATE

1/14/26

layering maintaining the typical 1:3 muscularis:mucosa layer ratio. There were no focal lesions consistent with obstruction or a mass effect observed.

The ileocecal junction was visualized and exhibited normal intact wall layering and is subjectively of normal thickness. Sections of colon are visualized with formed fecal material and gas shadowing distally. There is no observed focal or generalized colon wall thickening or loss of layering.

Pancreas

The visible pancreas was observed to be largely isoechoic to surrounding omental fat.

Free Abdomen

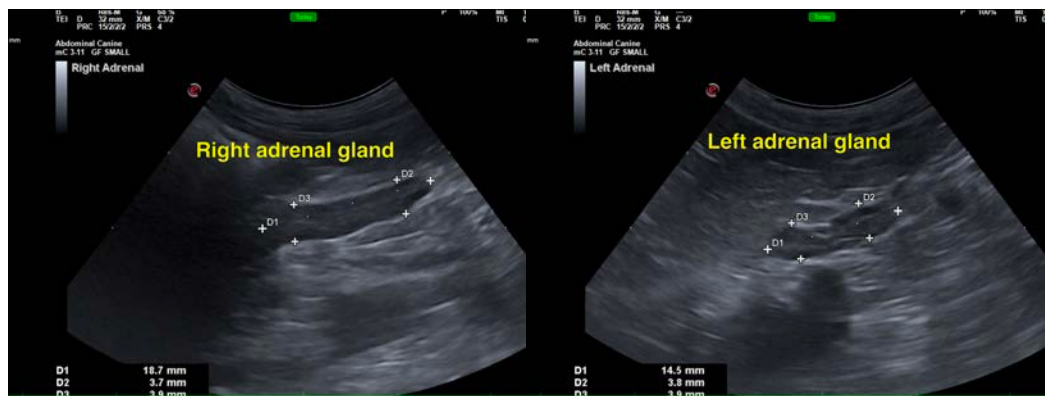
No clinically significant lymphadenopathy or abnormalities noted. No free fluid noted.

ULTRASONOGRAPHIC FINDINGS

- Partially cavitated splenic mass.
- Diffusely coarse liver with poorly defined nodules – suspect benign age related change.
- Mild nephrocalcinosis.
- Gallbladder debris (incidental).

INTERPRETATION OF THE FINDINGS & FURTHER RECOMMENDATIONS

The mass in the spleen is concerning for neoplasia, which may be malignant or benign. While there are nodules in the liver and they may represent metastatic neoplasia, they do not have the overt appearance of metastatic lesions, and benign aging change or other cause of hepatopathy is equally if not more likely. Unfortunately, given the patient’s severity of thrombocytopenia, splenectomy cannot likely be safely performed right now. I am suspicious of an immune mediated thrombocytopenia secondary to neoplasia, which can be difficult to control when the source (splenic mass) cannot be removed. Immunosuppression with steroid therapy and/or secondary immunosuppressives could be considered in an attempt to increase platelet count to allow for surgery, though immunosuppression does make surgery higher risk. Unfortunately, these cases can be difficult to manage. Consultation with a veterinary oncologist should be considered.





PATIENT

Luna Torres

SPECIES

Canine

BREED

Miniature Schnauzer

SEX

Spayed Female

AGE

8 Years

WEIGHT

19.4 lbs

INTERPRETED BY

Dr Brittany Sinclair,
BVSc(hons),
DACVECC

IMAGING PERFORMED BY

Gabriel Ferrer, DVM

HOSPITAL NAME

Pulse: Pet Ultrasound

REFERRING VET

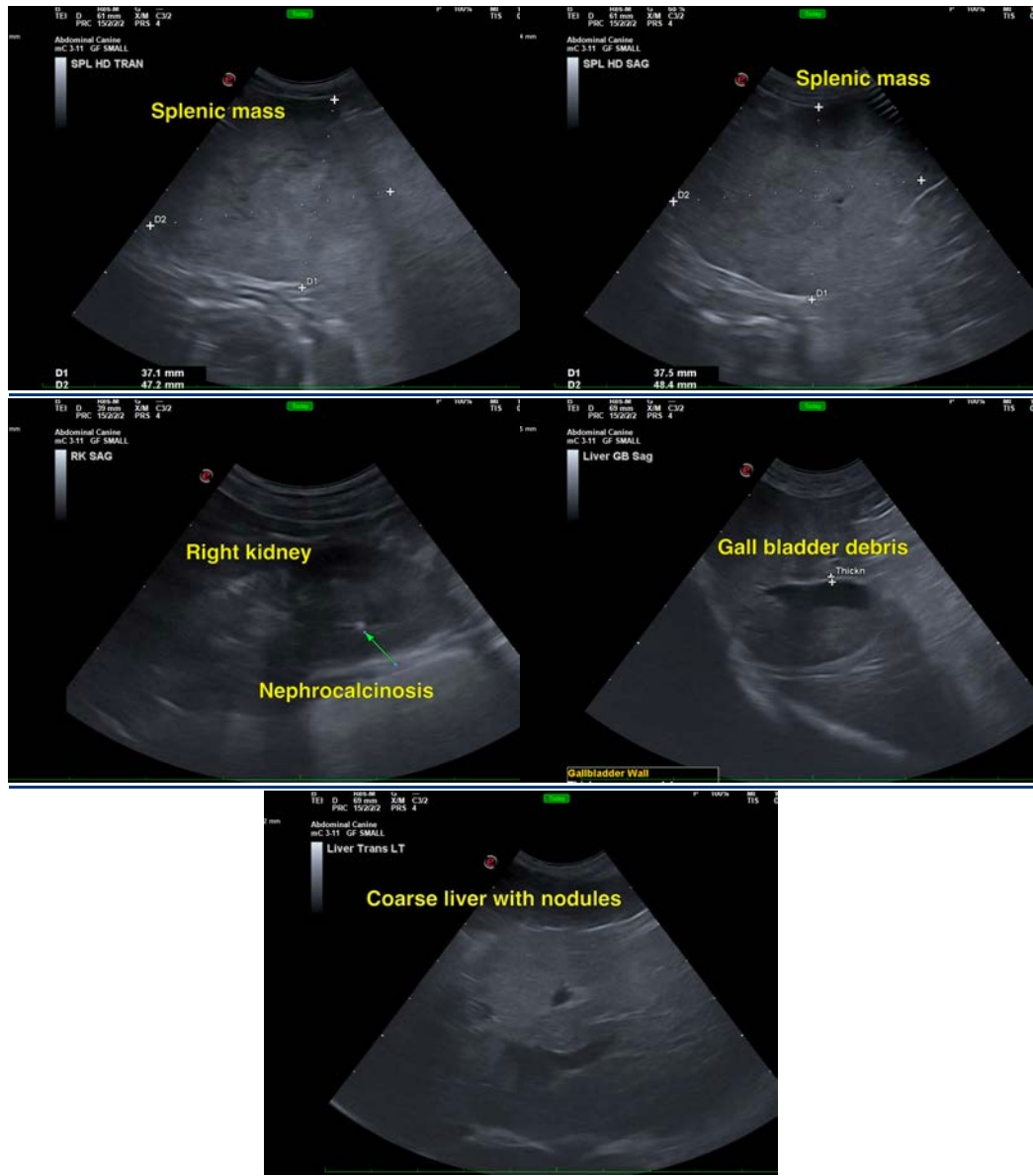
Dr. Nicole Andrea
Gonzalez

INVOICE

72222

DATE

1/14/26



The information and recommendations provided are based on the images presented by the referring veterinarian/sonographer. No evaluation can be communicated regarding pathology that was not visible in the image/video clips provided.

Thank you for this referral. If the clinical or image interpretation does not parallel your findings or if I can be of any further assistance please contact me.

Dr Brittany Sinclair, BVSc(hons), DACVECC

info@SonoPath.com