

**PATIENT**

Pippin Becht

**PRESENTING CLINICAL SIGNS**

History: Not eating, weight loss, vomiting. Current meds: Cerenia, Polyflex  
Abnormal PE/Chem/CBC/UA Results: WBC 30.2, Neu 25.52, Alb 1.7, TP 5.1

**SPECIES**

Feline

**ULTRASONOGRAPHIC EXAMINATION OF THE ABDOMEN**

**Urinary System**

Urinary bladder is adequately distended. It has a normal uniform wall thickness. Contents include primarily anechoic fluid with occasional echogenic non-shadowing debris, most consistent with incidental suspended lipid in a cat, possibly combined with exfoliated cells, mucous and/or small blood clots. Both sterile inflammation as well as urinary tract infection can also present with echogenic debris. No masses or cystoliths are observed. The trigone and visible pelvic urethra are normal in thickness with a smooth mucosal surface.

**BREED**

Domestic Shorthair

**SEX**

Spayed female

Left kidney is normal is size (3.42 cm), shape and echogenicity. It has smooth peripheral margination. There is a normal 1:3 cortex to medulla ratio with appropriate corticomedullary distinction. There is no evidence of pyelectasia, mineral or infarcts observed.

**AGE**

12 years

Right kidney is normal is size (3.96 cm), shape and echogenicity. It has smooth peripheral margination. There is a normal 1:3 cortex to medulla ratio with appropriate corticomedullary distinction. There is no evidence of pyelectasia, mineral or infarcts observed.

**WEIGHT**

5.9 lbs

**Adrenal Glands**

**INTERPRETED BY**

Beth Johnson, DVM  
DACVIM

Left adrenal gland is normal in size (0.25 cm thick), shape and overall architecture, echogenicity and echotexture. Visible surrounding vasculature appears normal.

Right adrenal gland is normal in size (0.33 cm thick), shape and overall architecture, echogenicity and echotexture. Visible surrounding vasculature appears normal.

**IMAGING PERFORMED BY**

Jessica Miller, RDMS

**Spleen**

Spleen is subjectively normal in size with a normal smooth capsular contour. Parenchyma is appropriately finely textured and homogenous with normal echogenicity relative to surrounding tissue (hyperechoic to liver). No focal nodules or masses are observed. Splenic vasculature appears normal.

**HOSPITAL NAME**

Basking Ridge AH

**Liver**

Liver is subjectively normal in size with normal smooth curvilinear peripheral contour. Parenchyma is appropriately hypoechoic to the spleen in echogenicity and appropriately mildly coarse and homogenous in echotexture. No focal lesions are observed. Visible vasculature and biliary tree appear normal without distension or congestion.

**REFERRING VET**

Dr. Hollo

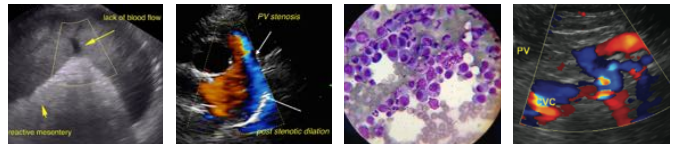
**INVOICE**

31762

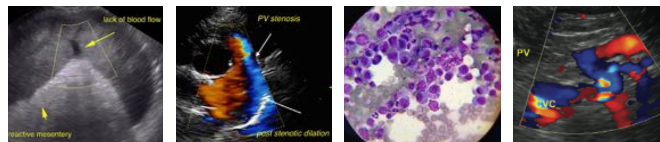
**DATE**

7/18/22

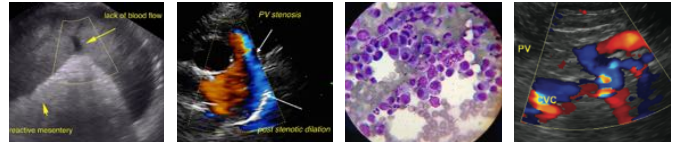
Gallbladder is moderately distended with anechoic bile as well as suspended and gravity dependent echogenic debris. Multiple, mineral densities with acoustic shadows are noted within the gallbladder. This is suggestive of cholecystoliths. The cystic and common bile duct are tortuous and mildly, but not pathologically dilated. The wall is smooth without visible thickening. There is no evidence of cystic or



<b>PATIENT</b>	CBD dilation. There is a scant amount of anechoic free fluid around the biliary system between the liver lobes.
Pippin Becht	
<b>SPECIES</b>	<b><i>Gastrointestinal</i></b>
Feline	The visible stomach wall is normal in thickness and layering. The lumen of the stomach is mildly distended with echogenic non-shadowing luminal contents and gas consistent with normal ingesta. There is no evidence of obstruction, foreign material or infiltrative disease. Pyloric outflow tract appears patent.
<b>BREED</b>	
Domestic Shorthair	The visible small intestine demonstrates areas of moderately to severely thick muscularis layer relative to mucosa (disruption of the normal 1:3 muscularis:mucosa ratio). Small intestinal submucosa is slightly irregular, thick and hyperechoic, without evident loss of layering appreciated. The lumen of the small intestine is mildly distended with echogenic non-shadowing luminal contents and gas consistent with normal ingesta. However, in the mid to caudal right abdomen there is a focal, bowel loop with an eccentric thickening that measured 0.86 cm thick with early hypoechoic loss of layering. This is consistent with an emerging bowel mass. At that level there is a linear, hyperechoic structure with an acoustic shadow that is concerning for a foreign object without evidence of an obstructive plication, etc.
<b>SEX</b>	
Spayed female	
<b>AGE</b>	
12 years	The visible colon is normal in wall thickness (< 0.2 cm) and layering. Contents are consistent with normal formed feces and gas.
<b>WEIGHT</b>	
5.9 lbs	
<b>INTERPRETED BY</b>	<b><i>Pancreas</i></b>
Beth Johnson, DVM DACVIM	The observed pancreas appears appropriately isoechoic to surrounding omental fat. Visible capsule is smooth and normal in contour. Visible pancreatic parenchyma is homogenous and unremarkable. There is no visible pancreatic duct dilation. There is no evidence of active peripancreatic inflammation.
<b>IMAGING PERFORMED BY</b>	<b><i>Free Abdomen</i></b>
Jessica Miller, RDMS	Lymph nodes are enlarged with swollen irregular capsular contour and loss of normal length to width ratio (rounded in shape). Nodes are hypoechoic with loss of normal parenchymal detail. There is a small amount of anechoic free fluid primarily noted in the cranial abdomen. Enhanced, hyperechoic fat and mesentery was noted surrounding the mesenteric lymph nodes and the above described bowel mass.
<b>HOSPITAL NAME</b>	
Basking Ridge AH	
<b>REFERRING VET</b>	<b>ULTRASONOGRAPHIC FINDINGS</b>
Dr. Hollo	<b>Primary Findings</b>
<b>INVOICE</b>	1. <b>Gastrointestinal lymphoma (suspect) pattern</b> – Thick muscularis has been reported with infiltrative bowel disease including both benign inflammatory disease as well as infiltrative neoplasia such as lymphoma. Given the concurrent pathology noted, infiltrative neoplasia is considered more likely, but benign IBD cannot be ruled out without tissue sampling.
31762	Mid to caudal abdominal emerging bowel mass noted. This is concerning for infiltrative neoplasia such as lymphoma.
<b>DATE</b>	
7/18/22	



<b>PATIENT</b>	There is foreign material noted within the lumen of the area of the bowel mass without evidence of an obstructive pattern, plication, etc. at this time. Foreign material is likely secondary to decreased bowel function in the area versus the primary contributing problem.
Pippin Becht	
<b>SPECIES</b>	2. <b>Aggressive mesenteric lymph nodes</b> – most consistent with infiltrative round cell or metastatic neoplasia. A benign aggressive inflammatory response cannot be ruled out without tissue sampling +/- culture.
Feline	Free fluid and enhanced fat and mesentery are all suggestive of focal inflammatory change/peritonitis likely secondary to infiltrative bowel disease.
<b>BREED</b>	3. <b>Gallbladder debris</b> and mineral with a mildly dilated tortuous cystic and common bile duct. Rule outs include normal patient variant with incidental debris versus concurrent cholangitis. This finding should be interpreted in combination with other findings such as cranial abdominal pain and/or liver enzyme changes to support an active process.
Domestic Shorthair	
<b>SEX</b>	
Spayed female	
<b>AGE</b>	<b>Secondary Findings</b>
12 years	1. <b>Urinary bladder debris.</b>
<b>WEIGHT</b>	<b><u>INTERPRETATION OF THE FINDINGS &amp; FURTHER RECOMMENDATIONS</u></b>
5.9 lbs	A gastrointestinal malabsorption panel (including cobalamin, folate, TLI and PLI) to Texas A&M GI Laboratory is recommended for further evaluation of GI and pancreatic function.
<b>INTERPRETED BY</b>	If a conservative approach is elected a FNA of the enlarged lymph nodes +/- the bowel mass could be considered if the patient's coagulation status is appropriate, to look for and rule in or out infiltrative round cell neoplasia. However, if a diagnosis cannot be obtained cytologically ideally biopsies of the GI tract to ensure to include the diffuse changes as well as remove the bowel mass followed by resection and anastomosis are recommended to definitively diagnose and therefore manage the infiltrative bowel disease.
Beth Johnson, DVM DACVIM	
<b>IMAGING PERFORMED BY</b>	If surgery is elected further evaluation of the gallbladder/biliary system is recommended at the same time. In the meantime, especially if further diagnostics cannot be pursued empirical therapies can include empirical deworming with a 5 day course of Panacur, cobalamin supplementation unless cobalamin level is evaluated and supplementation is not warranted +/- Prednisolone if not contraindicated based on the patient's contraindication, comorbidities, etc. Other supportive therapies could also include broad spectrum antibiotics and hepatic nutraceuticals especially if chemistry panel changes support a concurrent cholangitis/cholangiohepatitis.
Jessica Miller, RDMS	
<b>HOSPITAL NAME</b>	Depending on the course of action elected, especially if surgery is not pursued immediate, if gastrointestinal signs continue then close monitoring of the foreign material is recommended to rule out the development of an obstruction.
Basking Ridge AH	
<b>REFERRING VET</b>	
Dr. Hollo	
<b>INVOICE</b>	
31762	
<b>DATE</b>	
7/18/22	



**PATIENT**

Pippin Becht

**SPECIES**

Feline

**BREED**

Domestic Shorthair

**SEX**

Spayed female

**AGE**

12 years

**WEIGHT**

5.9 lbs

**INTERPRETED BY**

Beth Johnson, DVM  
DACVIM

**IMAGING PERFORMED BY**

Jessica Miller, RDMS

**HOSPITAL NAME**

Basking Ridge AH

**REFERRING VET**

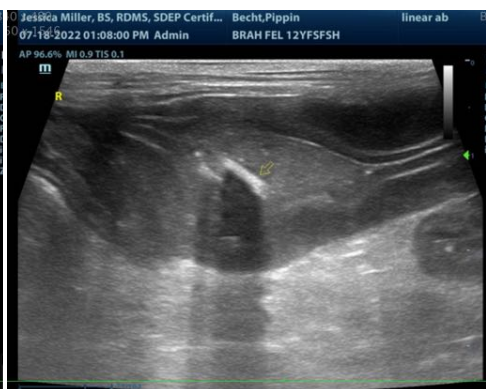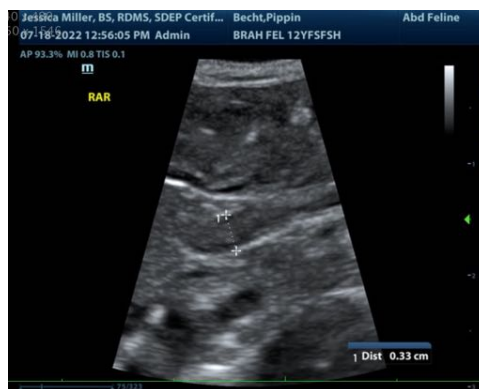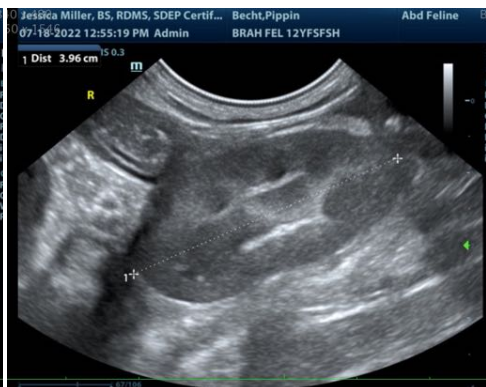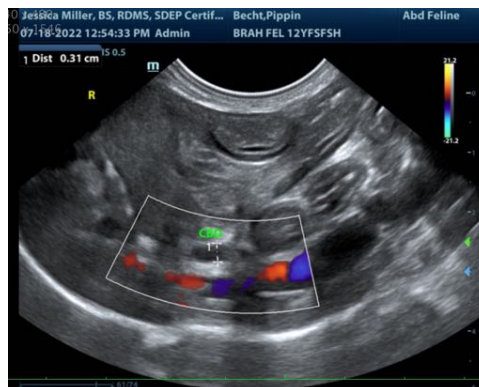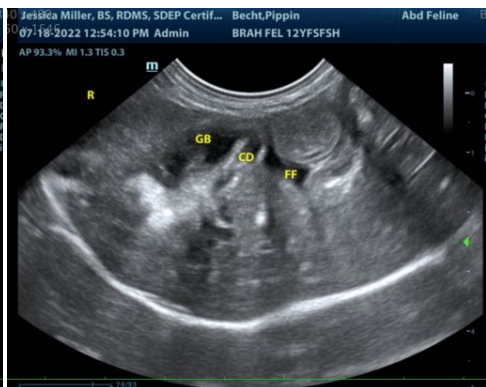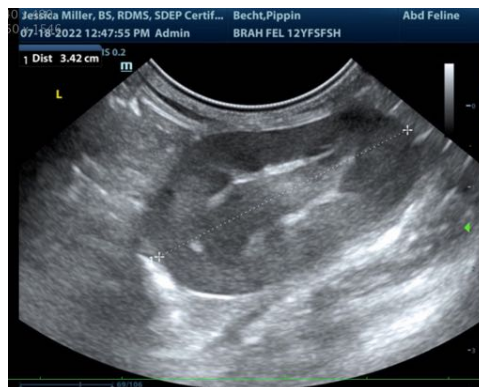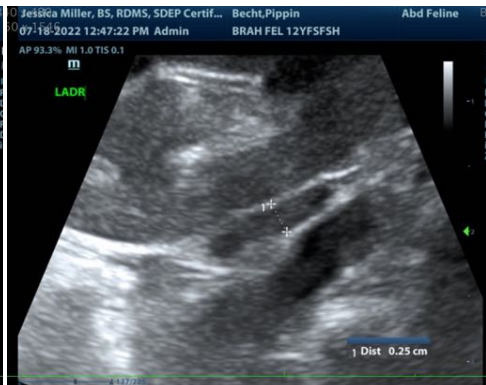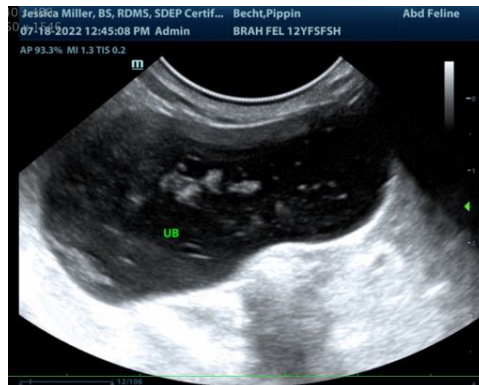
Dr. Hollo

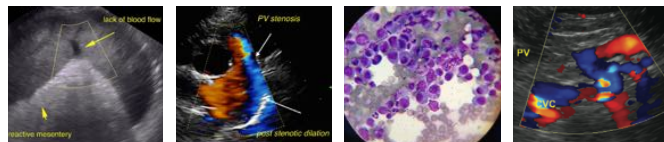
**INVOICE**

31762

**DATE**

7/18/22





**PATIENT**

Pippin Becht

**SPECIES**

Feline

**BREED**

Domestic Shorthair

**SEX**

Spayed female

**AGE**

12 years

**WEIGHT**

5.9 lbs

**INTERPRETED BY**

Beth Johnson, DVM  
DACVIM

**IMAGING PERFORMED BY**

Jessica Miller, RDMS

**HOSPITAL NAME**

Basking Ridge AH

**REFERRING VET**

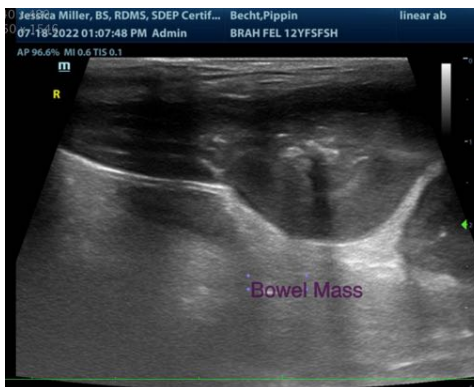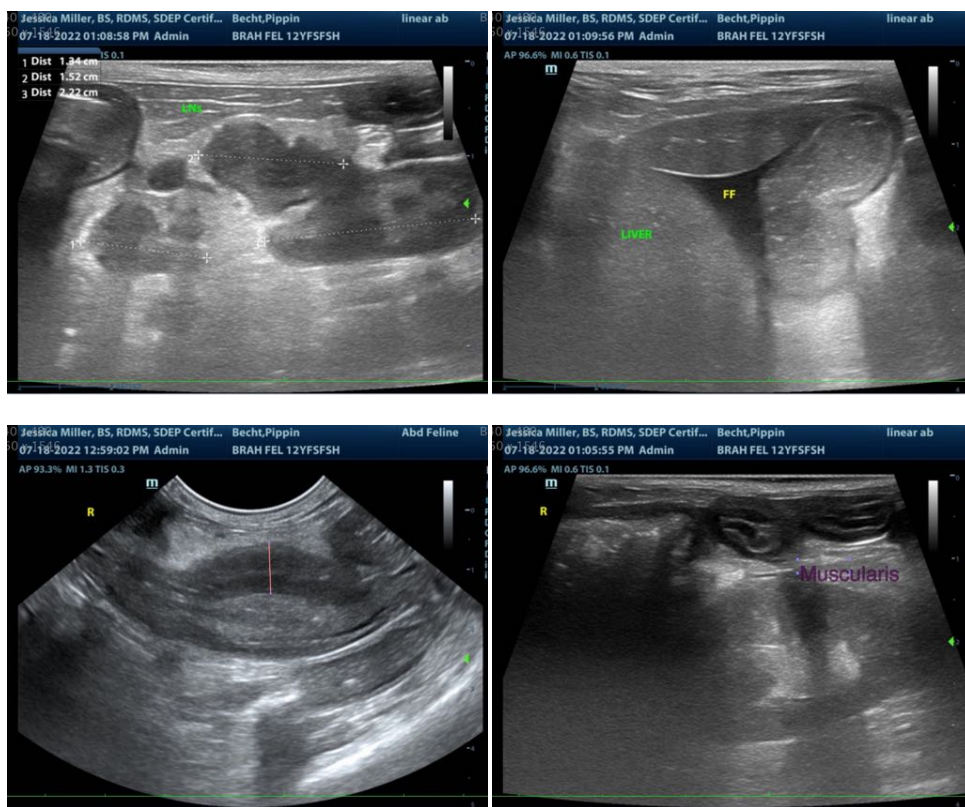
Dr. Hollo

**INVOICE**

31762

**DATE**

7/18/22



The information and recommendations provided are based on the images presented by the referring veterinarian/sonographer. No evaluation can be communicated regarding pathology that was not visible in the image/video clips provided.

Thank you for this referral. If the clinical or image interpretation does not parallel your findings or if it can be of any further assistance please contact me.

**Beth Johnson, DVM DACVIM**

Beth.Johnson@SonoPath.com