



PATIENT

Poppa Jr. Smith

SPECIES

Feline

BREED

Domestic Shorthair

SEX

Neutered male

AGE

14 years

WEIGHT

10.6 lbs

INTERPRETED BY

Beth Johnson, DVM
DACVIM

IMAGING PERFORMED BY

Shari Reffi, CVT

HOSPITAL NAME

VCA Blairstown AH

REFERRING VET

Dr. Clegg

INVOICE

30982

DATE

6/13/22

PRESENTING CLINICAL SIGNS

History: Possible abdominal mass and hepatic lipodosis. Current meds: Metronidazole, Cyproheptadine, Cerenia
Abnormal PE/Chem/CBC/UA Results: ALT 244, ALP 1,454, GGT 7, BILI 4.6, T4 10

ULTRASONOGRAPHIC EXAMINATION OF THE ABDOMEN

Urinary System

Urinary bladder is moderately distended with anechoic contents. It has normal uniform wall thickness (< 0.2 cm). No masses or cystoliths are observed.

Left kidney is normal in size and shape with smooth peripheral margination. A normal 1:3 cortex to medulla ratio is maintained. The medulla and cortices are uniform in texture with some mild increased echogenicity and mild loss of corticomedullary distinction. There is no evidence of pyelectasia, mineral or infarcts observed. The left kidney measured 4.52 cm.

Right kidney is normal in size and shape with smooth peripheral margination. A normal 1:3 cortex to medulla ratio is maintained. The medulla and cortices are uniform in texture with some mild increased echogenicity and mild loss of corticomedullary distinction. There is no evidence of pyelectasia, mineral or infarcts observed. The right kidney measured 5.53 cm.

Adrenal Glands

Left adrenal gland is normal in size (0.45 cm), shape and contour. Corticomedullary structure is unremarkable.

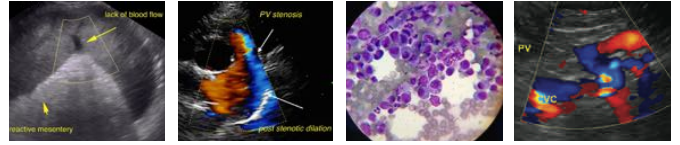
Right adrenal gland is normal in size (0.46 cm), shape and contour. Corticomedullary structure is unremarkable.

Spleen

Spleen is subjectively enlarged in size with rounded margins but intact capsule. Parenchyma is homogeneously coarse/mottled in echotexture and normal to hypoechoic in echogenicity. No focal nodules or masses are observed. Splenic vasculature appears normal.

Liver

Liver is subjectively normal in size. Margins are sharp and smooth. It has normal homogenous echotexture and normal echogenicity except for several focal masses of mixed echogenicity containing multiple cysts of varying size. The smaller cystic lesion is 0.8 cm on the left side of the liver. The larger cystic mass measured 0.3 cm on the right side of the liver. Gallbladder is mildly distended with anechoic contents. The wall is smooth without visible thickening. There is no evidence of common bile duct dilation.



PATIENT	<i>Gastrointestinal</i>
Poppa Jr. Smith	The visible gastric wall is normal in thickness (canine < 0.5 cm and feline < 0.4 cm). The stomach is empty.
SPECIES	The small intestines are normal in wall thickness and layering. Normal layering is maintained except for a diffusely disproportionately thick muscularis layer relative to mucosa. Small intestinal motility appears adequate (1-3 contractions per min). There are no luminal contents noted within small intestines.
Feline	
BREED	Colon is normal in wall thickness (< 0.2 cm) and layering.
Domestic Shorthair	
SEX	<i>Pancreas</i>
Neutered male	Pancreas has normal homogenous echotexture and is normal in echogenicity and smooth margination. There is no evidence of peripancreatic inflammation.
AGE	<i>Free Abdomen</i>
14 years	There is no appreciable free fluid including pericardial effusion. There is a large, irregular, hypoechoic 3.5 x 4.5 cm mass in the midabdomen that was surrounded by enhanced, hyperechoic fat. This is most consistent with mesenteric lymph node. However, a bowel mass cannot be ruled out, but is considered less likely.
WEIGHT	
10.6 lbs	
INTERPRETED BY	ULTRASONOGRAPHIC FINDINGS
Beth Johnson, DVM DACVIM	PRIMARY FINDINGS:
IMAGING PERFORMED BY	Midabdominal mass. Most consistent with an enlarged, mesenteric lymph node that is secondary to infiltrative neoplasia such as round cell neoplasia. Bowel mass cannot be ruled out and is considered less likely.
Shari Reffi, CVT	Coarse splenomegaly – can be associated with congestion caused by sedation (if sedated) but can also be associated with diffuse infiltrative disease. Both benign conditions such as extramedullary hematopoiesis, lymphoid hyperplasia, amyloidosis (leave amyloidosis out if canine) as well as infiltrative neoplastic diseases such as round cell neoplasia should be considered.
HOSPITAL NAME	Feline thick muscularis – This finding has been reported in cats with infiltrative bowel disease including both benign inflammatory disease as well as infiltrative neoplasia such as lymphoma.
VCA Blairstown AH	Cystic liver masses, which in a senior cat is most consistent with benign biliary cystadenomas. Malignancy cannot be ruled out, but is considered less likely.
REFERRING VET	
Dr. Clegg	
INVOICE	SECONDARY FINDINGS:
30982	Age related kidney change – This finding is expected/consistent with age-related mild degenerative disease and should be interpreted clinically in combination with laboratory changes.
DATE	
6/13/22	



PATIENT

Poppa Jr. Smith

SPECIES

Feline

BREED

Domestic Shorthair

SEX

Neutered male

AGE

14 years

WEIGHT

10.6 lbs

INTERPRETED BY

Beth Johnson, DVM
DACVIM

IMAGING PERFORMED BY

Shari Reffi, CVT

HOSPITAL NAME

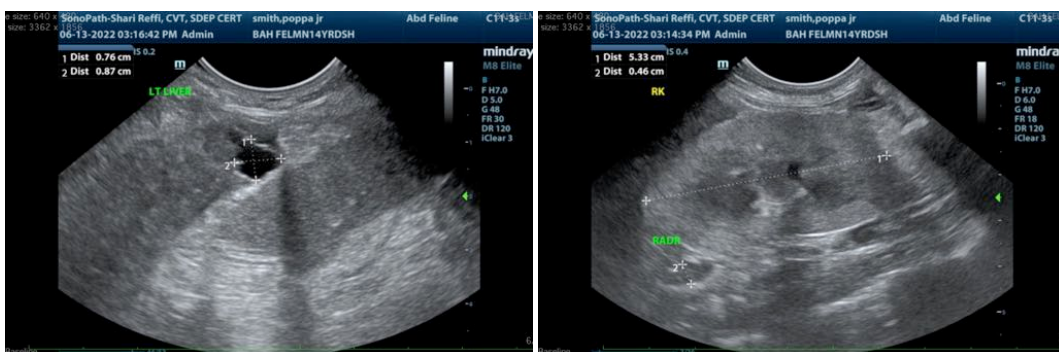
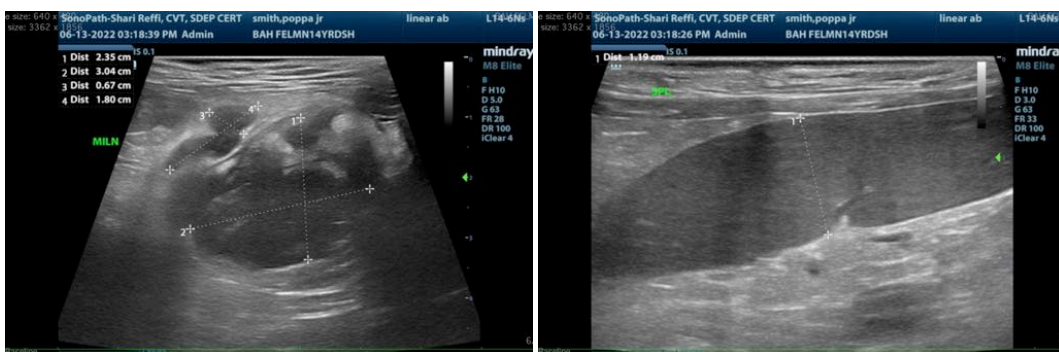
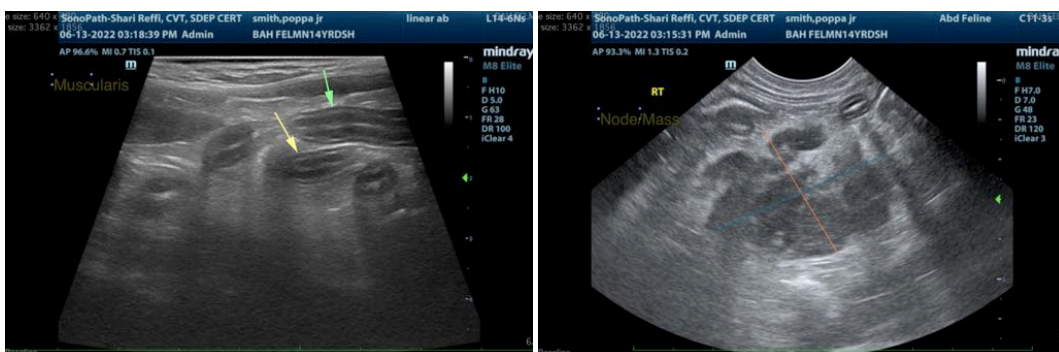
VCA Blairstown AH

REFERRING VET

Dr. Clegg

INTERPRETATION OF THE FINDINGS & FURTHER RECOMMENDATIONS

Recommendations for this patient include a FNA of the midabdominal mass/mesenteric lymph node if the patient's coagulation status is appropriate as well as potentially FNA of the spleen with Diphenhydramine as premedication in case this is mast cell disease versus lymphoma.



INVOICE

30982

DATE

6/13/22



PATIENT

Poppa Jr. Smith

SPECIES

Feline

BREED

Domestic Shorthair

SEX

Neutered male

AGE

14 years

WEIGHT

10.6 lbs

INTERPRETED BY

Beth Johnson, DVM
DACVIM

IMAGING PERFORMED BY

Shari Reffi, CVT

HOSPITAL NAME

VCA Blairstown AH

REFERRING VET

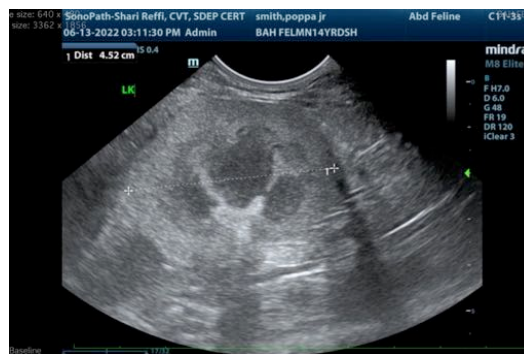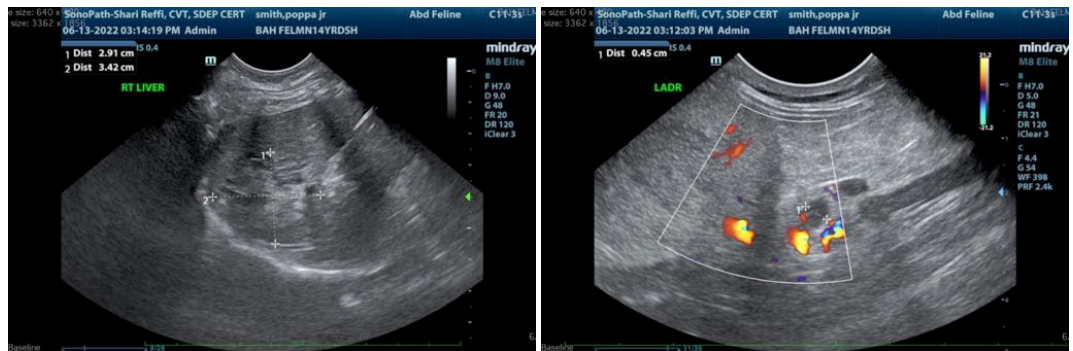
Dr. Clegg

INVOICE

30982

DATE

6/13/22



The information and recommendations provided are based on the images presented by the referring veterinarian/sonographer. No evaluation can be communicated regarding pathology that was not visible in the image/video clips provided.

Thank you for this referral. If the clinical or image interpretation does not parallel your findings or if I can be of any further assistance please contact me.

Beth Johnson, DVM DACVIM

Beth.Johnson@SonoPath.com