

PATIENT	PRESENTING CLINICAL SIGNS
Mikka Tassone	History: weight loss, fussy eater for past month Abnormal PE/Chem/CBC/UA Results: elevated BUN, Creat
SPECIES	ULTRASONOGRAPHIC EXAMINATION OF THE
Canine	<i>Urinary System</i>
BREED	Urinary bladder is adequately distended with primarily anechoic contents and occasional echogenic non-shadowing debris. Apical urinary bladder wall is diffusely thick (0.46 cm). Mucosa is hyperechoic and irregular. No masses or cystoliths are observed. The trigone and visible pelvic urethra are normal thickness with a smooth mucosal surface.
Whippet	
SEX	Kidneys are normal in size and contour. A relatively uniform hyperechogenicity is observed with mildly decreased corticomedullary distinction. There is no pyelectasia noted and no mineral is observed. No overt masses/nodules are observed. The left kidney measured 7.07 cm and the right kidney measured 6.54 cm.
Neutered male	
AGE	<i>Adrenal Glands</i>
7 years	Left adrenal gland is normal in size (2.0 cm long, 0.4 cm at cranial pole and 0.4 cm at caudal pole), shape and overall architecture, echogenicity and echotexture. Visible surrounding vasculature appears normal.
WEIGHT	Right adrenal gland is normal in size (2.0 cm long, 1.2 cm at cranial pole and 0.63 cm at caudal pole), shape and overall architecture, echogenicity and echotexture. Visible surrounding vasculature appears normal.
16 kg	
INTERPRETED BY	<i>Spleen</i>
Beth Johnson, DVM DACVIM	Spleen is subjectively normal in size with a normal smooth capsular contour. Parenchyma is appropriately finely textured and homogenous with normal echogenicity relative to surrounding tissue (hyperechoic to liver). No focal nodules or masses are observed. Splenic vasculature appears normal.
IMAGING PERFORMED BY	<i>Liver</i>
Kelly Reshny, RVT	Liver is subjectively normal in size with normal smooth curvilinear peripheral contour. Parenchyma is appropriately hypoechoic to the spleen in echogenicity and appropriately mildly coarse and homogenous in echotexture. No focal lesions are observed. Visible vasculature and biliary tree appear normal without distension or congestion.
HOSPITAL NAME	<i>Gastrointestinal</i>
Lynden AC	Gallbladder is non-distended in size. The wall is smooth without visible thickening. Luminal contents are primarily anechoic. There is no evidence of cystic or common bile duct dilation.
REFERRING VET	
Dr. Babcock	
INVOICE	
31502	
DATE	
7/7/22	



PATIENT	The visible small intestines are normal in wall thickness and layering. Small intestinal motility appears adequate (1-3 contractions per min). The lumen of the small intestine is empty with no evidence of obstruction, foreign material or infiltrative disease.
Mikka Tassone	
SPECIES	The visible colon is normal in wall thickness (< 0.2 cm) and layering. Contents are consistent with normal formed feces and gas.
Canine	
BREED	Pancreas
Whippet	The observed pancreas appears appropriately isoechoic to surrounding omental fat. Visible capsule is smooth and normal in contour. Visible pancreatic parenchyma is homogenous and unremarkable. There is no visible pancreatic duct dilation. There is no evidence of active peripancreatic inflammation.
SEX	Free Abdomen
Neutered male	There is no evidence of peritoneal effusion or apparent lymphadenopathy noted in these images.
AGE	
7 years	
WEIGHT	ULTRASONOGRAPHIC FINDINGS
16 kg	PRIMARY FINDINGS:
INTERPRETED BY	Nephritis – This appearance can be consistent with chronic interstitial nephritis or glomerulonephritis. Toxic insult and/or infectious disease (pyelonephritis, Leptospirosis, etc.) cannot be ruled out. This finding should be interpreted in combination with suspicion for renal disease and/or supporting laboratory or urinalysis changes.
Beth Johnson, DVM DACVIM	Chronic Cystitis - Urinary bladder wall changes are most consistent with chronic cystitis. Infiltrative neoplasia cannot be ruled out but is considered less likely give the location and diffuse nature of the changes.
IMAGING PERFORMED BY	INTERPRETATION OF THE FINDINGS & FURTHER RECOMMENDATIONS
Kelly Reshny, RVT	
HOSPITAL NAME	1. Urinalysis and, if indicated based on urinalysis results, urine culture are recommended. If protein is present in an otherwise quiet sediment, protein quantification with a urine protein to creatinine ration is recommended.
Lynden AC	2. Blood pressure is recommended if not recently evaluated.
REFERRING VET	3. Testing for Leptospirosis is indicated given the reported acute azotemia.
Dr. Babcock	4. A gastrointestinal malabsorption panel (including cobalamin, folate, TLI and PLI) to Texas A&M GI Laboratory is recommended for further evaluation of GI and pancreatic function. Baseline cortisol is also recommended. If the baseline cortisol is < 2.0 a full ACTH stimulation test is recommended to rule out less likely, but possible hypoadrenocorticism.
INVOICE	
31502	
DATE	
7/7/22	



PATIENT

Mikka Tassone

SPECIES

Canine

BREED

Whippet

SEX

Neutered male

AGE

7 years

WEIGHT

16 kg

INTERPRETED BY

Beth Johnson, DVM
DACVIM

**IMAGING
PERFORMED BY**

Kelly Reshny, RVT

HOSPITAL NAME

Lynden AC

REFERRING VET

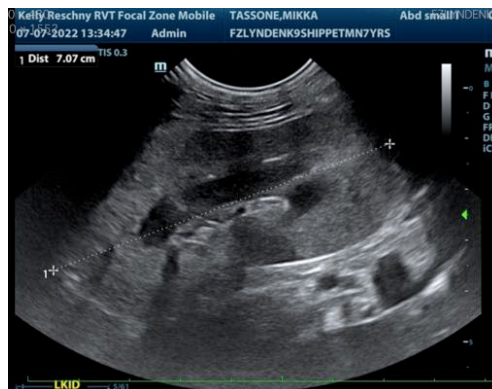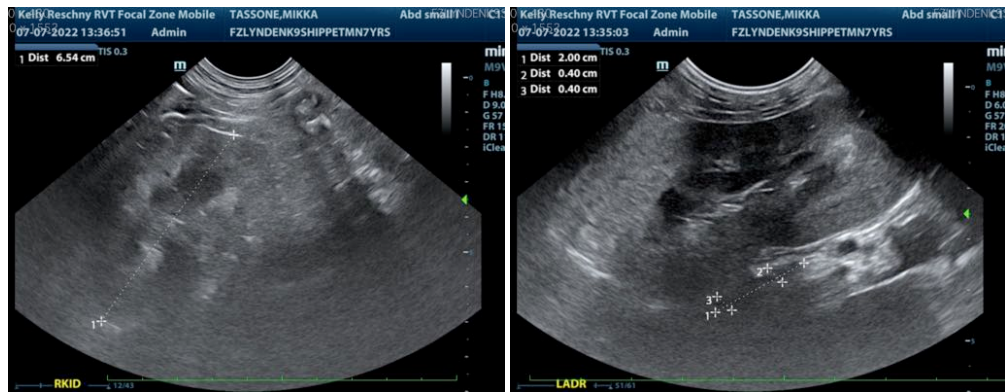
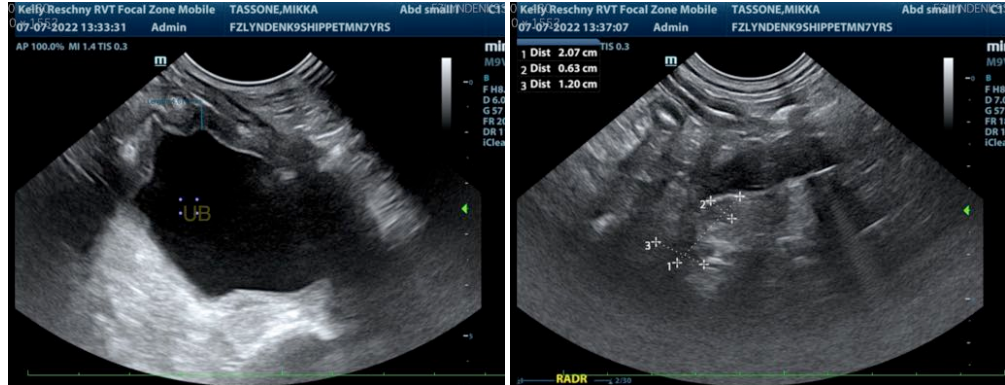
Dr. Babcock

INVOICE

31502

DATE

7/7/22



The information and recommendations provided are based on the images presented by the referring veterinarian/sonographer. No evaluation can be communicated regarding pathology that was not visible in the image/video clips provided.

Thank you for this referral. If the clinical or image interpretation does not parallel your findings or if I can be of any further assistance please contact me.

Beth Johnson, DVM DACVIM

Beth.Johnson@SonoPath.com