

PATIENT PRESENTING CLINICAL SIGNS

Milo Gima History: Clinically well, needs extensive dental work done. On preanesthetic bloodwork discovered low albumin and elevate post prandial bile acids. Concerned about proceeding until we see what is going on. Only current meds are k9 Advantix.

SPECIES Abnormal PE/Chem/CBC/UA Results: Mild anemia, elevated globulins, urine sp. grav 1.060.

Canine

ULTRASONOGRAPHIC EXAMINATION OF THE ABDOMEN

BREED Urinary System

Bichon Cross Urinary bladder is adequately distended with anechoic contents. No masses, inflammatory changes, echogenic sediment or cystoliths are observed. The urinary bladder, trigone and visible pelvic urethra are normal in thickness with a smooth mucosal surface.

SEX

Neutered male

Prostate (neutered) is normal in size, echotexture and echogenicity for a neutered male.

Left kidney is normal is size (4.08 cm), shape and echogenicity. It has smooth peripheral margination. There is a normal 1:3 cortex to medulla ratio with appropriate corticomedullary distinction. There is no evidence of pyelectasia, mineral or infarcts observed.

AGE

13 years

Right kidney is normal is size (3.64 cm), shape and echogenicity. It has smooth peripheral margination. There is a normal 1:3 cortex to medulla ratio with appropriate corticomedullary distinction. There is no evidence of pyelectasia, mineral or infarcts observed.

WEIGHT

13.6 lbs

Adrenal Glands

INTERPRETED BY

Beth Johnson, DVM
DACVIM

Left adrenal gland is normal in size (1.3 cm long, 0.44 cm at cranial pole and 0.36 cm at caudal pole), shape and overall architecture, echogenicity and echotexture. Visible surrounding vasculature appears normal.

IMAGING PERFORMED BY

Crystal Hill, RVT

Right adrenal gland is normal in size (1.38 cm long, 0.82 cm at cranial pole and 0.47 cm at caudal pole), shape and overall architecture, echogenicity and echotexture. Visible surrounding vasculature appears normal.

HOSPITAL NAME

Halton Peel AH

Spleen

Spleen is subjectively normal in size with a normal smooth capsular contour. Parenchyma is appropriately finely textured and homogenous with normal echogenicity relative to surrounding tissue (hyperechoic to liver). No focal nodules or masses are observed. Splenic vasculature appears normal.

REFERRING VET

Dr. Walters

Liver

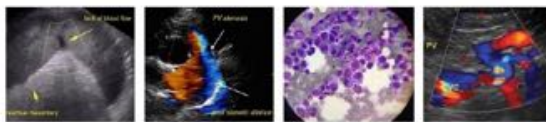
INVOICE

31761

Liver is subjectively normal in size with normal smooth curvilinear peripheral contour. Parenchyma is appropriately hypoechoic to the spleen in echogenicity and appropriately mildly coarse and homogenous in echotexture. No focal lesions are observed. Visible vasculature and biliary tree appear normal without distension or congestion.

DATE

7/18/22



PATIENT

Milo Gima

Gallbladder is moderately distended with anechoic bile as well as suspended and gravity dependent echogenic debris. The wall is smooth without visible thickening. There is no evidence of cystic or CBD dilation. There is no evidence of effusion or inflammation.

SPECIES

Canine

Gastrointestinal

The visible stomach wall is normal in thickness and layering. The lumen of the stomach is mildly fluid distended.

BREED

Bichon Cross

The visible small intestines are normal in wall thickness and layering. Small intestinal motility appears adequate (1-3 contractions per min). The lumen of the small intestine is empty with no evidence of obstruction, foreign material or infiltrative disease.

SEX

Neutered male

The visible colon is normal in wall thickness (< 0.2 cm) and layering. Contents are consistent with normal formed feces and gas.

AGE

13 years

Pancreas

The observed pancreas appears appropriately isoechoic to surrounding omental fat. Visible capsule is smooth and normal in contour. Visible pancreatic parenchyma is homogenous and unremarkable. There is no visible pancreatic duct dilation. There is no evidence of active peripancreatic inflammation.

WEIGHT

13.6 lbs

Free Abdomen

INTERPRETED BY

Beth Johnson, DVM
DACVIM

There is no evidence of peritoneal effusion or apparent lymphadenopathy noted in these images.

ULTRASONOGRAPHIC FINDINGS

IMAGING PERFORMED BY

Crystal Hill, RVT

Gallbladder debris - Cholecystic debris is of unknown clinical significance. It can be seen with biliary stasis from fasting or illness. Cholecystic debris is not necessarily related to hepatobiliary disease. Echogenic bile is most commonly an incidental finding in dogs and should be interpreted in combination with clinical signs such as nausea, inappetence, cranial abdominal discomfort and/or laboratory changes such as increased ALP and/or increased Tbili.

HOSPITAL NAME

Halton Peel AH

INTERPRETATION OF THE FINDINGS & FURTHER RECOMMENDATIONS

REFERRING VET

Dr. Walters

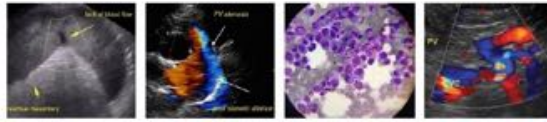
There is no obvious ultrasonographic explanation for this patient's laboratory changes and increased bile acids. Differentials for the high globulin and low albumin could include the reported extensive dental disease depending on the severity of the inflammation. Interpretation of the increased bile acids is dependent on the level of increase. If the increase is significant and decrease liver function is suspected further evaluation of the liver is recommended prior to anesthesia for the dental work. However, if the increase is mild there are no obvious contraindications in this study for proceeding with the reported necessary dental work. Testing for Leptospirosis is indicated if not recently evaluated.

INVOICE

31761

DATE

7/18/22



PATIENT

Milo Gima

SPECIES

Canine

BREED

Bichon Cross

SEX

Neutered male

AGE

13 years

WEIGHT

13.6 lbs

INTERPRETED BY

Beth Johnson, DVM
DACVIM

IMAGING PERFORMED BY

Crystal Hill, RVT

HOSPITAL NAME

Halton Peel AH

REFERRING VET

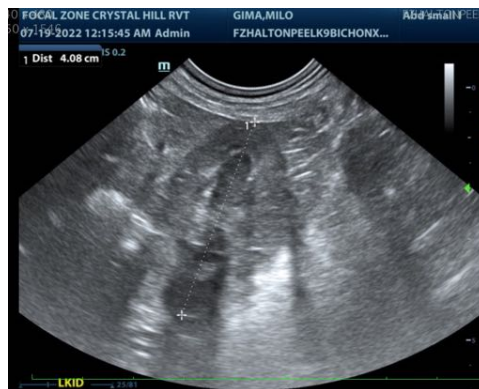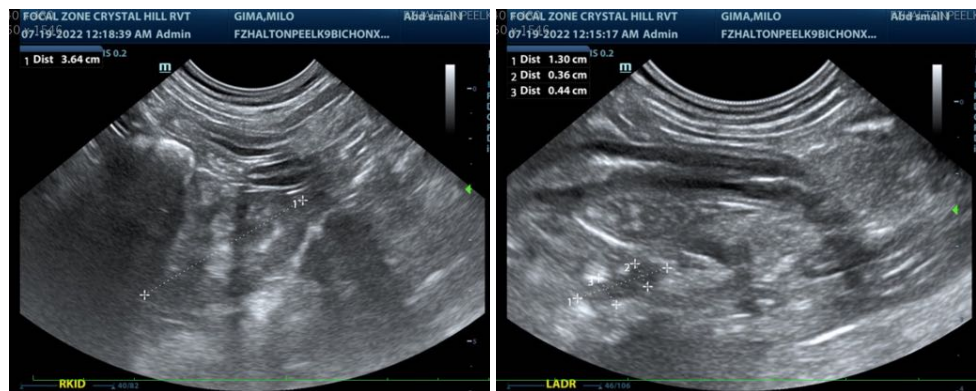
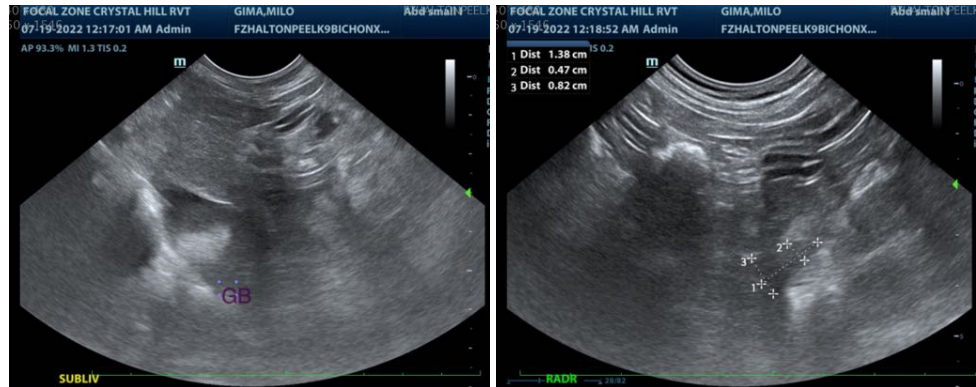
Dr. Walters

INVOICE

31761

DATE

7/18/22



The information and recommendations provided are based on the images presented by the referring veterinarian/sonographer. No evaluation can be communicated regarding pathology that was not visible in the image/video clips provided.

Thank you for this referral. If the clinical or image interpretation does not parallel your findings or if I can be of any further assistance please contact me.

Beth Johnson, DVM DACVIM

Beth.Johnson@SonoPath.com