



PATIENT

Marvin Palser

SPECIES

Canine

BREED

Mini Labradoodle

SEX

Neutered Male

AGE

3 Years

WEIGHT

37.6 Pounds

INTERPRETED BY

Beth Johnson, DVM
DACVIM

IMAGING PERFORMED BY

Dr. Susan Lincoski

HOSPITAL NAME

University Drive VH

REFERRING VET

Dr. Susan Lincoski

INVOICE

41134

DATE

9/8/22

PRESENTING CLINICAL SIGNS

t=101.0 Marvin is here for recheck following mulch ingestion. No vomiting, and had cerenia yesterday. Today he is more "punk", but not acting as painful yesterday and no "prayer posture". Belly is soft. He is, however, mildly dehydrated and MM's tacky. Thorax auscults WNL, and quiet gut sounds. Bloodwork reveals unremarkable, AMYL=395, T4=0.9, except mild neutrophilia (13.44K/ul). cPL=normal. Repeated radiographs, and sending yesterdays + todays for review stat. PL: 22 ga iv catheter placed, starting him on 2x maint p-lyte (90ml/hr) and repeat cerenia 2ml IV, pending review. Abnormal PE/Chem/CBC/UA Results: Bloodwork reveals unremarkable, AMYL=395, T4=0.9, except mild neutrophilia (13.44K/ul). cPL=normal. Radiographs 3-view from 9/7 and 9/8 are unable to rule in or out small intestinal mechanical obstruction.

ULTRASONOGRAPHIC EXAMINATION OF THE ABDOMEN

Urinary System

The urinary bladder is moderately distended with anechoic contents. No masses, inflammatory changes, echogenic sediment or cystoliths are observed. The urinary bladder, trigone and visible pelvic urethra are normal in thickness with a smooth mucosal surface.

The area of the prostate is examined without evident pathology.

The right kidney is normal in size (5.69 cm), shape and echogenicity. It has smooth peripheral margination. There is a normal 1:3 cortex to medulla ratio with appropriate corticomedullary distinction. There is no evidence of pyelectasia, mineral or infarcts observed.

The left kidney is normal in size (5.5 cm), shape and echogenicity. It has smooth peripheral margination. There is a normal 1:3 cortex to medulla ratio with appropriate corticomedullary distinction. There is no evidence of pyelectasia, mineral or infarcts observed.

Adrenal Glands

The right adrenal gland is normal in size (1.7 cm long x 0.57 cm thick), shape and contour. Corticomedullary structure is unremarkable. Visible surrounding vasculature appears normal.

The left adrenal gland is normal in size (1.2 cm long x 0.45 cm at the cranial pole and 0.46 cm at the caudal pole), shape and contour. Corticomedullary structure is unremarkable. Visible surrounding vasculature appears normal.

Spleen

The spleen is subjectively normal in size with a normal smooth capsular contour. Parenchyma is appropriately finely textured and homogenous with normal echogenicity relative to surrounding tissue (hyperechoic to liver). No focal nodules or masses are observed. Splenic vasculature appears normal.

Liver

The liver is subjectively normal in size with normal smooth curvilinear peripheral contour. Parenchyma is appropriately hypoechoic to the spleen in echogenicity and appropriately mildly coarse and homogenous in echotexture. No focal lesions are observed. Visible vasculature and biliary tree appear normal without distension or congestion.

The gallbladder is non-distended in size. The wall is smooth without visible thickening. Luminal contents are primarily anechoic. There is no evidence of cystic or common bile duct dilation.

Gastrointestinal



PATIENT

Marvin Palser

The visible stomach wall is normal in thickness and layering. The lumen of the stomach is mildly distended with very echogenic reverberation artifact from intraluminal gas, and fluid. There is no evidence of obstruction, foreign material or infiltrative disease; however, complete visualization of far wall is partially inhibited by gas. Pyloric outflow tract appears patent.

SPECIES

Canine

Most of the visible small intestines are normal in wall thickness and layering (canine duodenum < 0.5 cm and feline duodenum < 0.4 cm; other < 0.3 cm). Small intestinal motility appears adequate (1-3 contractions per min). The lumen of the small intestine is largely empty with no evidence of obstruction, foreign material or infiltrative disease. However, in the mid abdomen, there is a small bowel loop that is mildly fluid distended. Elsewhere in the abdomen, there is a bowel loop that is distended by echogenic material including a curvilinear echogenic interface with strong acoustic shadow. However, this second described bowel loop cannot be definitively determined to be small bowel with an obstructive foreign body versus large bowel with impacted feces and gas.

BREED

Mini Labradoodle

SEX

Neutered Male

The described dilated small bowel loop cannot be traced to the latter described possible foreign material/impaction to definitively determine a small bowel obstruction versus more normal large bowel contents. Regardless, in the area around the mildly fluid dilated bowel that contains the strong acoustic shadow, there is a scant amount of anechic free fluid and enhanced hyperechoic fat and mesentery, suggestive of a focal peritonitis.

AGE

3 Years

Pancreas

The pancreatic parenchyma is appropriately isoechoic to surrounding tissue. Visible capsule is smooth and normal in contour. There is no visible pancreatic duct dilation. There is no evidence of active peripancreatic inflammation.

WEIGHT

37.6 Pounds

Free Abdomen

INTERPRETED BY

Beth Johnson, DVM
DACVIM

There is no apparent lymphadenopathy noted in these images.

ULTRASONOGRAPHIC FINDINGS

IMAGING PERFORMED BY

Dr. Susan Lincoski

- Focal bowel loops containing an echogenic structure with strong acoustic shadow that could be normal colonic contents. However, an obstructive foreign body in small bowel can't be definitively ruled out. Regardless of small versus large bowel, there is visible evidence of a focal peritonitis surrounding the area. In a 2nd video there is a mildly dilated focal small bowel loop, but this focal dilation cannot be definitively traced to the area that could be a suspected small bowel foreign body. Therefore, differentials include gastroenteritis and peritonitis as a result of migrating mulch/debris that has reached the colon versus a potential, at least partial, if not possibly complete small bowel foreign body obstruction.

HOSPITAL NAME

University Drive VH

INTERPRETATION OF THE FINDINGS & FURTHER RECOMMENDATIONS

REFERRING VET

Dr. Susan Lincoski

Given the inflammation/suspicion for focal peritonitis, the more aggressive approach would be an exploratory laparotomy with planned foreign body removal if a foreign body is discovered +/- biopsies of any palpably or visibly abnormal bowel to prevent any ongoing inflammation/damage to the GI tract, versus a more conservative approach, which given this patient's lack of ongoing clinical signs and reportedly comfortable abdomen, etc., may be appropriate, and includes supportive care in the form of fluid therapy, antiemetics, gastroprotectants, and fasting with planned recheck imaging again in 24 hours.

INVOICE

41134

DATE

9/8/22



PATIENT

Marvin Palser

SPECIES

Canine

BREED

Mini Labradoodle

SEX

Neutered Male

AGE

3 Years

WEIGHT

37.6 Pounds

INTERPRETED BY

Beth Johnson, DVM
DACVIM

IMAGING PERFORMED BY

Dr. Susan Lincoski

HOSPITAL NAME

University Drive VH

REFERRING VET

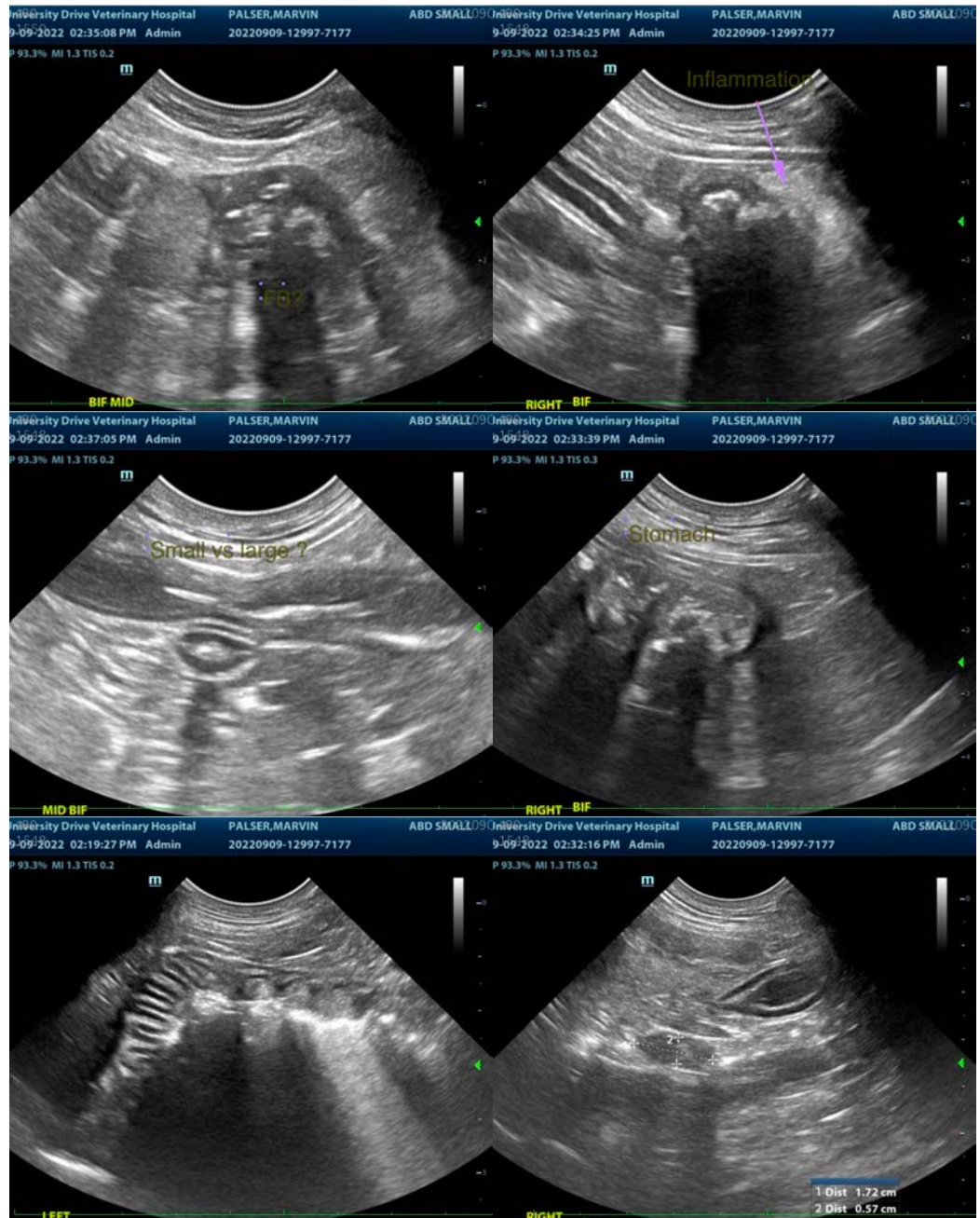Dr. Susan Lincoski

INVOICE

41134

DATE

9/8/22





PATIENT

Marvin Palser

SPECIES

Canine

BREED

Mini Labradoodle

SEX

Neutered Male

AGE

3 Years

WEIGHT

37.6 Pounds

INTERPRETED BY

Beth Johnson, DVM
DACVIM

IMAGING PERFORMED BY

Dr. Susan Lincoski

HOSPITAL NAME

University Drive VH

REFERRING VET

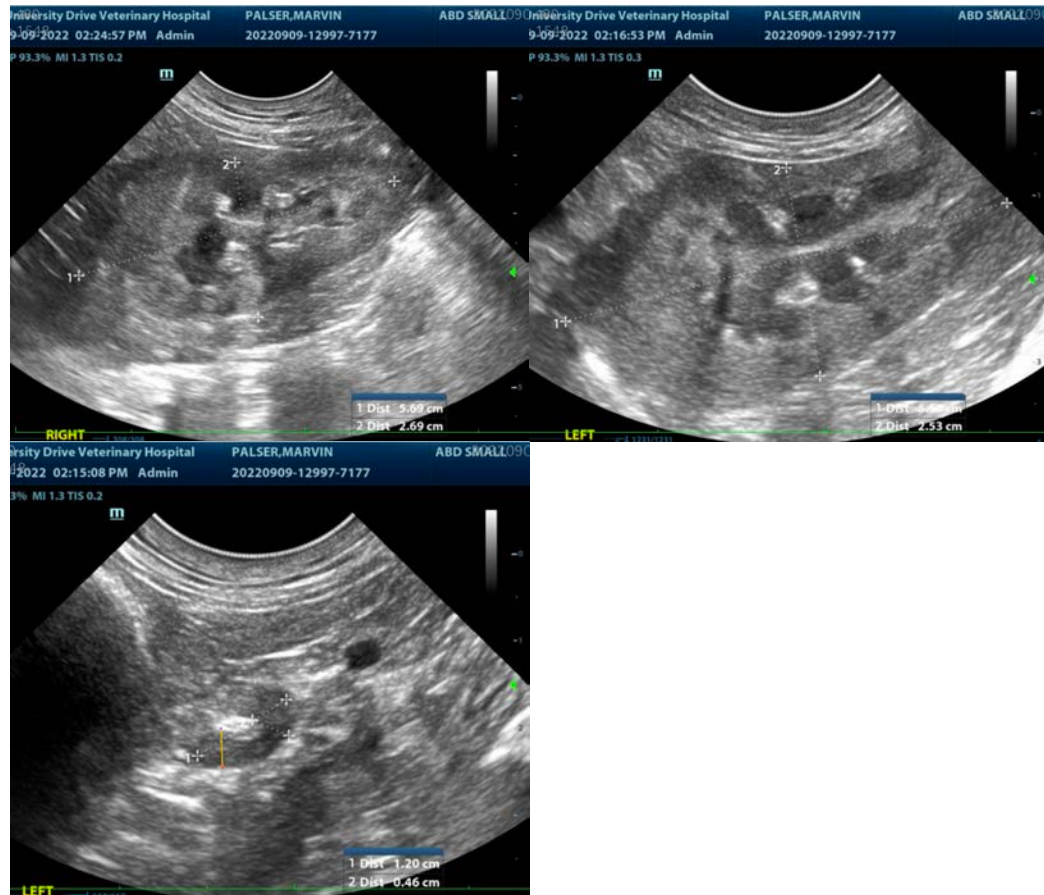
Dr. Susan Lincoski

INVOICE

41134

DATE

9/8/22



The information and recommendations provided are based on the images presented by the referring veterinarian/sonographer. No evaluation can be communicated regarding pathology that was not visible in the image/video clips provided.

Thank you for this referral. If the clinical or image interpretation does not parallel your findings or if I can be of any further assistance please contact me.

Beth Johnson, DVM, DACVIM
Beth.Johnson@sonopath.com