

**PATIENT**

Willow Wawrowski

SPECIES

Canine

BREED

Weimaraner

SEX

Spayed Female

AGE

13 Years

WEIGHT

74 Pounds

INTERPRETED BYBeth Johnson, DVM
DACVIM**IMAGING PERFORMED BY**

Amy Mayhew, LVT

HOSPITAL NAME

SVS Imaging MI

REFERRING VET

Oxford Vet Hospital

INVOICE

41128

DATE

9/7/22

PRESENTING CLINICAL SIGNS

Presented for loose tooth, blood work performed, found increased values
 Abnormal PE/Chem/CBC/UA Results: ALT 396, 12/28/21 was 157, ALP 4796, 12/28/21 was 808
 elevated GGT. Mild decrease total WBC, WNL parameters & hyperlipidemia. Please see attached.

ULTRASONOGRAPHIC EXAMINATION OF THE ABDOMEN**Urinary System**

The urinary bladder is moderately distended with anechoic contents. No masses, inflammatory changes, echogenic sediment or cystoliths are observed. The urinary bladder, trigone and visible pelvic urethra are normal in thickness with a smooth mucosal surface.

The right kidney is normal in size (7.86 cm), shape and echogenicity. It has smooth peripheral margination. There is a normal 1:3 cortex to medulla ratio with appropriate corticomedullary distinction. There is no evidence of pyelectasia, mineral or infarcts observed.

The left kidney is normal in size (7.68 cm), shape and echogenicity. It has smooth peripheral margination. There is a normal 1:3 cortex to medulla ratio with appropriate corticomedullary distinction. There is no evidence of pyelectasia, mineral or infarcts observed.

Adrenal Glands

The right adrenal gland is normal in size (0.67 cm at the cranial pole and 0.57 cm at the caudal pole), shape and contour. Corticomedullary structure is unremarkable. Visible surrounding vasculature appears normal.

The left adrenal gland is normal in size (0.59 cm at the cranial pole and 0.71 cm at the caudal pole), shape and contour. Corticomedullary structure is unremarkable. Visible surrounding vasculature appears normal.

Spleen

The spleen is subjectively normal in size with a normal smooth capsular contour. Parenchyma is appropriately finely textured and homogenous with normal echogenicity relative to surrounding tissue (hyperechoic to liver). No focal nodules or masses are observed. Splenic vasculature appears normal.

Liver

Liver is subjectively enlarged with mildly irregular margins. Parenchyma is heterogenous characterized by multiple poorly defined hypoechoic nodules within otherwise hyperechoic liver parenchyma. Visible vasculature and biliary tree appear normal without distension or congestion.

The gallbladder is non-distended in size. The wall is smooth without visible thickening. Luminal contents are primarily anechoic. There is no evidence of cystic or common bile duct dilation.

Gastrointestinal

The visible stomach wall is normal in thickness and layering. The lumen of the stomach is mildly distended with very echogenic reverberation artifact from intraluminal gas. There is no evidence of obstruction, foreign material or infiltrative disease; however, complete visualization of far wall is partially inhibited by gas. Pyloric outflow tract appears patent.

The visible small intestines are normal in wall thickness and layering (canine duodenum < 0.5 cm and feline duodenum < 0.4 cm; other < 0.3 cm). Small intestinal motility appears adequate (1-3 contractions per min). The lumen of the small intestine is empty with no evidence of obstruction, foreign material or infiltrative disease.

IMAGING PERFORMED BY

SVS Mobile Imaging MI 734-637-7711
svsimagingmi@gmail.com



EDUCATIONAL TELECONSULTATION SERVICES™
1-800-838-4268 info@sonopath.com SonoPath.com

PATIENT

Willow Wawrowski

The visible colon is normal in wall thickness (< 0.2 cm) and layering. Contents are consistent with normal formed feces and gas.

SPECIES

Canine

Pancreas

The pancreatic parenchyma is appropriately isoechoic to surrounding tissue. Visible capsule is smooth and normal in contour. There is no visible pancreatic duct dilation. There is no evidence of active peripancreatic inflammation.

BREED

Weimaraner

Free Abdomen

There is no evidence of free peritoneal effusion noted in these images.

SEX

Spayed Female

There is no apparent lymphadenopathy noted in these images.

ULTRASONOGRAPHIC FINDINGS**AGE**

13 Years

- **Heterogenous Liver** – These changes are most consistent with benign processes such as nodular hyperplasia, steroid (vacuolar) hepatopathy, extramedullary hematopoiesis or possibly chronic inflammatory disease and less commonly infiltrative round cell or metastatic neoplasia.

INTERPRETATION OF THE FINDINGS & FURTHER RECOMMENDATIONS**WEIGHT**

74 Pounds

An obvious cause for the reported increased liver enzymes is not identified in these images. Microscopic disease such as Leptospirosis, bacterial cholangiohepatitis, chronic active hepatitis, copper-associated hepatotoxicity, other hepatotoxicity, infiltrative neoplasia (considered unlikely), etc. cannot be definitively ruled out.

INTERPRETED BY

Beth Johnson, DVM
DACVIM

Given the higher alkaline phosphatase relative to the more mildly increased ALT, other less liver specific differentials including hyperadrenocorticism, chronic infections, inflammation from dental disease, IBD, hyperlipidemia, hyperthyroidism, chronic pancreatitis, chronic stress, etc. also should be considered.

IMAGING PERFORMED BY

Amy Mayhew, LVT

Therefore, recommendations include a “antigen search” for sources of reactive hepatopathy including testing for Leptospirosis, followed by addressing this patient’s reported dental disease, as well as an empirical course of antibiotics and hepatic nutraceuticals with monitoring of liver enzymes for improvement. If improvement is noted, antibiotics should be continued until values either normalize and/or plateau, at which time they should be discontinued. If liver enzymes do not improve, antibiotics should not be continued. If clinical signs of hyperadrenocorticism are present, testing for hyperadrenocorticism is indicated. However, testing should not be pursued without supporting clinical signs.

HOSPITAL NAME

SVS Imaging MI

Ultimately, if a diagnosis is not obtained, and values don’t improve and/or progress, liver sampling in the form of a fine needle aspirate of biopsy may ultimately be warranted.

REFERRING VET

Oxford Vet Hospital

INVOICE

41128

DATE

9/7/22

IMAGING PERFORMED BY

SVS Mobile Imaging MI 734-637-7711
svsimagingmi@gmail.com



PATIENT

Willow Wawrowski

SPECIES

Canine

BREED

Weimaraner

SEX

Spayed Female

AGE

13 Years

WEIGHT

74 Pounds

INTERPRETED BY

Beth Johnson, DVM
DACVIM

IMAGING PERFORMED BY

Amy Mayhew, LVT

HOSPITAL NAME

SVS Imaging MI

REFERRING VET

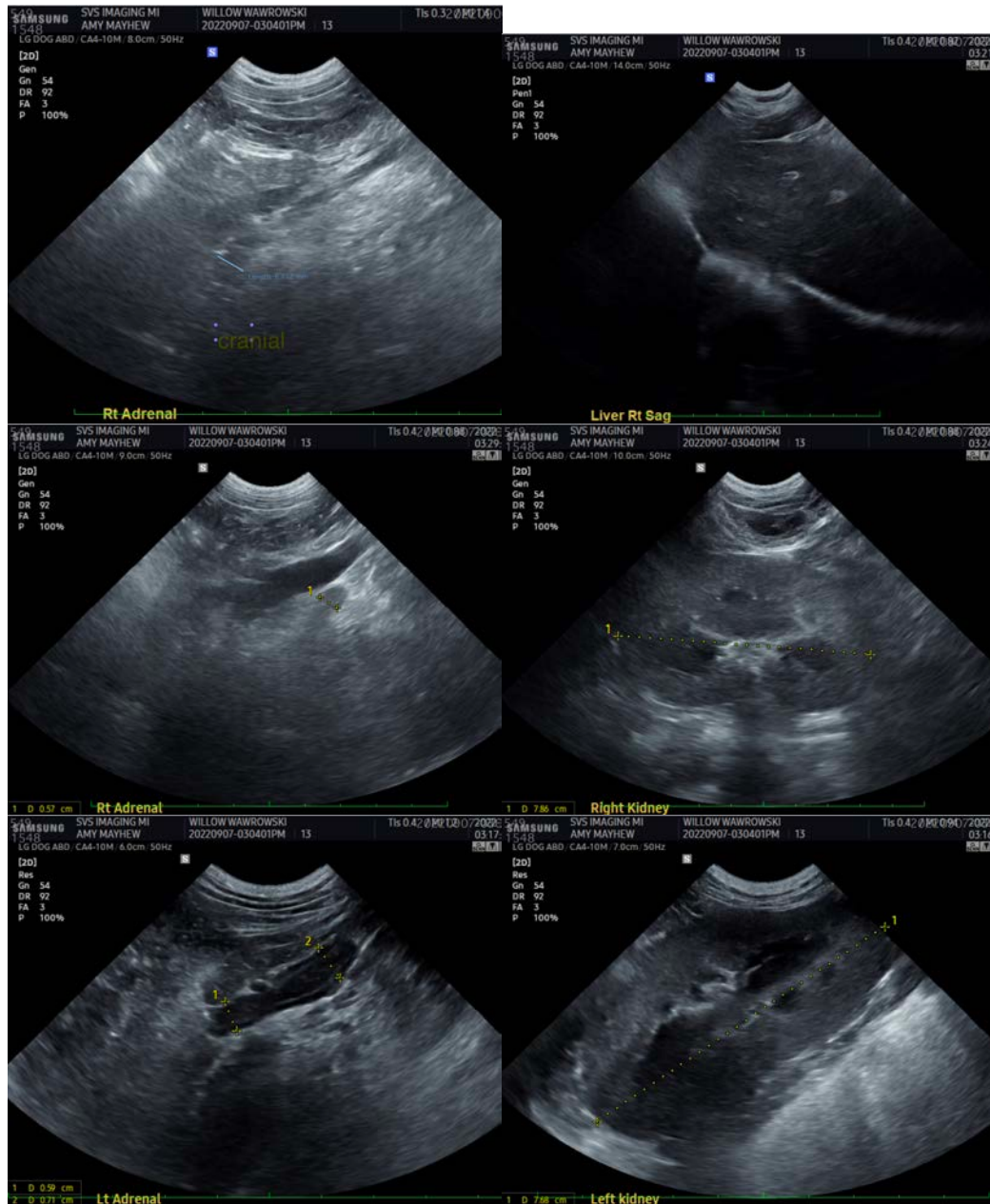
Oxford Vet Hospital

INVOICE

41128

DATE

9/7/22



The information and recommendations provided are based on the images presented by the referring veterinarian/sonographer. No evaluation can be communicated regarding pathology that was not visible in the image/video clips provided.

Thank you for this referral. If the clinical or image interpretation does not parallel your findings or if I can be of any further assistance please contact me.

Beth Johnson, DVM, DACVIM
Beth.Johnson@sonopath.com