



**PATIENT PRESENTING CLINICAL SIGNS**

Rue Anderson Moderate dental disease. Presurgical blood work showed elevated ALP. Recheck after 1 mo on Denosyl now slightly worse

**SPECIES**

Abnormal PE/Chem/CBC/UA Results: ALP 8/4 728 ALP 9/2 1022

Canine

**BREED**

Heeler

**SEX**

Spayed Female

**AGE**

12 Years

**WEIGHT**

35 Pounds

**ULTRASONOGRAPHIC EXAMINATION OF THE ABDOMEN**

**Urinary System**

Urinary bladder is adequately distended with primarily anechoic contents and occasional echogenic non-shadowing debris. Apical urinary bladder wall is diffusely thick (0.52 cm). Mucosa is hyperechoic and irregular. No masses or cystoliths are observed. The trigone and visible pelvic urethra are normal thickness with a smooth mucosal surface.

Kidneys are overall normal in size and shape with smooth peripheral margination. A normal 1:3 cortex to medulla ratio is maintained. The medulla and cortices are uniform in texture with some mild increased cortical echogenicity and mild loss of corticomedullary distinction, expected in this age patient. There is no evidence of pyelectasia, mineral or infarcts observed. The left kidney measures 5.76 cm. The right kidney measures 6.31 cm. Small cortical cysts are noted bilaterally.

**Adrenal Glands**

The right adrenal gland is normal in size (3.3 cm long, 1.78 cm at the cranial pole, 0.34 cm at the caudal pole), shape and contour. Corticomedullary structure is unremarkable. A hyperechoic nodule is noted in the cranial pole. Nodule does not disrupt normal shape and/or architecture. Visible surrounding vasculature appears normal.

The left adrenal gland is normal in size (2.4 cm long, 0.68 cm at the cranial pole, 0.53 cm at the caudal pole), shape and contour. Corticomedullary structure is unremarkable. Visible surrounding vasculature appears normal.

**Spleen**

Spleen is subjectively normal in size with a normal smooth capsular contour. Parenchyma is appropriately finely textured and homogenous with normal echogenicity relative to surrounding tissue (hyperechoic to liver). Multifocal well-demarcated hyperechoic homogenous nodules are noted. Splenic vasculature appears normal.

**Liver**

Liver is subjectively enlarged (swollen contour) without disruption of architecture. It has a normal homogenous echotexture. Parenchyma is diffusely hyperechoic characterized by less prominent than normal portal vein walls and increased echogenicity relative to the spleen and falciform fat. No focal lesions are observed. Visible vasculature and biliary tree appear normal without distension or congestion.

Gallbladder is moderately distended with anechoic bile as well as suspended and gravity dependent echogenic debris. The wall is smooth without visible thickening. There is no evidence of cystic or CBD dilation. There is no evidence of effusion or inflammation.

**INTERPRETED BY**

Beth Johnson, DVM  
DACVIM

**IMAGING PERFORMED BY**

Jenna Walsh, CVT

**HOSPITAL NAME**

Cottage Grove VC

**REFERRING VET**

Dr. Damewood

**INVOICE**

41115

**DATE**

9/7/22



## PATIENT *Gastrointestinal*

Rue Anderson The stomach wall is normal in thickness (canine < 0.5 cm and feline < 0.4 cm) and layering. The lumen of the stomach is empty with no evidence of obstruction, foreign material or infiltrative disease. Pyloric outflow tract appears patent.

## SPECIES

Canine The visible small intestines are normal in wall thickness and layering (canine duodenum < 0.5 cm and feline duodenum < 0.4 cm; other < 0.3 cm). Small intestinal motility appears adequate (1-3 contractions per min). The lumen of the small intestine is empty with no evidence of obstruction, foreign material or infiltrative disease.

## BREED

Heeler The visible colon is normal in wall thickness (< 0.2 cm) and layering. Contents are consistent with normal formed feces and gas.

## SEX

Spayed Female

## AGE

12 Years

## *Pancreas*

The pancreatic parenchyma is appropriately isoechoic to surrounding tissue. Visible capsule is smooth and normal in contour. There is no visible pancreatic duct dilation. There is no evidence of active peripancreatic inflammation.

## *Free Abdomen*

There is no evidence of free peritoneal effusion noted in these images.

## WEIGHT

35 Pounds

There is no apparent lymphadenopathy noted in these images.

## INTERPRETED BY

Beth Johnson, DVM  
DACVIM

## PRIMARY FINDINGS

- **Hyperechoic adrenal nodule (cranial pole right adrenal gland)** – Differentials include primary adrenal cortical adenoma or adenocarcinoma, pheochromocytoma, myelolipoma, adrenal hyperplasia secondary to pituitary disease or metastatic disease. Ultrasound alone cannot differentiate between functional and non-functional nodules and/or between benign and malignant disease. Small nodules without other evidence of abdominal disease (to suggest metastatic disease) and/or clinical signs (to suggest adrenal disease) are most often incidental and should be monitored.
- **Hyperechoic hepatomegaly** - This appearance is non-specific and most consistent with a benign steroid (endocrine) or vacuolar hepatopathy or reactive or idiopathic hepatopathy. Inflammatory and/or infiltrative disease (such as round cell neoplasia) are also possible, but considered less likely.
- **Gallbladder debris** - Cholecystic debris is of unknown clinical significance. It can be seen with biliary stasis from fasting or illness. Cholecystic debris is not necessarily related to hepatobiliary disease. Echogenic bile is most commonly an incidental finding in dogs and should be interpreted in combination with clinical signs such as nausea, inappetence, cranial abdominal discomfort and/or laboratory changes such as increased ALP and/or increased Tbili.

## IMAGING PERFORMED BY

Jenna Walsh, CVT

## HOSPITAL NAME

Cottage Grove VC

## REFERRING VET

Dr. Damewood

## INVOICE

41115

## DATE

9/7/22

## SECONDARY FINDINGS

- **Hyperechoic splenic nodules** – most consistent with benign myelolipomas. Other differentials such as fibrosis or calcification caused by old hematomas or infarcts, chronic inflammation, granulomatous disease or metastatic disease cannot be ruled out, but are considered less likely.



## PATIENT

Rue Anderson

- **Chronic Cystitis** - Urinary bladder wall changes are most consistent with chronic cystitis. Infiltrative neoplasia cannot be ruled out but is considered less likely give the location and diffuse nature of the changes.

## SPECIES

Canine

- Age related kidney changes

## BREED

Heeler

## SEX

Spayed Female

## AGE

12 Years

## WEIGHT

35 Pounds

## INTERPRETED BY

Beth Johnson, DVM  
DACVIM

## INTERPRETATION OF THE FINDINGS & FURTHER RECOMMENDATIONS

Differentials for increased alkaline phosphatase are vast and non-specific. Differentials include, but are not limited to, benign nodular hyperplasia which occurs in 70% of older dogs and often does not result in an abnormal ultrasound, reactive or idiopathic/vacuolar hepatopathy, cholestasis and/or hyperadrenocorticism as well as many chronic non-hepatobiliary diseases such as chronic infections/inflammation from dental disease, IBD, neoplasia, hyperlipidemia, hypothyroidism, chronic pancreatitis, chronic stress, etc.

There is no ultrasonographic evidence of cholestasis. Adrenocortical testing such as a low dose dexamethasone suppression test could be considered if clinical signs of hyperadrenocorticism are present. Ursodiol could be considered if gallbladder sludge is noted. A fine needle aspirate of the liver could be considered if patient's coagulation status is appropriate. Otherwise, recommendations include addressing any other concurrent disease and monitoring. If values are progressive, recheck imaging is recommended.

Urinalysis and, if indicated based on urinalysis results, urine culture are recommended. If protein is present in an otherwise quiet sediment, protein quantification with a urine protein to creatinine ration is recommended.

If clinical signs of hyperadrenocorticism are not present, then testing is not indicated, and recommendations include addressing this patient's reported dental disease with monitoring of ALP for improvement post procedure.

## IMAGING PERFORMED BY

Jenna Walsh, CVT

## HOSPITAL NAME

Cottage Grove VC

## REFERRING VET

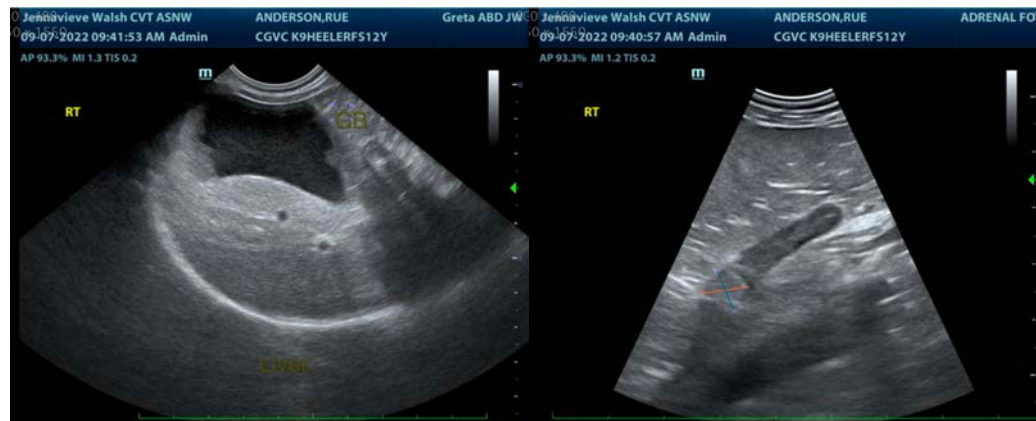Dr. Damewood

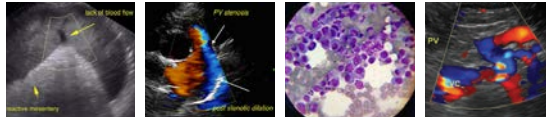
## INVOICE

41115

## DATE

9/7/22





**PATIENT**

Rue Anderson

**SPECIES**

Canine

**BREED**

Heeler

**SEX**

Spayed Female

**AGE**

12 Years

**WEIGHT**

35 Pounds

**INTERPRETED BY**

Beth Johnson, DVM  
DACVIM

**IMAGING PERFORMED BY**

Jenna Walsh, CVT

**HOSPITAL NAME**

Cottage Grove VC

**REFERRING VET**

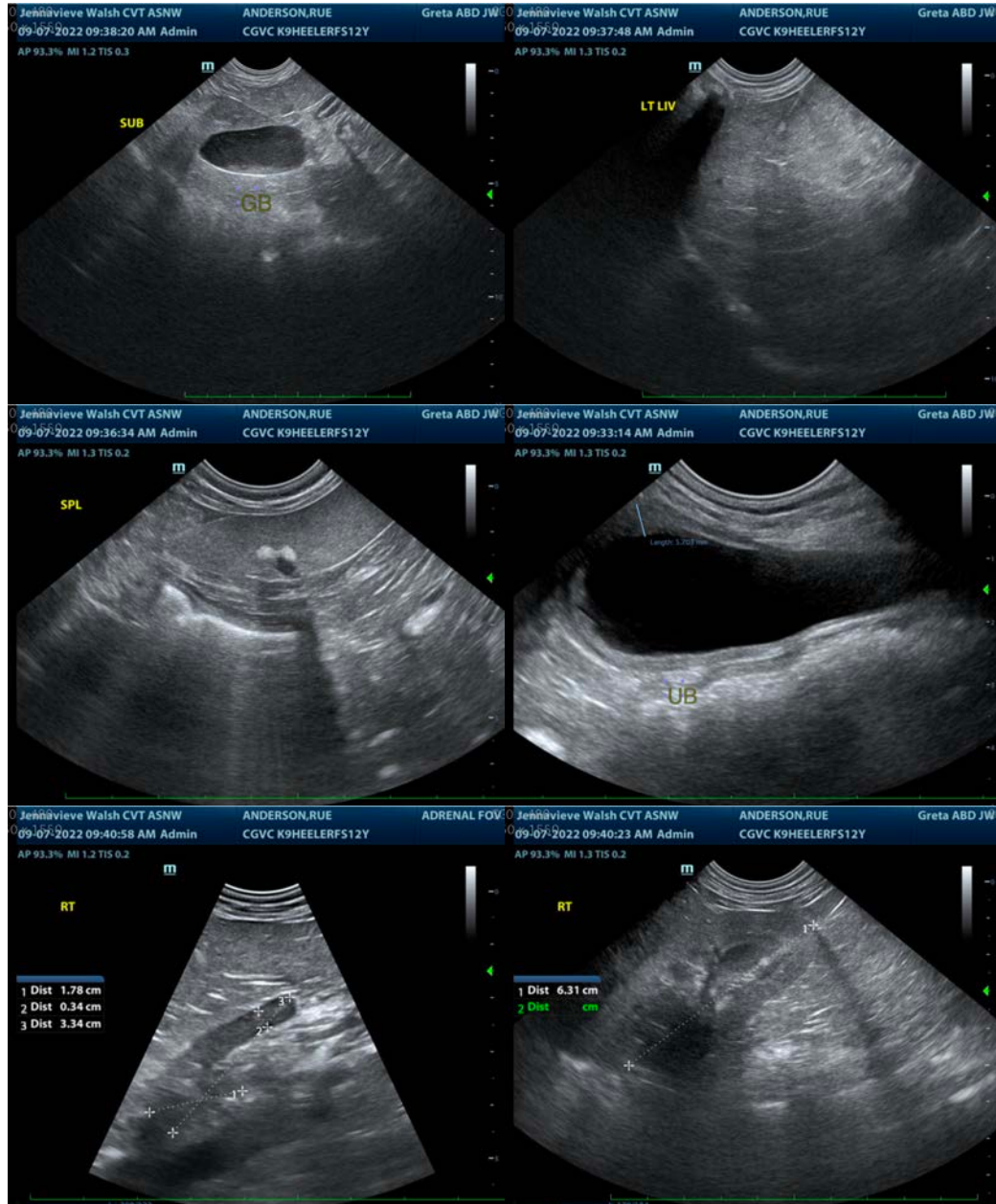
Dr. Damewood

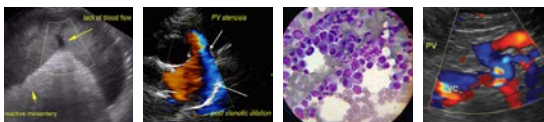
**INVOICE**

41115

**DATE**

9/7/22





## PATIENT

Rue Anderson

## SPECIES

Canine

## BREED

Heeler

## SEX

Spayed Female

## AGE

12 Years

## WEIGHT

35 Pounds

## INTERPRETED BY

Beth Johnson, DVM  
DACVIM

## IMAGING PERFORMED BY

Jenna Walsh, CVT

## HOSPITAL NAME

Cottage Grove VC

## REFERRING VET

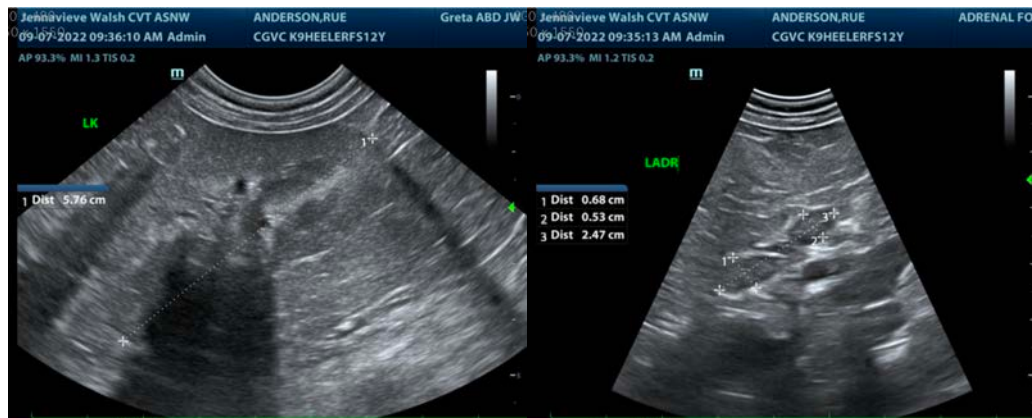
Dr. Damewood

## INVOICE

41115

## DATE

9/7/22



The information and recommendations provided are based on the images presented by the referring veterinarian/sonographer. No evaluation can be communicated regarding pathology that was not visible in the image/video clips provided.

Thank you for this referral. If the clinical or image interpretation does not parallel your findings or if I can be of any further assistance please contact me.

**Beth Johnson, DVM, DACVIM**  
Beth.Johnson@sonopath.com