



**PATIENT**

Archie Rief

**SPECIES**

Canine

**BREED**

Wheaten Terrier

**SEX**

Neutered Male

**AGE**

10 Years

**WEIGHT**

12.1 kg

**INTERPRETED BY**

Beth Johnson, DVM  
DACVIM

**IMAGING PERFORMED BY**

Evan Bell

**HOSPITAL NAME**

Cedarview AH

**REFERRING VET**

Dr. Kim Holzman

**INVOICE**

41766

**DATE**

9/29/22

**PRESENTING CLINICAL SIGNS**

Vomiting once daily for past several weeks at night. Combination of food and bile. Has never had a great appetite but seems to be unchanged. Initially overnight with hypersalivation and improved with later snacks (late evening before bed) but now occurring during the day when owner out. Has mild weight loss. Remains BAR at home. Ddx stress, heat, dietary intolerance, foreign body, parasitic, inflammatory, infectious, neoplastic etc.

Abnormal PE/Chem/CBC/UA Results: Globulins increased to 48 otherwise CBC normal, chemistry, lytes normal GI panel (incl cPLI) and random cortisol pending.

**ULTRASONOGRAPHIC EXAMINATION OF THE ABDOMEN**

**Urinary System**

The urinary bladder is moderately distended with anechoic contents. No masses, inflammatory changes, echogenic sediment or cystoliths are observed. The urinary bladder, trigone and visible pelvic urethra are normal in thickness with a smooth mucosal surface.

Prostate is normal in size, echotexture and echogenicity for a neutered male.

The right kidney is normal in size (5.0 cm), shape and echogenicity. It has smooth peripheral margination. There is a normal 1:3 cortex to medulla ratio with appropriate corticomedullary distinction. There is no evidence of pyelectasia or infarcts observed. Non-obstructive linear multifocal hyperechoic diverticular foci with acoustic shadowing are noted.

The left kidney is normal in size (5.0 cm), shape and echogenicity. It has smooth peripheral margination. There is a normal 1:3 cortex to medulla ratio with appropriate corticomedullary distinction. There is no evidence of pyelectasia or infarcts observed. Non-obstructive linear multifocal hyperechoic diverticular foci with acoustic shadowing are noted.

**Adrenal Glands**

The area of the right adrenal gland is examined without evident pathology.

The left adrenal gland is normal in size (0.48 cm at the cranial pole and 0.64 cm at the caudal pole), shape and contour. Corticomedullary structure is unremarkable. Visible surrounding vasculature appears normal.

**Spleen**

Spleen is subjectively large in size with normal smooth margins. Parenchyma is normal in echogenicity with a coarse/heterogenous echotexture. No focal nodules or masses are observed. Splenic vasculature appears normal.

**Liver**

The liver is subjectively normal in size with normal smooth curvilinear peripheral contour. Parenchyma is appropriately hypoechoic to the spleen in echogenicity and appropriately mildly coarse and homogenous in echotexture. No focal lesions are observed. Visible vasculature and biliary tree appear normal without distension or congestion.

Gallbladder is moderately distended with anechoic bile as well as suspended and gravity dependent echogenic debris. The wall is smooth without visible thickening. There is no evidence of cystic or CBD dilation. There is no evidence of effusion or inflammation.



**PATIENT**

Archie Rief

**SPECIES**

Canine

**BREED**

Wheaten Terrier

**SEX**

Neutered Male

**AGE**

10 Years

**WEIGHT**

12.1 kg

**INTERPRETED BY**

Beth Johnson, DVM  
DACVIM

**IMAGING PERFORMED BY**

Evan Bell

**HOSPITAL NAME**

Cedarview AH

**REFERRING VET**

Dr. Kim Holzman

**INVOICE**

41766

**DATE**

9/29/22

**Gastrointestinal**

Fundic mucosal hypertrophy with hyperechoic mucosa and some mucosal remodeling is noted. There is no loss of mural detail. Layering is normal. There is mild luminal fluid accumulation. No evidence of masses/nodules or foreign material present. There is some echogenic chyme/fluid/likely normal ingesta entering the pylorus. Obstructive foreign material can't be ruled out but is considered less likely.

The visible small intestines are normal in wall thickness and layering (canine duodenum < 0.5 cm and feline duodenum < 0.4 cm; other < 0.3 cm). Small intestinal motility appears adequate (1-3 contractions per min). The lumen of the small intestine is empty with no evidence of obstruction, foreign material or infiltrative disease.

The visible colon is normal in wall thickness (< 0.2 cm) and layering. Contents are consistent with normal formed feces and gas.

**Pancreas**

The pancreatic parenchyma is appropriately isoechoic to surrounding tissue. Visible capsule is smooth and normal in contour. There is no visible pancreatic duct dilation. There is no evidence of active peripancreatic inflammation.

**Free Abdomen**

There is no evidence of free peritoneal effusion noted in these images.

There is one ovoid shaped hypoechoic cranial abdominal lymph node/pancreaticoduodenal lymph node noted.

**PRIMARY FINDINGS**

- **Gastritis** – Consistent with irritation secondary to dietary indiscretion or intolerance, infection (bacterial, viral, other), parasitic or protozoal disease, toxin, other metabolic disease such as pancreatitis, other. Microulceration cannot be ruled out. \*\*Delayed gastric emptying is suspected. A partial outflow obstruction cannot be definitively ruled out but is considered less likely than just normal chyme/fluid/ingesta within the pylorus.
- **Coarse splenomegaly** – can be associated with congestion caused by sedation (if sedated) but can also be associated with diffuse infiltrative disease. Both benign conditions such as extramedullary hematopoiesis, lymphoid hyperplasia, as well as infiltrative neoplastic diseases such as round cell neoplasia should be considered.
- **Reactive cranial abdominal lymphadenopathy** – Infiltrative neoplasia can't be ruled out but is considered less likely.

**SECONDARY FINDINGS**

- **Gallbladder debris** - Cholecystic debris is of unknown clinical significance. It can be seen with biliary stasis from fasting or illness. Cholecystic debris is not necessarily related to hepatobiliary disease. Echogenic bile is most commonly an incidental finding in dogs and should be interpreted in combination with clinical signs such as nausea, inappetence, cranial abdominal discomfort and/or laboratory changes such as increased ALP and/or increased Tbili.
- Non-obstructive dystrophic mineralization in the kidneys



**PATIENT**

Archie Rief

**SPECIES**

Canine

**BREED**

Wheaten Terrier

**SEX**

Neutered Male

**AGE**

10 Years

**WEIGHT**

12.1 kg

**INTERPRETED BY**

Beth Johnson, DVM  
DACVIM

**IMAGING PERFORMED BY**

Evan Bell

**HOSPITAL NAME**

Cedarview AH

**REFERRING VET**

Dr. Kim Holzman

**INVOICE**

41766

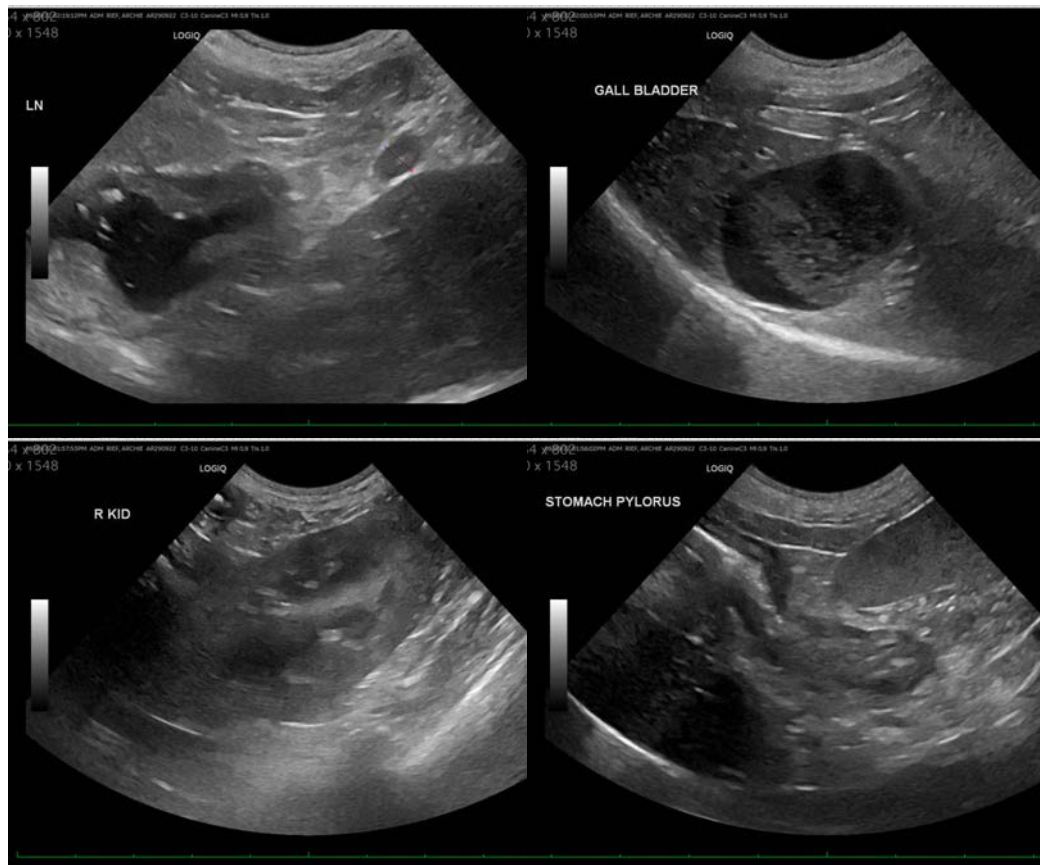
**DATE**

9/29/22

**INTERPRETATION OF THE FINDINGS & FURTHER RECOMMENDATIONS**

As is already reportedly pending, a gastrointestinal malabsorption panel and baseline cortisol are recommended. In the meantime, recommendations include management of gastritis and potentially concurrent GERD with antiemetics and gastroprotectants (twice daily Omeprazole). Additionally, a helicobacter protocol of your choice could be considered. Transition to a hydrolyzed protein diet could be considered on a trial-and-error basis. A fine needle aspirate of the liver is recommended if patient's coagulation status is appropriate.

Ultimately, however, if medical management of gastritis/GERD does not result in improvement of clinical signs, and a diagnosis is not obtained from pending lab work, upper GI endoscopy for further evaluation of gastric mucosa, gastric outflow tract, and duodenum with biopsies at the time of the procedure may be warranted.





**PATIENT**

Archie Rief

**SPECIES**

Canine

**BREED**

Wheaten Terrier

**SEX**

Neutered Male

**AGE**

10 Years

**WEIGHT**

12.1 kg

**INTERPRETED BY**

Beth Johnson, DVM  
DACVIM

**IMAGING PERFORMED BY**

Evan Bell

**HOSPITAL NAME**

Cedarview AH

**REFERRING VET**

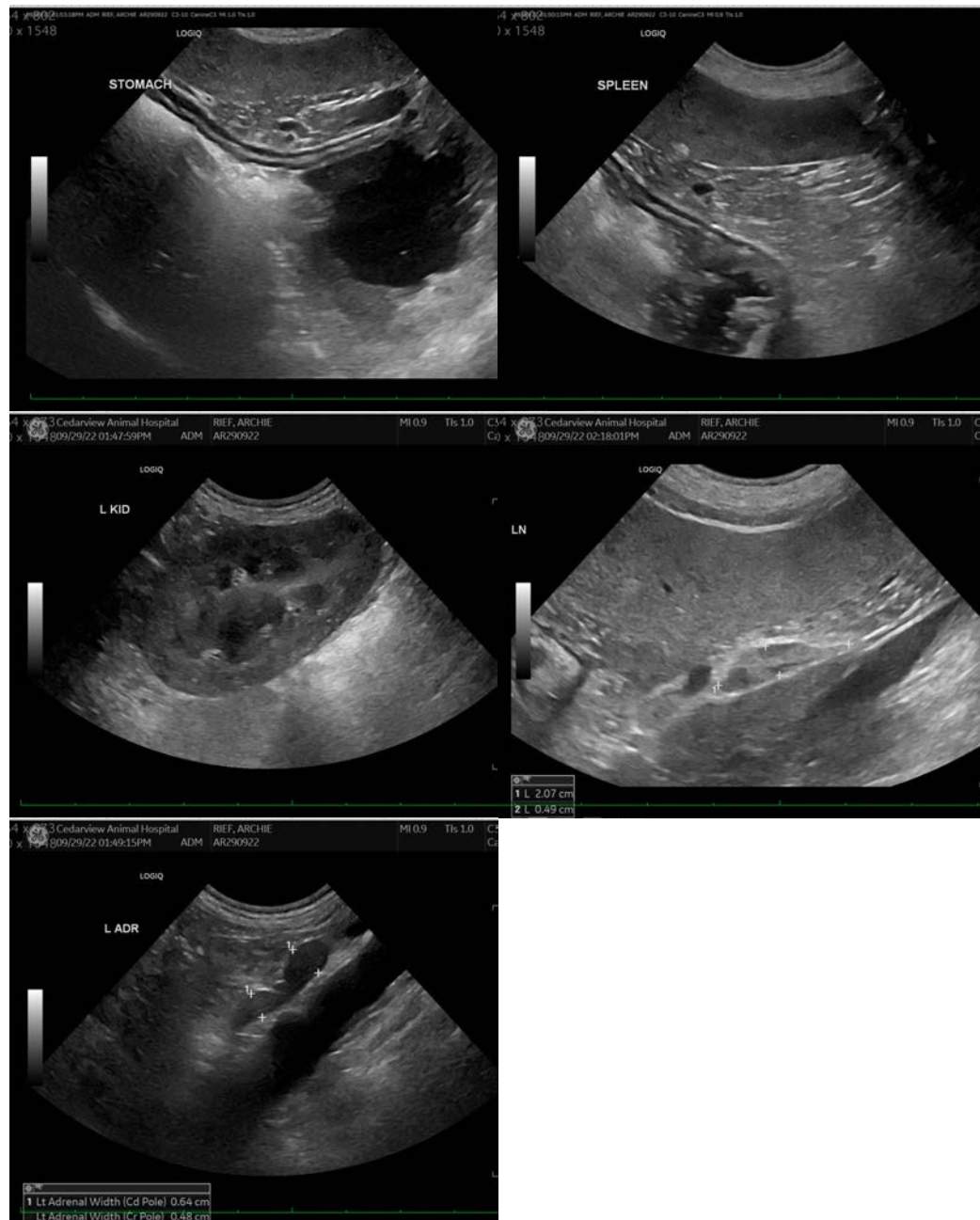
Dr. Kim Holzman

**INVOICE**

41766

**DATE**

9/29/22



The information and recommendations provided are based on the images presented by the referring veterinarian/sonographer. No evaluation can be communicated regarding pathology that was not visible in the image/video clips provided.

Thank you for this referral. If the clinical or image interpretation does not parallel your findings or if I can be of any further assistance please contact me.

**Beth Johnson, DVM, DACVIM**

Beth.Johnson@sonopath.com