

**DATE PRESENTING CLINICAL SIGNS**

9/27/22 Presented for weakness in the hind end. Took radiographs and incidentally found a large mass in the abdomen.

PATIENT

Alix Sewell Current Medications: Galliprant 60mg (1 tab) PO q24hr #1 bottle, Prednisone 20mg (2tab) PO q12hr #120 tabs. O to purchase Adaquan through Chewy

SPECIES

Canine

BREED

German Shepherd

SEX

Spayed Female

AGE

1/6/13

WEIGHT

75 Pounds

INTERPRETED BY

Beth Johnson, DVM
DACVIM

IMAGING PERFORMED BY

Rachel Brilhart RDMS

HOSPITAL NAME

Banfield Abingdon

REFERRING VET

Dr. Aylward

INVOICE

41692

Radiographs: Initial interpretation: decreased femoral head coverage bilaterally and arthritic changes present, Incidental findings: vertebral spondylosis, lordosis of spine, gas filled loops of intestines, bladder small; large centrally located oblong mass possibly associated with liver vs spleen vs gastric vs other.
Date of Previous IntraPet Ultrasound: No previous.
Sedation: Required for further imaging.
Stat Report: Not requested.

ULTRASONOGRAPHIC EXAMINATION OF THE ABDOMEN**Urinary System**

The urinary bladder is moderately distended with anechoic contents. No masses, inflammatory changes, echogenic sediment or cystoliths are observed. The urinary bladder, trigone and visible pelvic urethra are normal in thickness with a smooth mucosal surface.

The right kidney is normal in size (6.45 cm), shape and echogenicity. It has smooth peripheral margination. There is a normal 1:3 cortex to medulla ratio with appropriate corticomedullary distinction. There is no evidence of pyelectasia, mineral or infarcts observed.

The left kidney is normal in size (6.24 cm), shape and echogenicity. It has smooth peripheral margination. There is a normal 1:3 cortex to medulla ratio with appropriate corticomedullary distinction. There is no evidence of pyelectasia, mineral or infarcts observed.

Adrenal Glands

The right adrenal gland is normal in size (3.8 cm long x 0.74 cm at the cranial pole and 0.53 cm at the caudal pole), shape and contour. Corticomedullary structure is unremarkable. Visible surrounding vasculature appears normal.

The left adrenal gland is normal in size (3.5 cm long x 0.54 cm at the cranial pole and 0.53 cm at the caudal pole), shape and contour. Corticomedullary structure is unremarkable. Visible surrounding vasculature appears normal.

Spleen

Spleen is subjectively large in size with normal smooth margins. Parenchyma is normal in echogenicity with a coarse/heterogenous echotexture. No focal nodules or masses are observed. Splenic vasculature appears normal. Additionally, the spleen is folded upon itself, which is a positional, typically non-pathologic variant.

Liver

Liver is relatively normal in size and contour. Parenchyma is mildly heterogenous and coarse with mild likely age-related parenchymal remodeling noted. No focal lesions are observed. Visible vasculature and biliary tree appear normal without distension or congestion.

Gallbladder is non-distended in size. The wall is smooth without visible thickening. Luminal contents are primarily anechoic with some echogenic debris noted, including some mineral/sand debris. There is no evidence of cystic or common bile duct dilation.

Gastrointestinal

The visible stomach wall is normal in thickness and layering. The lumen of the stomach is mildly distended with very echogenic reverberation artifact from intraluminal gas. There is no evidence of obstruction, foreign material or infiltrative disease; however, complete visualization of far wall is partially inhibited by gas. Pyloric outflow tract appears patent.

The visible small intestines are normal in wall thickness and layering (canine duodenum < 0.5 cm and feline duodenum < 0.4 cm; other < 0.3 cm). Small intestinal motility appears adequate (1-3 contractions per min). The lumen of the small intestine is empty with no evidence of obstruction, foreign material or infiltrative disease.

The visible colon is normal in wall thickness (< 0.2 cm) and layering. Contents are consistent with normal formed feces and gas.

Pancreas

The pancreatic parenchyma is appropriately isoechoic to surrounding tissue. Visible capsule is smooth and normal in contour. There is no visible pancreatic duct dilation. There is no evidence of active peripancreatic inflammation.

Free Abdomen

There is no evidence of free peritoneal effusion noted in these images.

There is no apparent lymphadenopathy noted in these images.

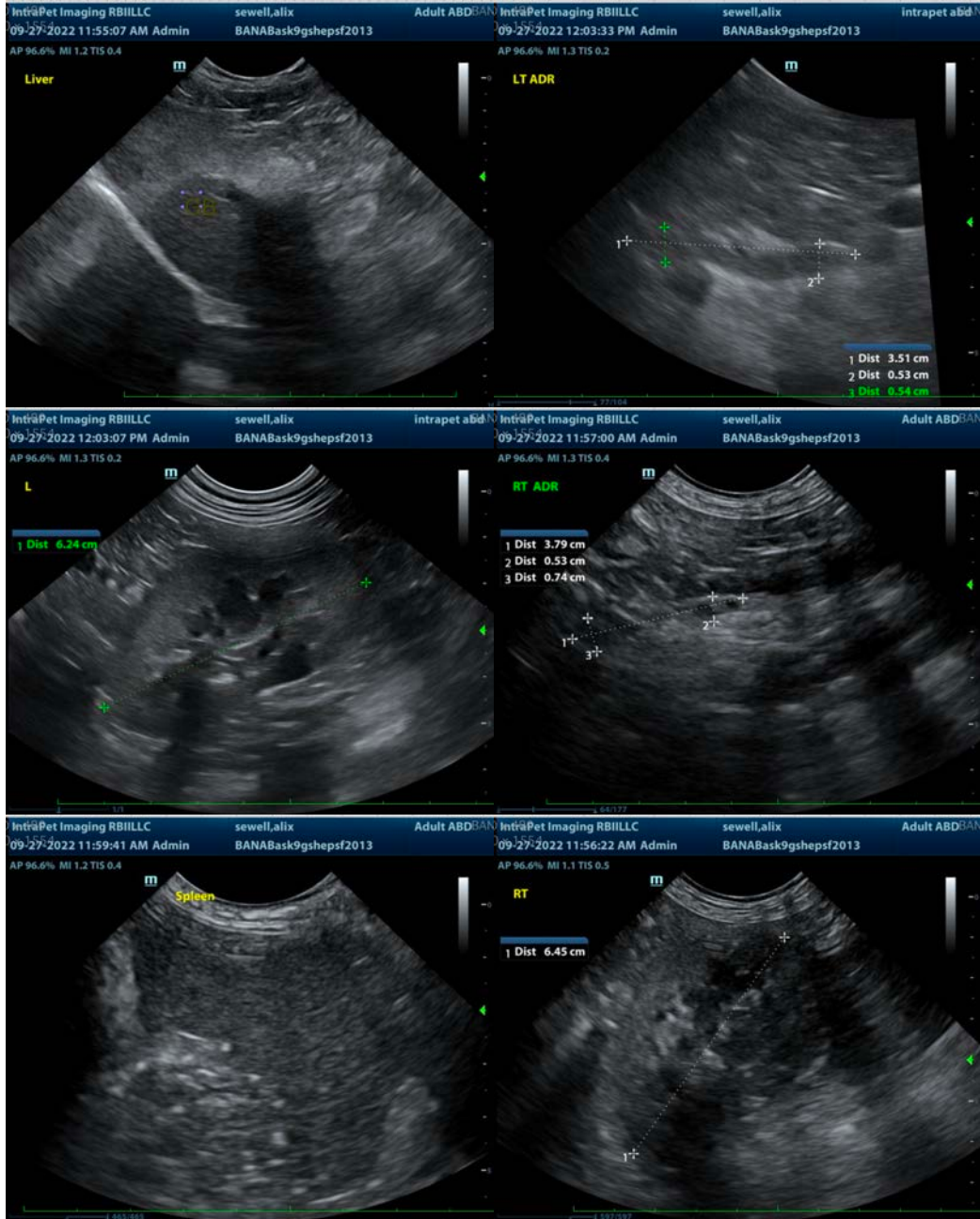
ULTRASONOGRAPHIC FINDINGS

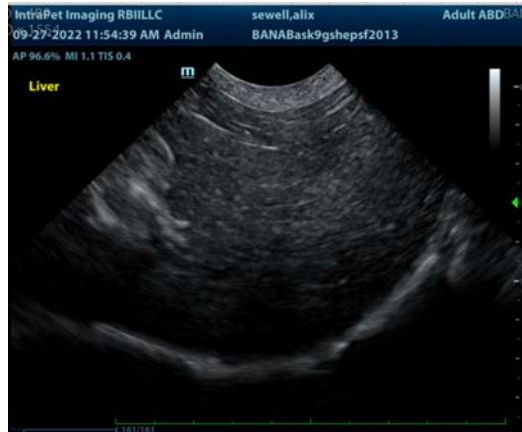- **Coarse splenomegaly** – can be associated with congestion caused by sedation (if sedated) but can also be associated with diffuse infiltrative disease. Both benign conditions such as extramedullary hematopoiesis, lymphoid hyperplasia as well as infiltrative neoplastic diseases such as round cell neoplasia should be considered.
- Age related hepatic remodeling with mild cholecystic debris

INTERPRETATION OF THE FINDINGS & FURTHER RECOMMENDATIONS

The exam was mildly limited by patient vocalization and lack of cooperation, despite sedation. If further imaging is required, additional sedation would be recommended.

There is no ultrasonographically visible evidence of an abdominal mass present in these images at this time. Perhaps the folded splenomegaly looked like a splenic mass radiographically. A fine needle aspirate of the spleen could be considered if patient's coagulation status is appropriate. However, given the presenting complain of pelvic limb weakness, recommendations are to address that primarily, having rule out an abdominal mass.





The information and recommendations provided are based on the images presented by the referring veterinarian/sonographer. No evaluation can be communicated regarding pathology that was not visible in the image/video clips provided.

Thank you for this referral. If the clinical or image interpretation does not parallel your findings or if I can be of any further assistance please contact me.

Beth Johnson, DVM, DACVIM
Beth.Johnson@sonopath.com