

**DATE**

9/26/22

PRESENTING CLINICAL SIGNS**PATIENT**

Pebbles Schilcht

History: Patient was initially presented on 09/21 for inappropriate urination and a few episodes vomiting. At that visit, bladder was unable to be palpated. T was 104.4, otherwise the PE was NSF. She was treated for FLUTD with onsiar and convenia and was given cerenia for nausea. She returned on 09/23/2022 for further work up as she hadn't really improved. Full BW and rads were obtained

SPECIES

Feline

Current Medications: zeniquin: 12.5 mg PO SID

Lab Results: CBC: Hct 26%, no reticulocytosis, WBC: 30,000- neutrophils 27,500. Chem: Glucose 209 - attributed to stress, otherwise unremarkable.

Radiographs: left renomegaly.

BREED

DSH

Date of Previous IntraPet Ultrasound: No previous.

Sedation: Not required to complete full diagnostic ultrasound.

Stat Report: Not requested.

Imaging Performed By: Rachel Brillhart, RDMS.

SEX

Spayed Female

ULTRASONOGRAPHIC EXAMINATION OF THE ABDOMEN**AGE**

8/9/20

Urinary System

Urinary bladder is only mildly distended (empty). Visible contents are anechoic. Urinary bladder wall is unable to be fully assessed for pathology without further distension. No visible masses or cystoliths are observed. The trigone and visible pelvic urethra are normal thickness with a smooth mucosal surface. If there are urinary signs and/or concern for urinary bladder pathology, reassessment after complete filling is recommended.

WEIGHT

8 Pounds

Kidneys are bilaterally uniformly enlarged/swollen (left kidney measures 4.24 cm, the right kidney measures 3.34 cm) with an overall hyperechoic echogenicity and slight loss of corticomedullary definition. The left kidney appears to be more severely affected than the right. Normal smooth peripheral margination and shape are maintained. The renal pelvis are dilated with anechoic fluid and hyperechoic thickened pelvic fat. No overt evidence of neoplasia is observed. The perinephric area is enhanced by hyperechoic fat and mesentery. Mineral sand/debris within the pelvis of the left kidney, in addition to the hyperechoic fat cannot be definitively ruled out. A hyperechoic band parallel to the corticomedullary border is present bilaterally.

INTERPRETED BYBeth Johnson, DVM
DACVIM**Adrenal Glands**

Left adrenal gland is normal in size (0.59 cm), shape and overall architecture, echogenicity and echotexture. Visible surrounding vasculature appears normal.

HOSPITAL NAME

Madonna VC

REFERRING VET

Dr. Smith

Right adrenal gland is normal in size (0.41 cm), shape and overall architecture, echogenicity and echotexture. Visible surrounding vasculature appears normal.

INVOICE

17456

Spleen

Spleen is subjectively large in size with a normal smooth capsular contour. Parenchyma is appropriately finely textured and homogenous with normal echogenicity relative to surrounding tissue (hyperechoic to liver). No focal nodules or masses are observed. Splenic vasculature appears normal. The spleen is folded upon itself, which is a positional non-pathologic variant.

Liver

Liver is subjectively normal in size with normal smooth curvilinear peripheral contour. Parenchyma is appropriately hypoechoic to the spleen in echogenicity and appropriately mildly coarse and homogenous in

echotexture. No focal lesions are observed. Visible vasculature and biliary tree appear normal without distension or congestion.

Gallbladder is non-distended in size. The wall is smooth without visible thickening. Luminal contents are primarily anechoic. There is no evidence of cystic or common bile duct dilation.

Gastrointestinal

The visible stomach wall is normal in thickness and layering. The lumen of the stomach is empty with no evidence of obstruction, foreign material or infiltrative disease. Pyloric outflow tract appears patent.

The visible small intestines are normal in wall thickness and layering. Small intestinal motility appears adequate (1-3 contractions per min). The lumen of the small intestine is empty with no evidence of obstruction, foreign material or infiltrative disease.

The visible colon is normal in wall thickness and layering. Contents are consistent with normal formed feces and gas.

Pancreas

The pancreas is visible and mildly prominent in size and mildly hypoechoic to surrounding tissue with a mildly coarse parenchyma. There is no visible pancreatic duct dilation. There is no evidence of active peripancreatic inflammation.

Free Abdomen

There is no evidence of peritoneal effusion. There is no apparent lymphadenopathy.

ULTRASONOGRAPHIC FINDINGS

Primary Findings

- Pyelectasia – Differentials for pyelectasia include pyelonephritis, diuresis, congenital malformation or ureteral or lower urinary tract obstruction.
- Mild or resolving acute pancreatitis is possible and can't be ruled out versus normal patient variant

Secondary Findings

- Folded spleen, as described above

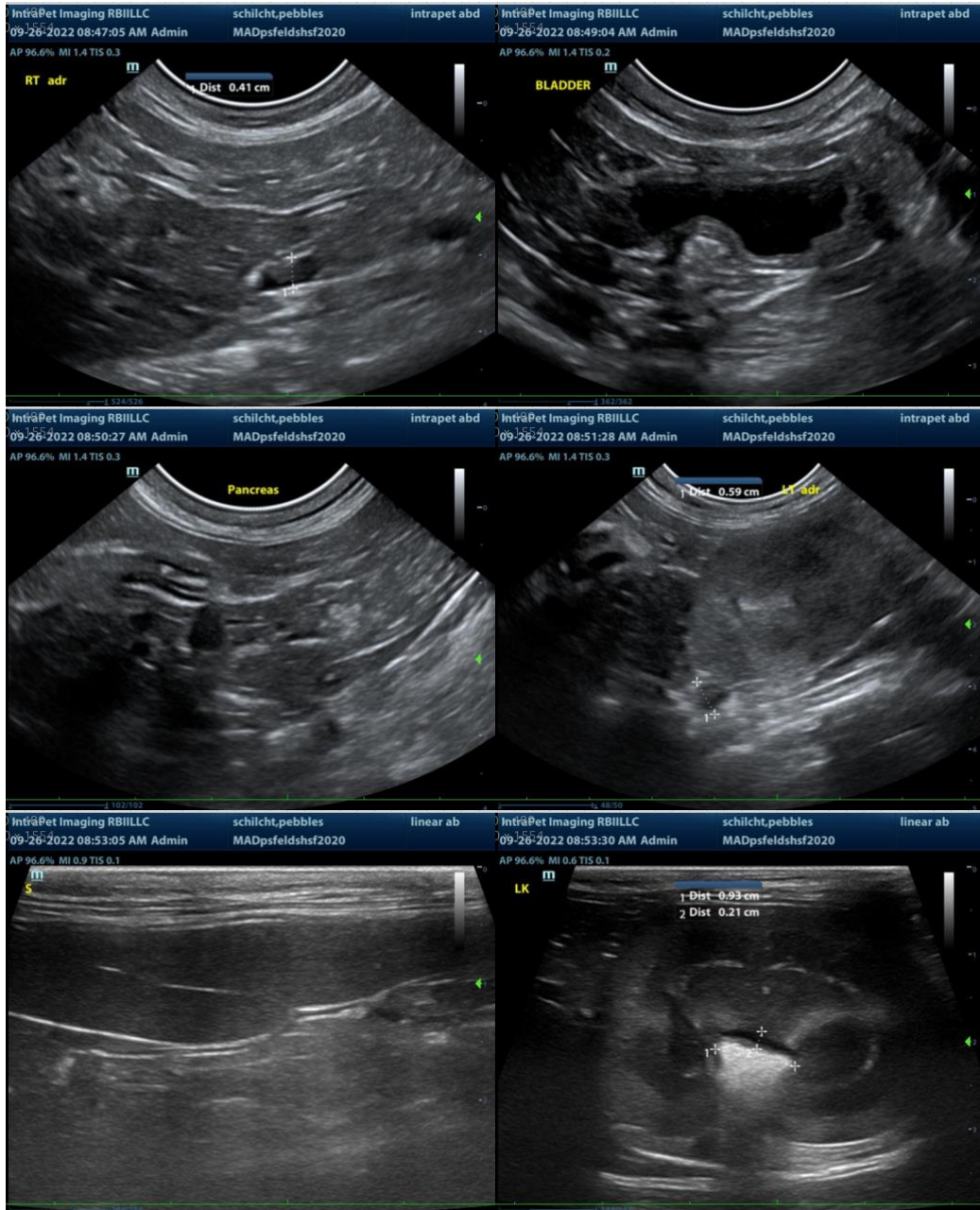
INTERPRETATION OF THE FINDINGS & FURTHER RECOMMENDATIONS

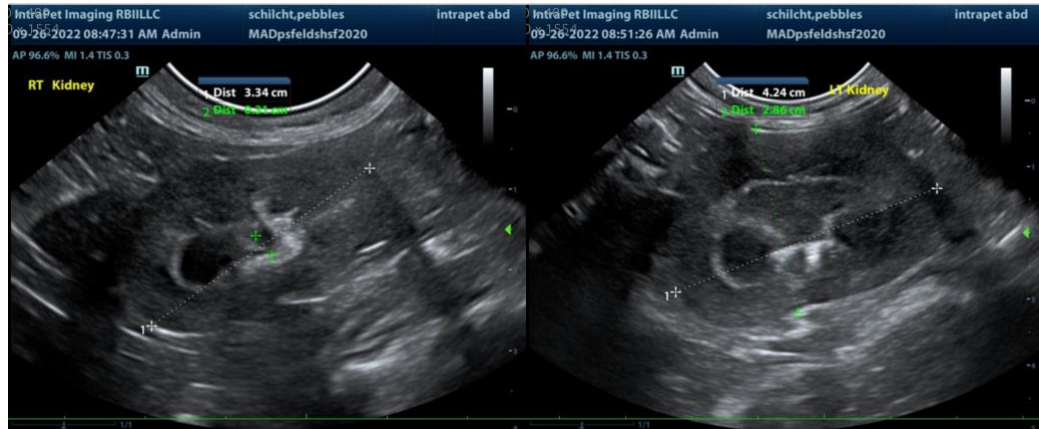
Urinalysis and, if indicated based on urinalysis results, urine culture are recommended. If protein is present in an otherwise quiet sediment, protein quantification with a urine protein to creatinine ration is recommended.

A gastrointestinal malabsorption panel (including cobalamin, folate, TLI and PLI) to Texas A&M GI Laboratory is recommended for further evaluation of GI and pancreatic function. If a full GI panel isn't elected, then a quantitative PLI.

In the meantime, supportive/symptomatic medical management of suspected pyelonephritis with fluid therapy, broad spectrum antibiotics, pain management (if indicated), as well as supportive therapy for gastrointestinal signs, etc. is recommended with monitoring of clinical signs and laboratory changes, etc. for

improvement.





The information and recommendations provided are based on the images presented by the referring veterinarian. No evaluation can be communicated regarding pathology that was not visible in the image/video clips provided.

Thank you for this referral. If the clinical or image interpretation does not parallel your findings or if I can be of any further assistance please contact me.

Beth Johnson, DVM DACVIM
Beth.Johnson@SonoPath.com