

**DATE PRESENTING CLINICAL SIGNS**

9/23/22

1/8/19 hx of grade 2 MCT (top of head) complete but narrow excision. 1/5/21 grade 2 ST sarcoma R hip. 8/29/22 Increase thirst / leaking urine. some clear mucoid vulvar discharge + loose stool. accidents in house. mild abdominal distension (+/- hepatomegaly) hx of cruciate repair sx RH, crepitus bilateral. SQ masses (3x2 R hock) (7mm R lat thigh) diet: HA VEGETARIAN, RC VEGETARIAN, no current meds

PATIENT

Lucy Mostovoy

SPECIES

Canine

Current Medications: Cytopoint inj 8/29/22

Lab Results: See attached.

Date of Previous IntraPet Ultrasound: No previous.

Sedation: Not required to complete full diagnostic ultrasound.

Stat Report: Not requested.

BREED

American Staffordshire Terrier

SEX

Spayed Female

AGE

12/7/10

WEIGHT

73 Pounds

INTERPRETED BYBeth Johnson, DVM
DACVIM**IMAGING PERFORMED BY**

Rachel Brilhart RDMS

HOSPITAL NAME

Bel Air Vet Hospital

REFERRING VET

Dr. Stevenson

INVOICE

41618

ULTRASONOGRAPHIC EXAMINATION OF THE ABDOMEN**Urinary System**

The urinary bladder is moderately distended with anechoic contents. No masses, inflammatory changes, echogenic sediment or cystoliths are observed. The urinary bladder, trigone and visible pelvic urethra are normal in thickness with a smooth mucosal surface.

The right kidney is normal in size (7.06 cm), shape and echogenicity. It has smooth peripheral margination. There is a normal 1:3 cortex to medulla ratio with appropriate corticomedullary distinction. There is no evidence of pyelectasia, mineral or infarcts observed.

The left kidney is normal in size (8.02 cm), shape and echogenicity. It has smooth peripheral margination. There is a normal 1:3 cortex to medulla ratio with appropriate corticomedullary distinction. There is no evidence of pyelectasia, mineral or infarcts observed.

Adrenal Glands

Adrenal glands are plump/swollen in size. Normal shape and contour are maintained without evidence of capsular invasion. Corticomedullary structure is unremarkable. Visible surrounding vasculature appears normal. The right adrenal gland measures 3.4 cm long x 1.0 cm at the cranial pole and 1.0 cm at the caudal pole. The left adrenal gland measures 3.5 cm long x 1.0 cm at the cranial pole and 0.97 cm at the caudal pole. A hyperechoic nodule is noted in the cranial pole of the right adrenal gland, and two hyperechoic nodules are noted in the cranial pole of the left adrenal gland. The nodules do not disrupt normal shape and/or architecture.

Spleen

Spleen is generally normal in size and shape with a smooth capsular contour. Parenchyma is diffusely nodular in appearance characterized by small discrete hypoechoic nodules. Splenic vasculature appears normal.

Liver

Liver is subjectively enlarged with mildly irregular margins. Parenchyma is heterogenous characterized by multiple poorly defined hypoechoic nodules within otherwise hyperechoic liver parenchyma. Visible vasculature and biliary tree appear normal without distension or congestion.

The gallbladder is non-distended in size. The wall is smooth without visible thickening. Luminal contents are primarily anechoic. There is no evidence of cystic or common bile duct dilation.

Gastrointestinal

The visible stomach wall is normal in thickness and layering. The lumen of the stomach is mildly distended with echogenic non-shadowing luminal contents and gas consistent with normal ingesta. There is no evidence of obstruction, foreign material or infiltrative disease. Pyloric outflow tract appears patent.

The visible small intestines are normal in wall thickness and layering (canine duodenum < 0.5 cm and feline duodenum < 0.4 cm; other < 0.3 cm). Small intestinal motility appears adequate (1-3 contractions per min). The lumen of the small intestine is empty with no evidence of obstruction, foreign material or infiltrative disease.

The visible colon is normal in wall thickness (< 0.2 cm) and layering. Contents are consistent with normal formed feces and gas.

Pancreas

The observed pancreas appears appropriately isoechoic to surrounding omental fat. The capsule is mildly irregular in shape. Parenchyma is mildly heterogenous and coarse. There is no visible pancreatic duct dilation. There is no evidence of active peripancreatic inflammation.

Free Abdomen

There is no evidence of free peritoneal effusion noted in these images.

Sublumbar lymphadenopathy is noted.

PRIMARY FINDINGS

- **Bilateral adrenomegaly** – consistent with adrenal hyperplasia secondary to pituitary dependent hyperadrenocorticism vs stress or normal variant. Interpret in combination with clinical signs of hyperadrenocorticism.
- **Hyperechoic nodules present in both adrenal gland** – Top differential is adrenal hyperplasia secondary to pituitary dependent disease, or possibly bilateral primary adrenal cortical adenomas. Other differentials include myelolipomas. Adenocarcinoma, pheochromocytoma, metastatic disease, etc. can't be ruled out but is considered much less likely.
- **Heterogenous Liver** – These changes are most consistent with benign processes such as nodular hyperplasia, steroid (vacuolar) hepatopathy, extramedullary hematopoiesis or possibly chronic inflammatory disease and less commonly infiltrative round cell or metastatic neoplasia.
- **Sublumbar lymphadenopathy** – Rule outs include both reactive lymphadenopathy as well as infiltrative neoplasia and cannot be differentiated without tissue sampling.

SECONDARY FINDINGS

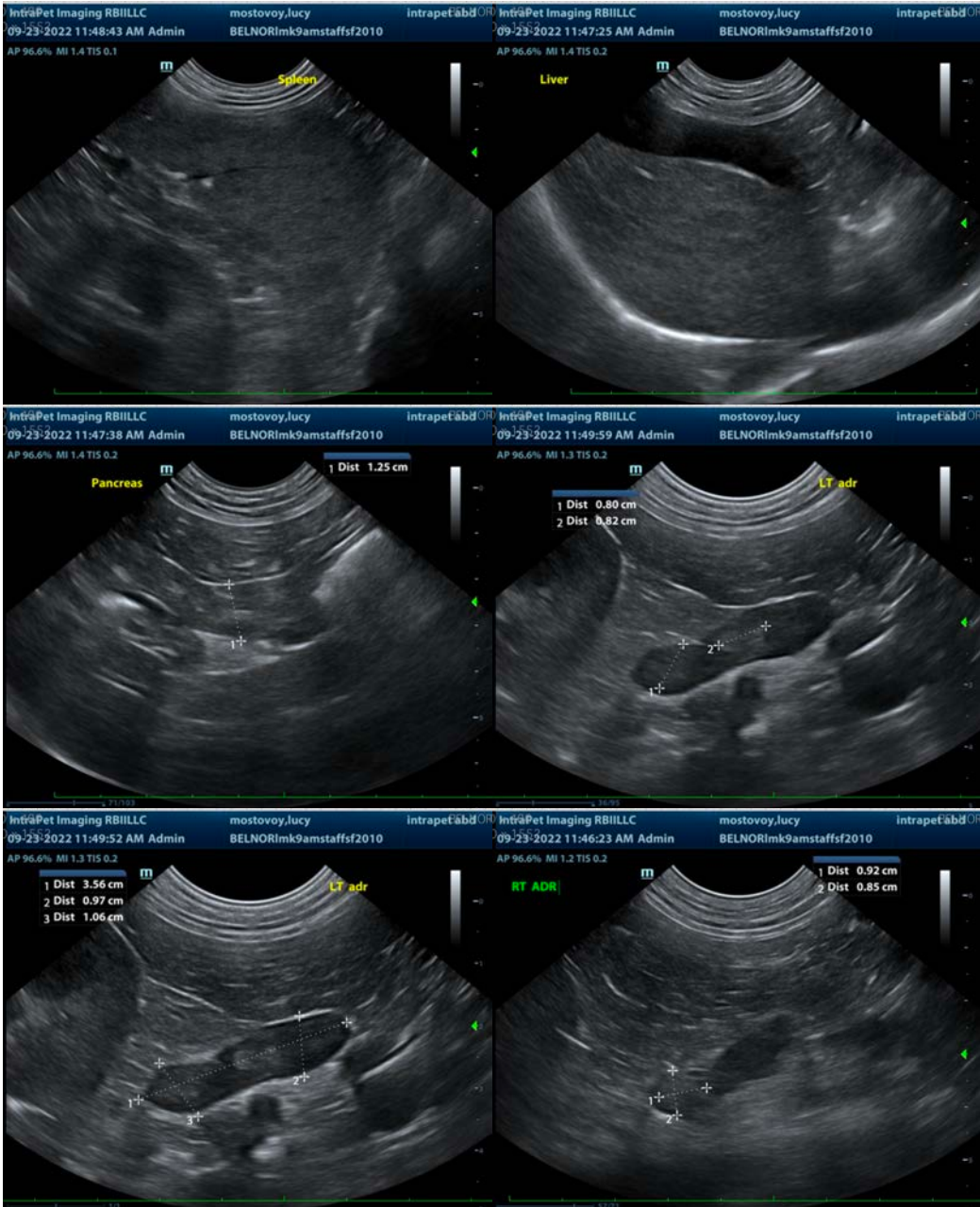
- **Splenic micronodular hyperplasia pattern** – This nodular change is often associated with benign aging nodular hyperplasia. Infiltrative neoplasia, however, including both early hemangiosarcoma as well as round cell neoplasia cannot be ruled out.
- **Pancreatic age-related remodeling** – Mild irregularities are consistent with benign age-related change. Low-grade smoldering chronic pancreatitis cannot be ruled out and should be suspected in the face of appropriate clinical signs.

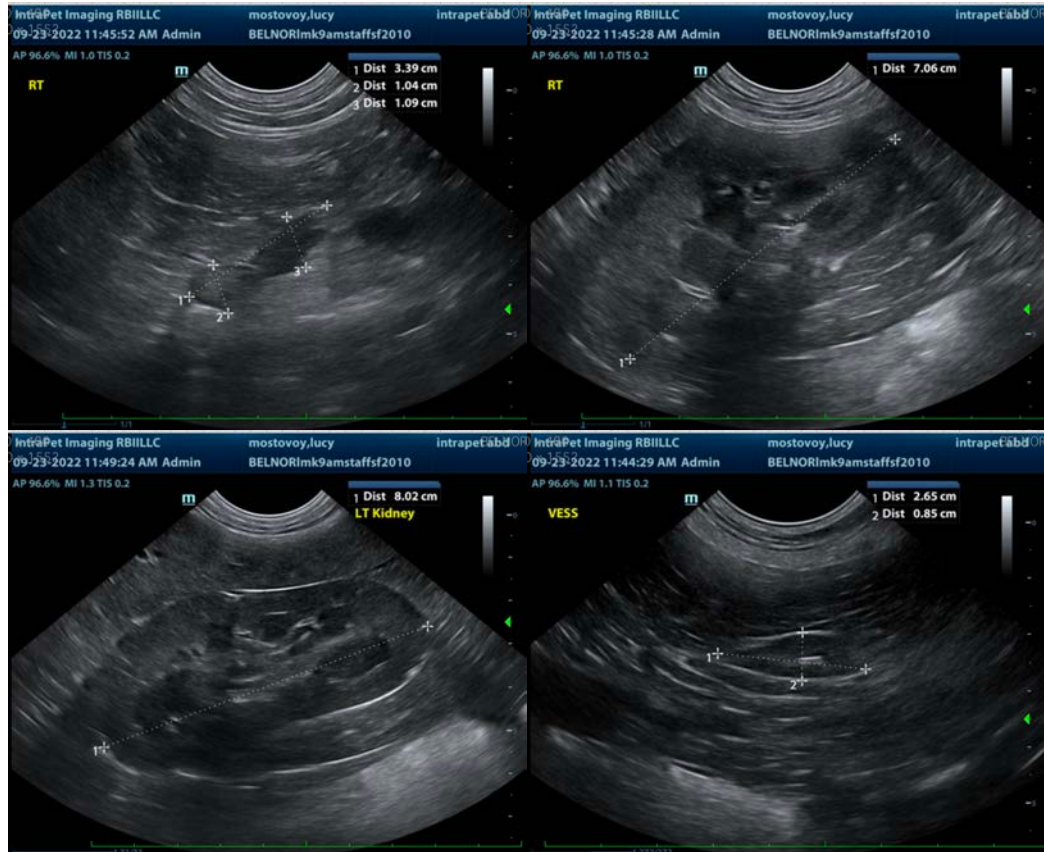
INTERPRETATION OF THE FINDINGS & FURTHER RECOMMENDATIONS

The described adrenal gland and liver changes are suggestive of hyperadrenocorticism. If clinical signs of hyperadrenocorticism, such as polyuria, polydipsia, polyphagia, panting, hair loss, hypertension, etc. are present, testing for hyperadrenocorticism with a LDDS test is warranted. If clinical signs are not present, monitoring is recommended with testing pursued when/if clinical signs develop. If not recently evaluated,

blood pressure is recommended. If not recently evaluated, a urinalysis and, if indicated based on urinalysis results, urine culture are also recommended. If protein is present in an otherwise quiet sediment, protein quantification with a urine protein to creatinine ratio is recommended.

Given the sublumbar lymphadenopathy and reported diarrhea, a thorough rectal/perianal exam is recommended to rule out anal gland tumors, etc. and empirical deworming with a 5-day course of Panacur is recommended.





The information and recommendations provided are based on the images presented by the referring veterinarian/sonographer. No evaluation can be communicated regarding pathology that was not visible in the image/video clips provided.

Thank you for this referral. If the clinical or image interpretation does not parallel your findings or if I can be of any further assistance please contact me.

Beth Johnson, DVM, DACVIM
Beth.Johnson@sonopath.com