IMAGING PERFORMED BY

IntraPet.com

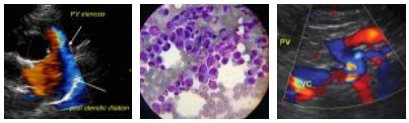

SonoPath

Clinical Sonography & Telecytology

EDUCATIONAL TELECONSULTATION SERVICES™

1-800-838-4268 info@sonopath.com SonoPath.com

DATE
9/23/22

PATIENT
Gunner Boyce

SPECIES
Canine

BREED
Chesapeake Bay Retriever

SEX
Neutered Male

AGE
1/8/11

WEIGHT
88 Pounds

INTERPRETED BY
Beth Johnson, DVM DACVIM

HOSPITAL NAME
Honeygo AH

REFERRING VET
Dr. Wright

INVOICE
17421

PRESENTING CLINICAL SIGNS

History: Intermittent diarrhea, vomiting. Patient lethargic and depressed at the time of the ultrasound.

Current Medications: Metronidazole 500mg BID during flare ups- will consider using low dose for maintenance.
Date of Previous IntraPet Ultrasound: 6/21/22. See attached.
Sedation: Not required to complete full diagnostic ultrasound.
Stat Report: Recommended and declined.
Imaging Performed By: Stephanie Warga RDCS, RVT.

ULTRASONOGRAPHIC EXAMINATION OF THE ABDOMEN

Urinary System

Urinary bladder is adequately distended with anechoic contents. No masses, inflammatory changes, echogenic sediment or cystoliths are observed. The urinary bladder, trigone and visible pelvic urethra are normal in thickness with a smooth mucosal surface.

The area of the prostate is examined without evident pathology.

Left kidney is normal is size (7.74 cm), shape and echogenicity. It has smooth peripheral margination. There is a normal 1:3 cortex to medulla ratio with appropriate corticomedullary distinction. There is no evidence of pyelectasia, mineral or infarcts observed.

Right kidney is normal is size (6.82 cm), shape and echogenicity. It has smooth peripheral margination. There is a normal 1:3 cortex to medulla ratio with appropriate corticomedullary distinction. There is no evidence of pyelectasia, mineral or infarcts observed.

Adrenal Glands

Left adrenal gland is normal in size (2.6 cm long x 0.66 cm at cranial pole and 0.76 cm at caudal pole), shape and overall architecture, echogenicity and echotexture. Visible surrounding vasculature appears normal.

Right adrenal gland is normal in size (2.8 cm x 0.92 cm at cranial pole and 0.98 cm at caudal pole), shape and overall architecture, echogenicity and echotexture. Visible surrounding vasculature appears normal.

Spleen

Spleen is subjectively normal in size with a normal smooth capsular contour. Parenchyma is appropriately finely textured and homogenous with normal echogenicity relative to surrounding tissue (hyperechoic to liver). No focal nodules or masses are observed. Splenic vasculature appears normal.

Liver

Liver is subjectively normal in size with normal smooth curvilinear peripheral contour. Parenchyma is appropriately hypoechoic to the spleen in echogenicity and appropriately mildly coarse and homogenous in echotexture. No focal lesions are observed. Visible vasculature and biliary tree appear normal without distension or congestion.

Gallbladder is moderately distended with anechoic bile as well as suspended and gravity dependent echogenic debris. The wall is smooth without visible thickening. There is no evidence of cystic or CBD dilation. There is no evidence of effusion or inflammation.

Gastrointestinal

The visible stomach wall is normal in thickness and layering. The lumen of the stomach is markedly distended with echogenic fluid.

The visible small intestines are normal in layering and thickness with several loops of markedly distended with echogenic fluid and a focal bowel loop with an echogenic interface and distal progressively shadowing material. Nondilated small bowel is also present, suggestive of a typical obstructive pattern.

The colon is moderately distended with echogenic fluid.

Pancreas

The observed pancreas appears appropriately isoechoic to surrounding omental fat. Visible capsule is smooth and normal in contour. Visible pancreatic parenchyma is homogenous and unremarkable. There is no visible pancreatic duct dilation. There is no evidence of active peripancreatic inflammation.

Free Abdomen

There is a scant amount of anechoic free fluid throughout the abdomen. No lymphadenopathy is visible.

ULTRASONOGRAPHIC FINDINGS

Primary Findings

- The small bowel dilation and progressively shadowing material, combined with some nondilated small bowel is very concerning for at least a partial, if not total, obstruction. Given the appearance of the shadow, a hairball or granular debris, such as dirt or sand versus potentially soft fluid absorbing material are considered most likely. Severe gastroenteritis cannot be definitively ruled out but is considered less likely given the combination of markedly dilated bowel and nondilated bowel throughout the abdomen.

Secondary Findings

- Gallbladder debris - Cholecystic debris is of unknown clinical significance. It can be seen with biliary stasis from fasting or illness. Cholecystic debris is not necessarily related to hepatobiliary disease. Echogenic bile is most commonly an incidental finding in dogs and should be interpreted in combination with clinical signs such as nausea, inappetence, cranial abdominal discomfort and/or laboratory changes such as increased ALP and/or increased Tbili.

INTERPRETATION OF THE FINDINGS & FURTHER RECOMMENDATIONS

Given the chronicity of this patients clinical signs and the progressive dilation of the small bowel, combined with the shadowing material believed to be within the small bowel, an exploratory laparotomy for suspected foreign body removal +/- gastrointestinal biopsies is recommended. If further diagnostics are warranted prior to surgery, abdominal radiographs could be evaluated, including potentially a barium study. If continued medical management is elected, versus surgery and long-term antibiotics are necessary to control the diarrhea, a transition from metronidazole to Tylosin is recommended and for further assessment of gastrointestinal health, a gastrointestinal malabsorption panel (including cobalamin, folate, TLI and PLI) to Texas A&M GI Laboratory is recommended for further evaluation of GI and pancreatic function. A conservative approach, however, is considered to carry risk of possible bowel perforation in this patient, given the chronicity and progressive bowel dilation.

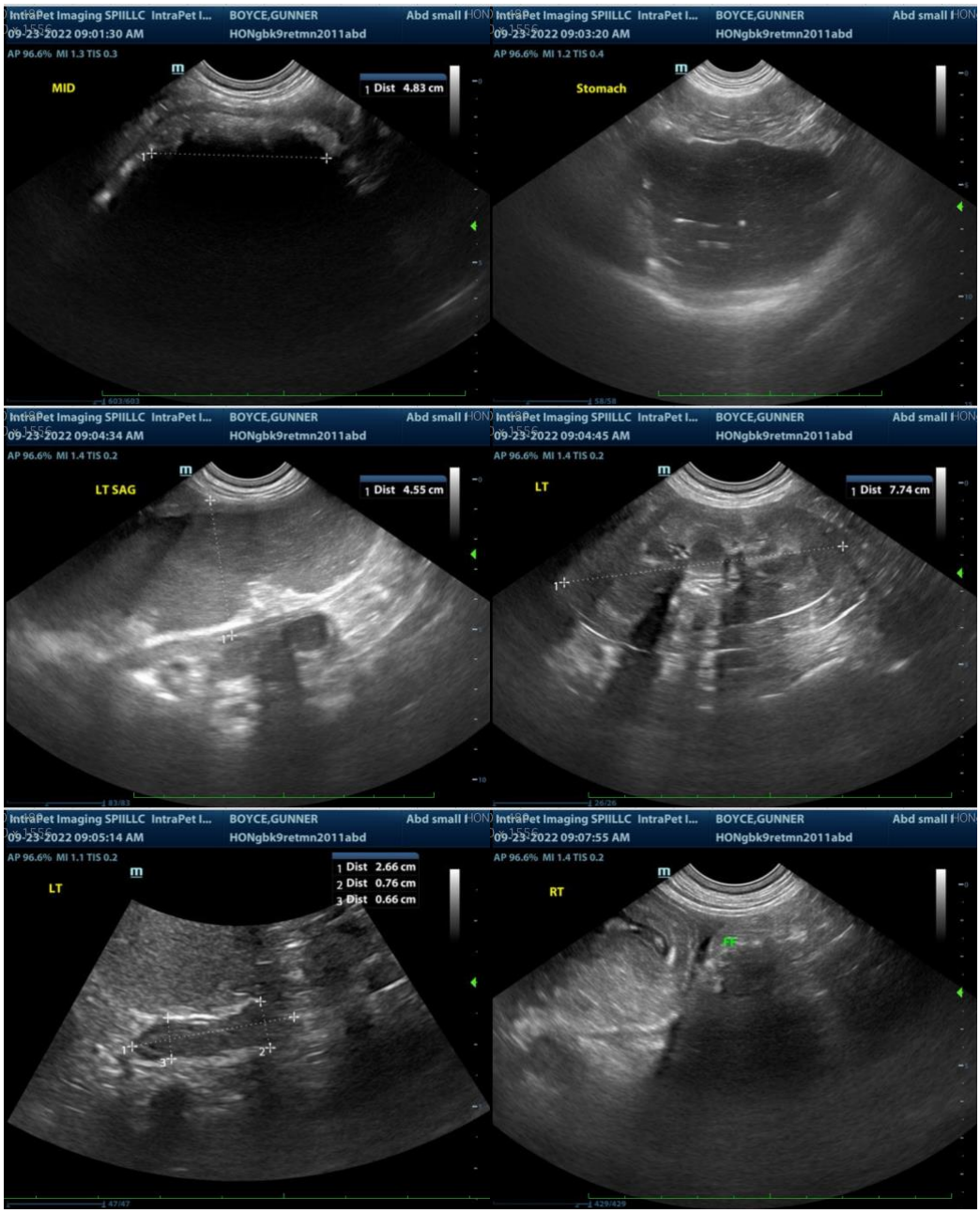
IntraPet Imaging SPIILLC IntraPet I... BOYCE,GUNNER Abd small
09-23-2022 09:01:30 AM HONgbk9retmn2011abd
AP 96.6% MI 1.3 TIS 0.3
MID
1 Dist 4.83 cm
IntraPet Imaging SPIILLC IntraPet I... BOYCE,GUNNER Abd small
09-23-2022 09:03:20 AM HONgbk9retmn2011abd
AP 96.6% MI 1.2 TIS 0.4
Stomach
IntraPet Imaging SPIILLC IntraPet I... BOYCE,GUNNER Abd small
09-23-2022 09:04:34 AM HONgbk9retmn2011abd
AP 96.6% MI 1.4 TIS 0.2
LT SAG
1 Dist 4.55 cm
IntraPet Imaging SPIILLC IntraPet I... BOYCE,GUNNER Abd small
09-23-2022 09:04:45 AM HONgbk9retmn2011abd
AP 96.6% MI 1.4 TIS 0.2
LT
1 Dist 7.74 cm
IntraPet Imaging SPIILLC IntraPet I... BOYCE,GUNNER Abd small
09-23-2022 09:05:14 AM HONgbk9retmn2011abd
AP 96.6% MI 1.1 TIS 0.2
LT
1 Dist 2.66 cm
2 Dist 0.76 cm
3 Dist 0.66 cm
IntraPet Imaging SPIILLC IntraPet I... BOYCE,GUNNER Abd small
09-23-2022 09:07:55 AM HONgbk9retmn2011abd
AP 96.6% MI 1.4 TIS 0.2
RT

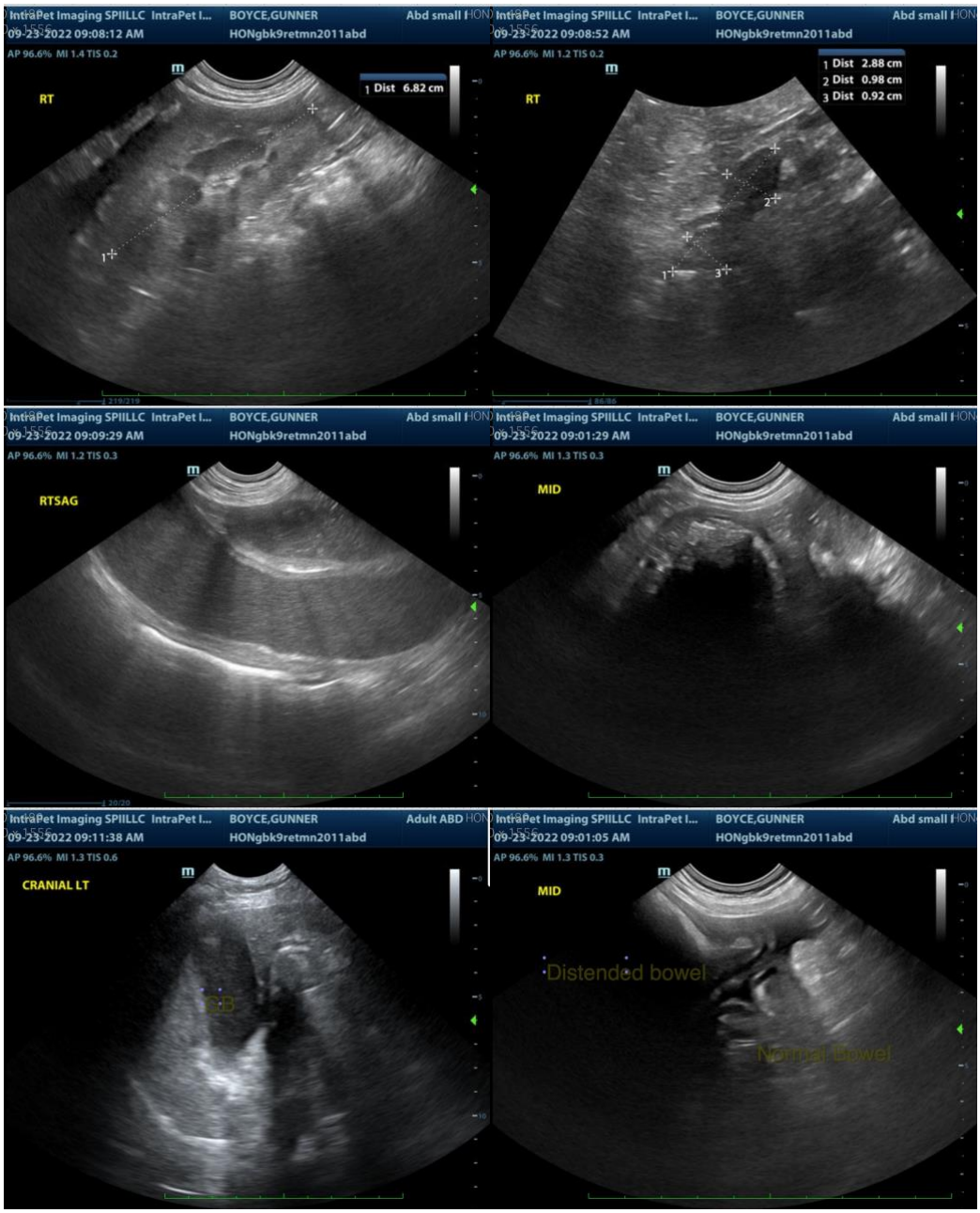

The information and recommendations provided are based on the images presented by the referring veterinarian. No evaluation can be communicated regarding pathology that was not visible in the image/video clips provided.

Thank you for this referral. If the clinical or image interpretation does not parallel your findings or if I can be of any further assistance please contact me.

Beth Johnson, DVM DACVIM

Beth.Johnson@SonoPath.com