



**DATE PRESENTING CLINICAL SIGNS**

9/23/22 Unable to jump, lethargic, fever of 104. Concern for Cushing's vs other.

**PATIENT** Current Medications: None listed.

Barney Dyba Date of Previous IntraPet Ultrasound: No previous.  
Sedation: Not required to complete full diagnostic ultrasound.  
Stat Report: Not requested.

**SPECIES ULTRASONOGRAPHIC EXAMINATION OF THE ABDOMEN**

Canine

**Urinary System**

**BREED**

The urinary bladder is moderately distended with anechoic contents. No masses, inflammatory changes, echogenic sediment or cystoliths are observed. The urinary bladder, trigone and visible pelvic urethra are normal in thickness with a smooth mucosal surface.

Mix

**SEX**

Prostate is normal in size, echotexture and echogenicity for a neutered male.

Neutered Male

The right kidney is normal in size (6.55 cm), shape and echogenicity. It has smooth peripheral margination. There is a normal 1:3 cortex to medulla ratio with appropriate corticomedullary distinction. There is no evidence of pyelectasia, mineral or infarcts observed.

**AGE**

9/24/15

The left kidney is normal in size (6.51 cm), shape and echogenicity. It has smooth peripheral margination. There is a normal 1:3 cortex to medulla ratio with appropriate corticomedullary distinction. There is no evidence of pyelectasia, mineral or infarcts observed.

**WEIGHT**

58.7 Pounds

**Adrenal Glands**

**INTERPRETED BY**

The right adrenal gland is normal in size (2.9 cm long x 0.57 cm at the cranial pole and 0.60 cm at the caudal pole), shape and contour. Corticomedullary structure is unremarkable. Visible surrounding vasculature appears normal.

Beth Johnson, DVM  
DACVIM

The left adrenal gland is normal in size (2.67 cm long x 0.73 cm at the cranial pole and 0.68 cm at the caudal pole), shape and contour. Corticomedullary structure is unremarkable. Visible surrounding vasculature appears normal.

**IMAGING PERFORMED BY**

Rachel Brillhart RDMS

**Spleen**

**HOSPITAL NAME**

Spleen is subjectively normal in size with a normal smooth capsular contour. Parenchyma is appropriately finely textured and homogenous with normal echogenicity relative to surrounding tissue (hyperechoic to liver). Multifocal well-demarcated hyperechoic homogenous nodules are noted. Splenic vasculature appears normal.

Homeward Bound VS

**REFERRING VET**

**Liver**

Dr. Vance

Liver is subjectively enlarged with mildly irregular margins. Parenchyma is heterogenous characterized by multiple poorly defined hypoechoic nodules within otherwise hyperechoic liver parenchyma. Visible vasculature and biliary tree appear normal without distension or congestion.

**INVOICE**

41613

Gallbladder is moderately distended with anechoic bile as well as suspended and gravity dependent echogenic debris. The wall is smooth without visible thickening. There is no evidence of cystic or CBD dilation. There is no evidence of effusion or inflammation.

### ***Gastrointestinal***

The stomach wall is normal in thickness (canine < 0.5 cm and feline < 0.4 cm) and layering. The lumen of the stomach is empty with no evidence of obstruction, foreign material or infiltrative disease. Pyloric outflow tract appears patent.

The visible small intestines are normal in wall thickness and layering. Hyperechoic mucosal fogging or speckling is noted. Small intestinal motility appears adequate (1-3 contractions per min). The lumen is empty with no evidence of obstruction or foreign material.

The visible colon is normal in wall thickness (< 0.2 cm) and layering. Contents are consistent with normal formed feces and gas.

### ***Pancreas***

The observed pancreas is prominent (enlarged) in size, hypoechoic to surrounding tissue and irregular in shape with a swollen undulating contour. Enhanced hyperechoic ill-defined surrounding fat is noted.

### ***Free Abdomen***

Hypoechoic, heterogeneous portal lymph nodes are noted as well as enhanced hyperechoic fat and mesentery around the pancreas and liver.

There is no evidence of free peritoneal effusion noted in these images.

## **PRIMARY FINDINGS**

- Acute pancreatitis
- **Heterogenous Liver** – These changes are most consistent with benign processes such as nodular hyperplasia, steroid (vacuolar) hepatopathy, extramedullary hematopoiesis or possibly chronic inflammatory disease and less commonly infiltrative round cell or metastatic neoplasia. Heterogeneous portal lymphadenopathy and enhanced fat and mesentery may indicate a concurrent non-specific hepatitis in addition to the pancreatitis.
- **Mucosal speckling** – Mucosal speckling is often present with inflammatory bowel disease (IBD). It is not specific for type or severity of disease. Mild speckling change can occur as a normal patient variant in the post-prandial state.

## **SECONDARY FINDINGS**

- **Gallbladder debris** - Cholecystic debris is of unknown clinical significance. It can be seen with biliary stasis from fasting or illness. Cholecystic debris is not necessarily related to hepatobiliary disease. Echogenic bile is most commonly an incidental finding in dogs and should be interpreted in combination with clinical signs such as nausea, inappetence, cranial abdominal discomfort and/or laboratory changes such as increased ALP and/or increased Tbili.
- **Hyperechoic splenic nodules** – most consistent with benign myelolipomas. Other differentials such as fibrosis or calcification caused by old hematomas or infarcts, chronic inflammation, granulomatous disease or metastatic disease cannot be ruled out, but are considered less likely.

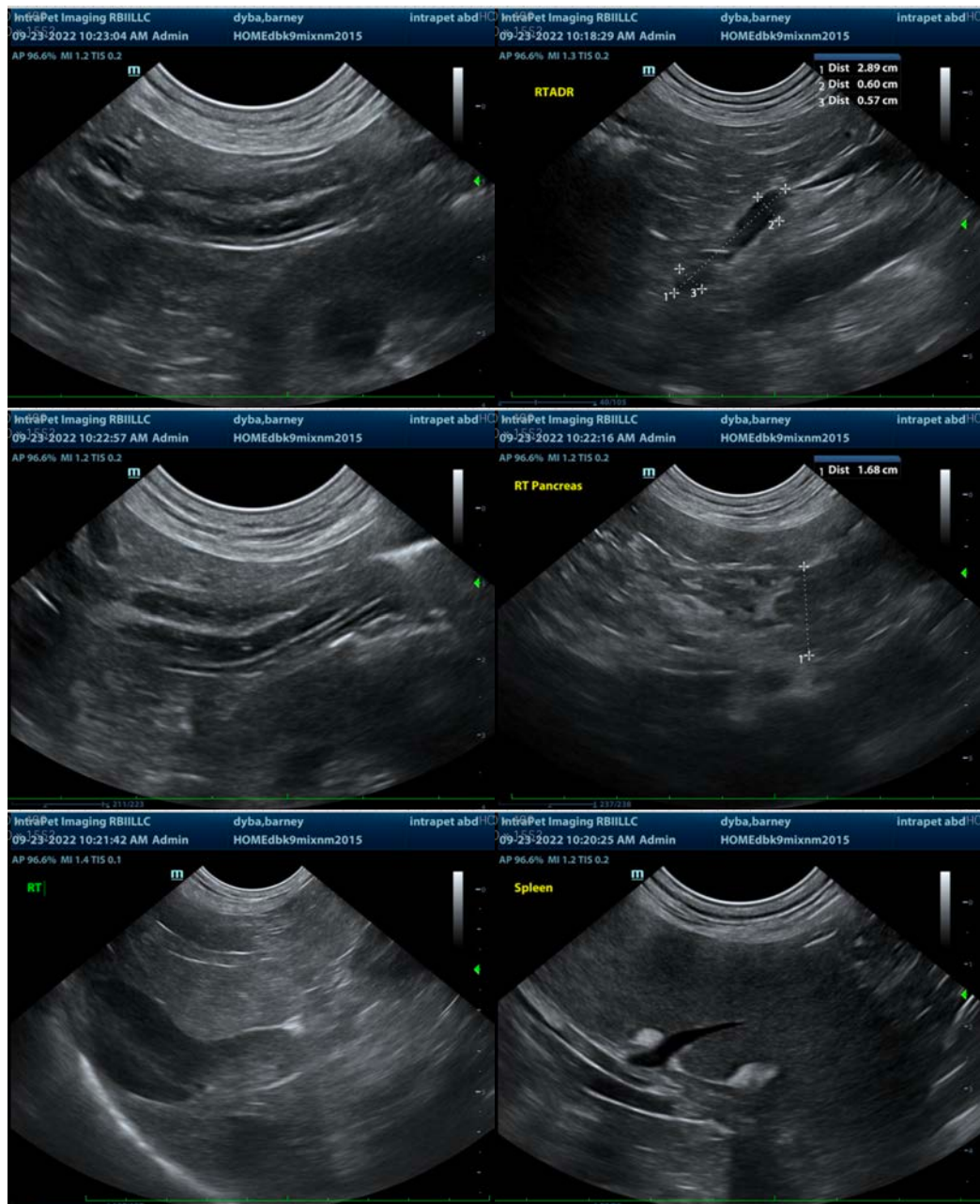
## **INTERPRETATION OF THE FINDINGS & FURTHER RECOMMENDATIONS**

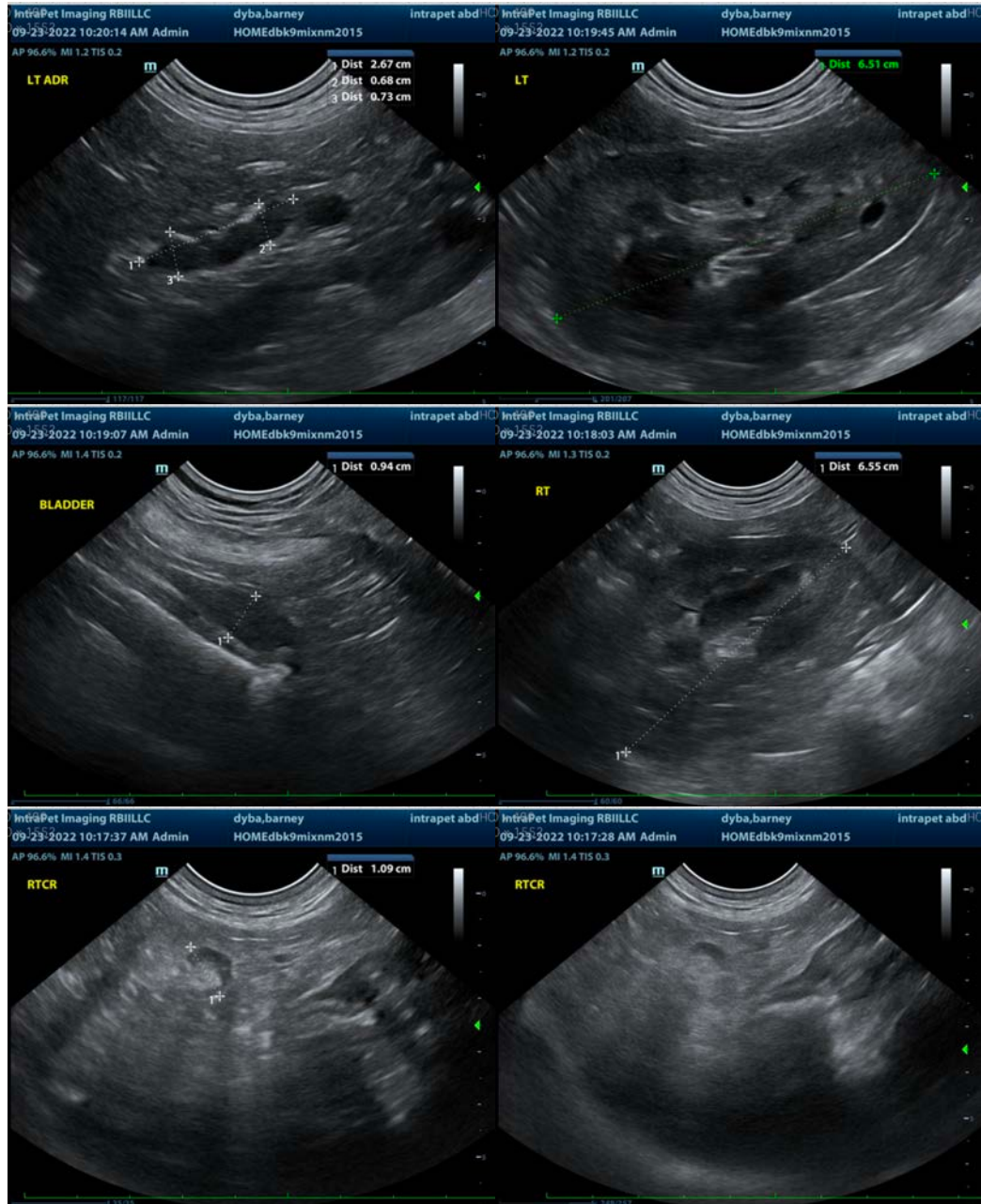
A gastrointestinal malabsorption panel (including cobalamin, folate, TLI and PLI) to Texas A&M GI Laboratory is recommended for further evaluation of GI and pancreatic function.

Testing for Leptospirosis is indicated if not recently evaluated.

A fine needle aspirate of the liver could also be considered if patient's coagulation status is appropriate, especially if liver enzyme changes support an ongoing hepatopathy/hepatitis.

In the meantime, medical management of pancreatitis with anti-emetics, gastroprotectants, appetite stimulants or nutritional support as needed, pain management, broad spectrum antibiotics, and fluid therapy is recommended. If possible, a fresh frozen plasma transfusion and hyperbaric oxygen therapy (HBOT) could be beneficial.





The information and recommendations provided are based on the images presented by the referring veterinarian/sonographer. No evaluation can be communicated regarding pathology that was not visible in the image/video clips provided.

Thank you for this referral. If the clinical or image interpretation does not parallel your findings or if I can be of any further assistance please contact me.

**Beth Johnson, DVM, DACVIM**  
Beth.Johnson@sonopath.com