SonoPath
Clinical Sonography & Telecytology

EDUCATIONAL TELECONSULTATION SERVICES™

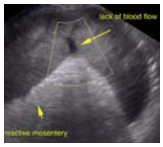
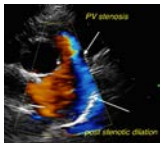
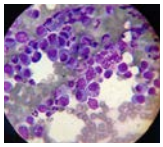
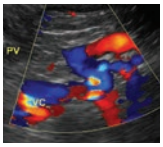

SonoPath.com™
1-800-838-4268 info@sonopath.com

PATIENT
Milo Manzano

SPECIES
Canine

BREED
Cockapoo

SEX
Neutered Male

AGE
13 Years

WEIGHT
21 Pounds

INTERPRETED BY
Beth Johnson, DVM
DACVIM

IMAGING PERFORMED BY
Kelly Vazquez

HOSPITAL NAME
Animal General
On the Hudson

REFERRING VET
Dr. Wiiliam Freedman

INVOICE
41502

DATE
9/21/22

PRESENTING CLINICAL SIGNS

Patient presents for hematuria, urine culture (-). Current med: Apoquel.
Abnormal PE/Chem/CBC/UA Results: U/A: 4-10 struvite crystals. 4-10 amorphous phosphate crystals, USG 1.052.

ULTRASONOGRAPHIC EXAMINATION OF THE ABDOMEN

Urinary System

Urinary bladder is adequately distended with primarily anechoic contents and occasional echogenic non-shadowing debris. Some of the debris is echogenic, like mineral sand/debris. Apical urinary bladder wall is diffusely thick (0.36 cm). Mucosa is hyperechoic and irregular. No masses or cystoliths are observed. The trigone and visible pelvic urethra are normal thickness with a smooth mucosal surface.

Prostate is normal in size, echotexture and echogenicity for a neutered male.

The right kidney is normal in size (4.63 cm), shape and echogenicity. It has smooth peripheral margination. There is a normal 1:3 cortex to medulla ratio with appropriate corticomedullary distinction. There is no evidence of pyelectasia or infarcts observed. Non-obstructive areas of mineralization/nephroliths are noted.

The left kidney is normal in size (4.43 cm), shape and echogenicity. It has smooth peripheral margination. There is a normal 1:3 cortex to medulla ratio with appropriate corticomedullary distinction. There is no evidence of pyelectasia or infarcts observed. Non-obstructive areas of mineralization/nephroliths are noted.

Adrenal Glands

The right adrenal gland is normal in size (1.4 cm long x 0.60 cm at the cranial pole and 0.56 cm at the caudal pole), shape and contour. Corticomedullary structure is unremarkable. Visible surrounding vasculature appears normal.

The left adrenal gland is normal in size (1.75 cm long x 0.42 cm at the cranial pole and 0.53 cm at the caudal pole), shape and contour. Corticomedullary structure is unremarkable. Visible surrounding vasculature appears normal.

Spleen

The spleen is subjectively normal in size with a normal smooth capsular contour. Parenchyma is appropriately finely textured and homogenous with normal echogenicity relative to surrounding tissue (hyperechoic to liver). No focal nodules or masses are observed. Splenic vasculature appears normal.

Liver

Liver is normal to subjectively small in size with slightly undulating or scalloped capsular contour or margins. Parenchyma is diffusely heterogenous with increased portal markings and coarse architecture. No focal nodules or masses are observed. Visible vasculature and biliary tree appear normal without distension or congestion.

Gallbladder is moderately distended with anechoic bile as well as mild suspended and gravity dependent echogenic debris. The wall is mildly thick, hyperechoic and irregular with subjectively benign polypoid changes. Infiltrative neoplasia cannot be ruled out but is considered less likely. There is no evidence of effusion or inflammation.

SonoPath
Clinical Sonography & Telecytology
EDUCATIONAL TELECONSULTATION SERVICES™

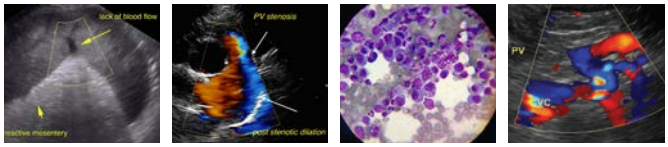

SonoPath.com™
1-800-838-4268 info@sonopath.com

PATIENT
Milo Manzano

SPECIES
Canine

BREED
Cockapoo

SEX
Neutered Male

AGE
13 Years

WEIGHT
21 Pounds

INTERPRETED BY
Beth Johnson, DVM
DACVIM

IMAGING PERFORMED BY
Kelly Vazquez

HOSPITAL NAME
Animal General
On the Hudson

REFERRING VET
Dr. Wiiliam Freedman

INVOICE
41502

DATE
9/21/22

Gastrointestinal

The stomach wall is normal in thickness (canine < 0.5 cm and feline < 0.4 cm) and layering. The lumen of the stomach is empty with no evidence of obstruction, foreign material or infiltrative disease. Pyloric outflow tract appears patent.

The visible small intestines are normal in wall thickness and layering (canine duodenum < 0.5 cm and feline duodenum < 0.4 cm; other < 0.3 cm). Small intestinal motility appears adequate (1-3 contractions per min). The lumen of the small intestine is empty with no evidence of obstruction, foreign material or infiltrative disease.

The visible colon is normal in wall thickness (< 0.2 cm) and layering. Contents are consistent with normal formed feces and gas.

Pancreas

The pancreatic parenchyma is appropriately isoechoic to surrounding tissue. Visible capsule is smooth and normal in contour. There is no visible pancreatic duct dilation. There is no evidence of active peripancreatic inflammation.

Free Abdomen

There is no evidence of free peritoneal effusion noted in these images.

There is no apparent lymphadenopathy noted in these images.

ULTRASONOGRAPHIC FINDINGS

- **Chronic Cystitis with echogenic mineral/crystal or debris -** Urinary bladder wall changes are most consistent with chronic cystitis. Infiltrative neoplasia cannot be ruled out but is considered less likely give the location and diffuse nature of the changes.
- Non-obstructive nephrolithiasis bilaterally in the kidneys
- **Chronic inflammatory hepatopathy** – This finding should be interpreted in combination with supporting laboratory changes and/or clinical signs, as this could be a resolving or aged change.
- Gallbladder polypoid hyperplasia

INTERPRETATION OF THE FINDINGS & FURTHER RECOMMENDATIONS

If not recently evaluated, a CBC/Chem panel and electrolytes is recommended for further evaluation of the liver. If there is any concern for liver disease, then a coagulation panel is warranted to rule out a coagulopathy causing the hematuria.

Otherwise, given the reported struvite crystals and cellular debris noted on ultrasound, chronic cystitis and crystalluria are likely the cause for the hematuria +/- a urinary tract infection with a falsely negative culture. If the culture was drawn within a week of patient receiving antibiotics, the culture should be rechecked after at least a week to 10 days off antibiotics. If not, an empirical course of antibiotics could be tried to see if that results in clinical improvement, as well as a urinary health stone dissolution/crystal prevention diet.

If improvement cannot be obtained empirically, and/or the answer is not received through urine testing, ultimately cystoscopy for tissue biopsy and tissue culture may be necessary to definitively diagnose and therefore adequately manage the cystitis/hematuria.

SonoPath

Clinical Sonography & Telecytology

EDUCATIONAL TELECONSULTATION SERVICES™

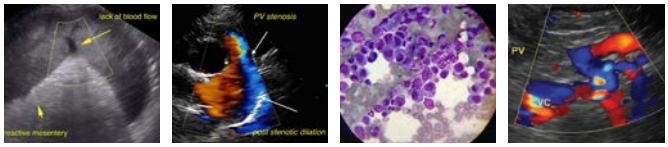

SonoPath.com™
1-800-838-4268 info@sonopath.com

PATIENT

Milo Manzano

SPECIES

Canine

BREED

Cockapoo

SEX

Neutered Male

AGE

13 Years

WEIGHT

21 Pounds

INTERPRETED BY

Beth Johnson, DVM
DACVIM

IMAGING PERFORMED BY

Kelly Vazquez

HOSPITAL NAME

Animal General
On the Hudson

REFERRING VET

Dr. Wiiliam Freedman

INVOICE

41502

DATE

9/21/22

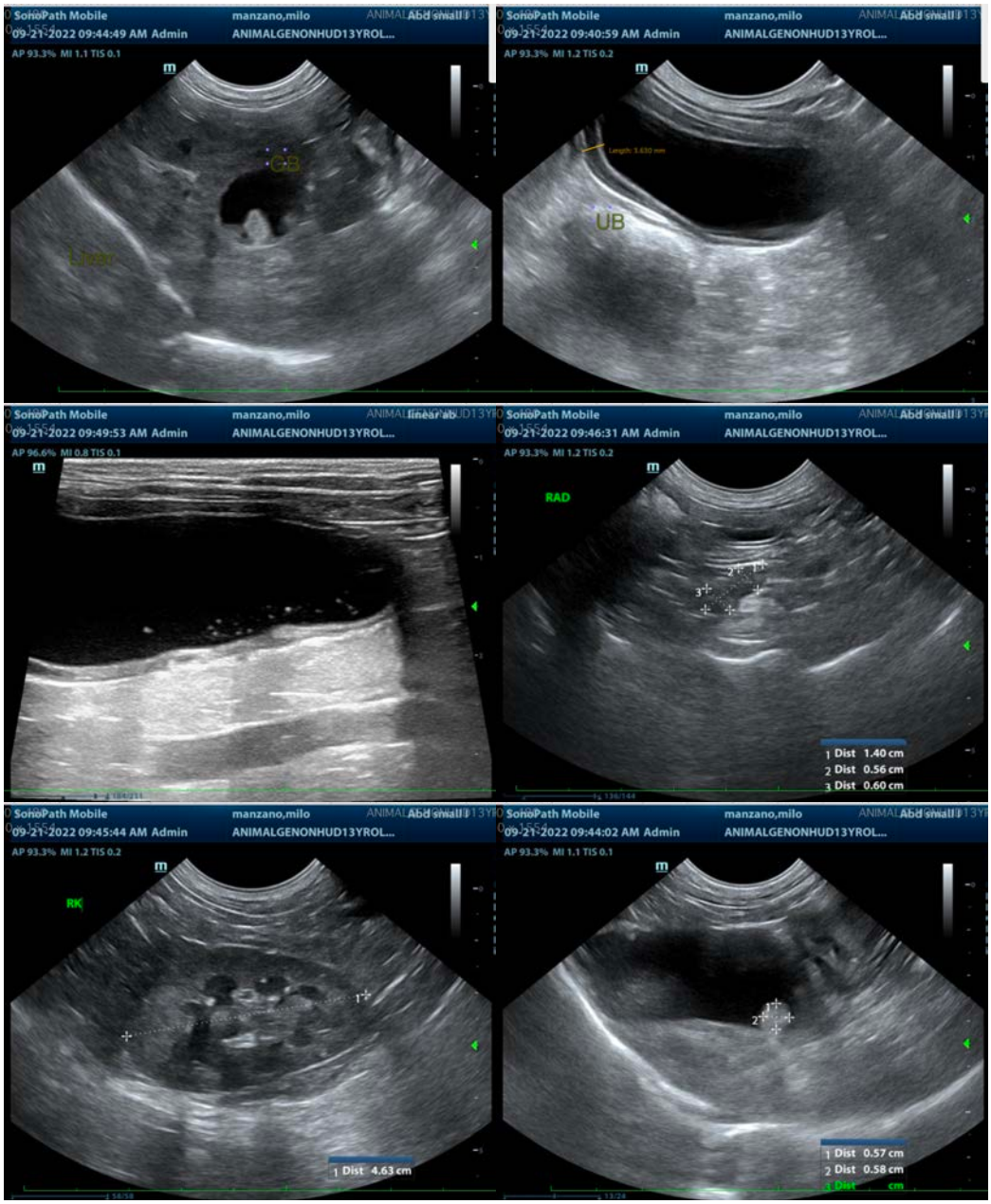

SonoPath
Clinical Sonography & Telecytology

EDUCATIONAL TELECONSULTATION SERVICES™

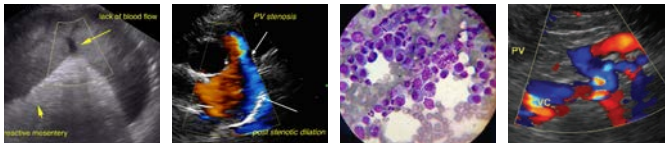

SonoPath.com™
1-800-838-4268 info@sonopath.com

PATIENT

Milo Manzano

SPECIES

Canine

BREED

Cockapoo

SEX

Neutered Male

AGE

13 Years

WEIGHT

21 Pounds

INTERPRETED BY

Beth Johnson, DVM
DACVIM

IMAGING PERFORMED BY

Kelly Vazquez

HOSPITAL NAME

Animal General
On the Hudson

REFERRING VET

Dr. Wiiliam Freedman

INVOICE

41502

DATE

9/21/22

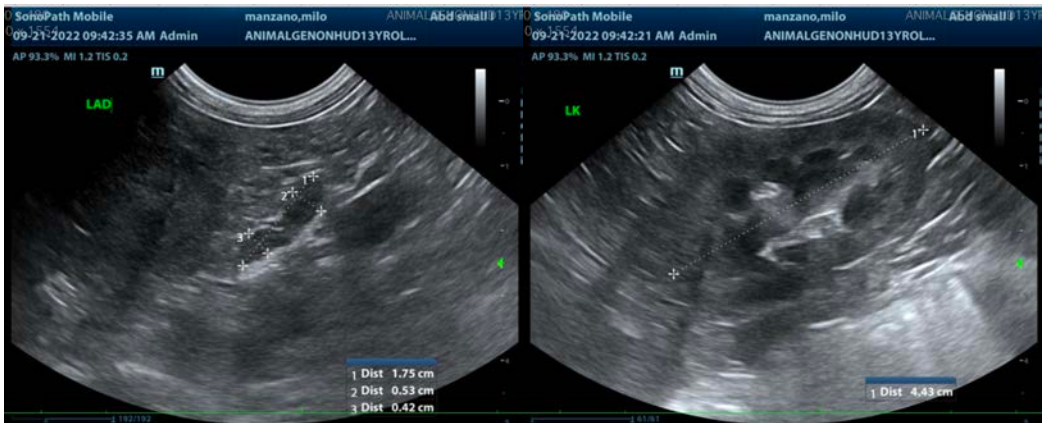

The information and recommendations provided are based on the images presented by the referring veterinarian/sonographer. No evaluation can be communicated regarding pathology that was not visible in the image/video clips provided.

Thank you for this referral. If the clinical or image interpretation does not parallel your findings or if I can be of any further assistance please contact me.

Beth Johnson, DVM, DACVIM
Beth.Johnson@sonopath.com