



PATIENT

Chase Beltran

SPECIES

Canine

BREED

Labrador Retriever

SEX

Neutered Male

AGE

11 Years

WEIGHT

88.2 Pounds

INTERPRETED BY

Beth Johnson, DVM
DACVIM

IMAGING PERFORMED BY

Kelly Vazquez

HOSPITAL NAME

Animal General
on the Hudson

REFERRING VET

Dr. Daniel Tierney

INVOICE

41496

DATE

9/21/22

PRESENTING CLINICAL SIGNS

Older dog, owner wants area checked, in March ALT elevated but now normal, renal values have been stable at high normal.

Abnormal PE/Chem/CBC/UA Results: CBC: WNL. Chem: ALT 56, ALP 35, BUN 19, creat. 1.5.

ULTRASONOGRAPHIC EXAMINATION OF THE ABDOMEN

Urinary System

The urinary bladder is moderately distended with anechoic contents. No masses, inflammatory changes, echogenic sediment or cystoliths are observed. The urinary bladder, trigone and visible pelvic urethra are normal in thickness with a smooth mucosal surface.

Prostate is normal in size, echotexture and echogenicity for a neutered male.

The right kidney is normal in size (6.32 cm), shape and echogenicity. It has smooth peripheral margination. There is a normal 1:3 cortex to medulla ratio with appropriate corticomedullary distinction. There is no evidence of pyelectasia, mineral or infarcts observed.

The left kidney is normal in size (5.32 cm), shape and echogenicity. It has smooth peripheral margination. There is a normal 1:3 cortex to medulla ratio with appropriate corticomedullary distinction. There is no evidence of pyelectasia, mineral or infarcts observed.

Adrenal Glands

Adrenal glands are plump/swollen in size. Normal shape and contour are maintained without evidence of capsular invasion. Corticomedullary structure is unremarkable. Visible surrounding vasculature appears normal. The left adrenal gland measures 2.27 cm long x 1.0 cm at the cranial pole and 0.64 cm at the caudal pole. The right adrenal gland measures 2.89 cm x 1.89 cm at the cranial pole and 1.0 cm at the caudal pole. A hyperechoic nodule is noted in the cranial pole of the right adrenal gland. Nodule does not disrupt normal shape and/or architecture.

Spleen

The spleen is subjectively normal in size with a normal smooth capsular contour. Parenchyma is appropriately finely textured and homogenous with normal echogenicity relative to surrounding tissue (hyperechoic to liver). No focal nodules or masses are observed. Splenic vasculature appears normal. I do not see visible evidence of a thrombus at this time.

Liver

The liver is subjectively normal in size with normal smooth curvilinear peripheral contour. Parenchyma is appropriately hypoechoic to the spleen in echogenicity and appropriately mildly coarse and homogenous in echotexture. No focal lesions are observed. Visible vasculature and biliary tree appear normal without distension or congestion.

The gallbladder is non-distended in size. The wall is smooth without visible thickening. Luminal contents are primarily anechoic. There is no evidence of cystic or common bile duct dilation.

Gastrointestinal

The stomach wall is normal in thickness (canine < 0.5 cm and feline < 0.4 cm) and layering. The lumen of the stomach is empty with no evidence of obstruction, foreign material or infiltrative disease. Pyloric outflow tract appears patent.



PATIENT

Chase Beltran

The visible small intestines are normal in wall thickness and layering (canine duodenum < 0.5 cm and feline duodenum < 0.4 cm; other < 0.3 cm). Small intestinal motility appears adequate (1-3 contractions per min). The lumen of the small intestine is empty with no evidence of obstruction, foreign material or infiltrative disease.

SPECIES

Canine

The visible colon is normal in wall thickness (< 0.2 cm) and layering. Contents are consistent with normal formed feces and gas.

Pancreas

BREED

Labrador Retriever

The pancreatic parenchyma is appropriately isoechoic to surrounding tissue. Visible capsule is smooth and normal in contour. There is no visible pancreatic duct dilation. There is no evidence of active peripancreatic inflammation.

SEX

Neutered Male

Free Abdomen

There is no evidence of free peritoneal effusion noted in these images.

There is no apparent lymphadenopathy noted in these images.

AGE

11 Years

ULTRASONOGRAPHIC FINDINGS

WEIGHT

88.2 Pounds

- **Bilateral adrenomegaly** – consistent with adrenal hyperplasia secondary to pituitary dependent hyperadrenocorticism vs stress or normal variant. Interpret in combination with clinical signs of hyperadrenocorticism.
- **Hyperechoic adrenal nodule (cranial pole right adrenal gland)** – Differentials include primary adrenal cortical adenoma or adenocarcinoma, pheochromocytoma, myelolipoma, adrenal hyperplasia secondary to pituitary disease or metastatic disease. Ultrasound alone cannot differentiate between functional and non-functional nodules and/or between benign and malignant disease. Small nodules without other evidence of abdominal disease (to suggest metastatic disease) and/or clinical signs (to suggest adrenal disease) are most often incidental and should be monitored.
- Otherwise, unremarkable/normal abdomen

INTERPRETED BY

Beth Johnson, DVM
DACVIM

IMAGING PERFORMED BY

Kelly Vazquez

HOSPITAL NAME

Animal General
on the Hudson

REFERRING VET

Dr. Daniel Tierney

INTERPRETATION OF THE FINDINGS & FURTHER RECOMMENDATIONS

The described adrenal gland changes could suggest hyperadrenocorticism. If clinical signs of hyperadrenocorticism, such as polyuria, polydipsia, polyphagia, panting, hair loss, hypertension, etc. are present, testing for hyperadrenocorticism with a LDDS test is warranted. If clinical signs are not present, monitoring is recommended with testing pursued when/if clinical signs develop. If not recently evaluated, blood pressure is recommended. If not recently evaluated, a urinalysis and, if indicated based on urinalysis results, urine culture are also recommended. If protein is present in an otherwise quiet sediment, protein quantification with a urine protein to creatinine ratio is recommended.

INVOICE

41496

DATE

9/21/22



PATIENT

Chase Beltran

SPECIES

Canine

BREED

Labrador Retriever

SEX

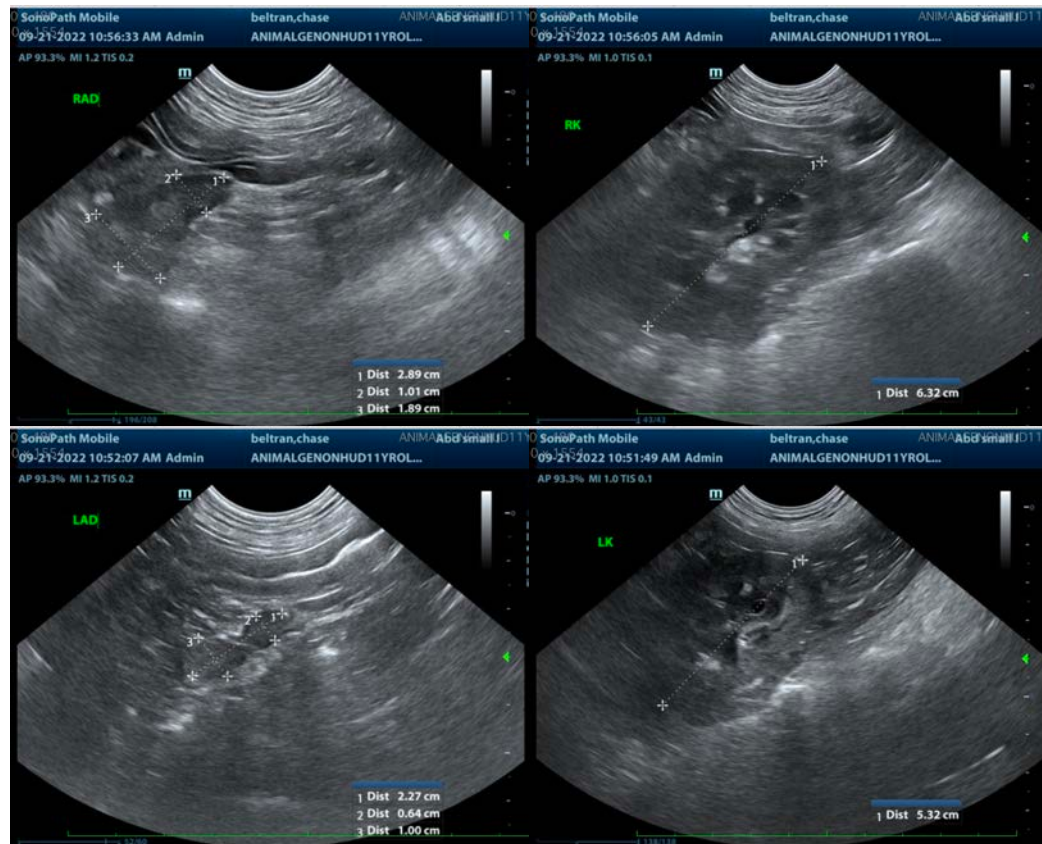
Neutered Male

AGE

11 Years

WEIGHT

88.2 Pounds



INTERPRETED BY

Beth Johnson, DVM
DACVIM

IMAGING PERFORMED BY

Kelly Vazquez

HOSPITAL NAME

Animal General
on the Hudson

REFERRING VET

Dr. Daniel Tierney

INVOICE

41496

DATE

9/21/22

The information and recommendations provided are based on the images presented by the referring veterinarian/sonographer. No evaluation can be communicated regarding pathology that was not visible in the image/video clips provided.

Thank you for this referral. If the clinical or image interpretation does not parallel your findings or if I can be of any further assistance please contact me.

Beth Johnson, DVM, DACVIM
Beth.Johnson@sonopath.com