

**DATE PRESENTING CLINICAL SIGNS**

9/21/22

One year history of multisystemic disease that was eventually diagnosed as systemic lupus erythematosus. Controlled on prednisone, but 8/22 had an acute fever, joint swelling, lethargic episode again and was immediately put back on immune suppressive dose of prednisone.

**PATIENT**

Brody Christensen

1 week after onset of episode, had diffuse bruising, liver values were off the chart high, suspected coagulopathy from acute liver insult/failure. Cause was never found. Then had severe leukocytosis (60K), mostly neutrophilia with left shift, and was put on clavamox, baytril, metronidazole early in episode. Cause for leukocytosis and acute liver insult never found. Would like abdominal ultrasound to look for source of infection and to evaluate liver.

**SPECIES**

Canine

**BREED**

Mastiff X

**SEX**

Neutered Male

Current Medications: Prednisone 40 mg PO BID, Clavamox 875 mg BID, Metronidazole 750 mg BID, Enrofloxacin 612 mg SID, Welactin, Vitamin E, Denamarin advanced, Omeprazole 40 mg BID

Lab Results: See attached.

Date of Previous IntraPet Ultrasound: No previous.

Sedation: Not required to complete full diagnostic ultrasound.

Stat Report: Not requested.

**ULTRASONOGRAPHIC EXAMINATION OF THE ABDOMEN****AGE**

10/13/17

**WEIGHT**

150 Pounds

**Urinary System**

Urinary bladder is adequately distended. It has a normal uniform wall thickness. Contents include primarily anechoic fluid with occasional echogenic non-shadowing debris, most consistent with exfoliated cells, mucous and/or small blood clots. Some mineral debris/sand is settled against the dependent wall. Both sterile inflammation as well as urinary tract infection can also present with echogenic debris. No masses or cystoliths are observed. The trigone and visible pelvic urethra are normal in thickness with a smooth mucosal surface.

**INTERPRETED BY**Beth Johnson, DVM  
DACVIM

The area of the prostate is examined without evident pathology.

**IMAGING PERFORMED BY**

Rachel Brillhart RDMS

The right kidney is normal in size (10.35 cm), shape and echogenicity. It has smooth peripheral margination. There is a normal 1:3 cortex to medulla ratio with appropriate corticomedullary distinction. There is no evidence of pyelectasia or infarcts observed. Non-obstructive areas of mineralization/nephroliths are noted.

The left kidney is normal in size (9.91 cm), shape and echogenicity. It has smooth peripheral margination. There is a normal 1:3 cortex to medulla ratio with appropriate corticomedullary distinction. There is no evidence of pyelectasia or infarcts observed. Non-obstructive areas of mineralization/nephroliths are noted.

**HOSPITAL NAME**

Airpark AH

**Adrenal Glands**

Adrenal glands are small (flattened contour). Corticomedullary structure is unremarkable. Visible surrounding vasculature appears normal. The left adrenal gland measures 3.39 cm long x 0.37 cm at the cranial pole and 0.45 cm at the caudal pole. The right adrenal gland measures 3.39 cm long x 0.45 cm at the cranial pole and 0.39 cm at the caudal pole.

**REFERRING VET**

Dr. Owens

**Spleen**

Spleen is subjectively normal in size with a normal smooth capsular contour. Parenchyma is appropriately finely textured and homogenous with normal echogenicity relative to surrounding tissue (hyperechoic to liver). No focal nodules or masses are observed. Multifocal mineral foci are noted. Splenic vasculature appears normal.

**INVOICE**

41508

**Liver**

Liver is subjectively enlarged (swollen contour) without disruption of architecture. It has a normal homogenous echotexture. Parenchyma is diffusely markedly hyperechoic characterized by less prominent

than normal portal vein walls and increased echogenicity relative to the spleen and falciform fat. No focal lesions are observed. Visible vasculature and biliary tree appear normal without distension or congestion.

Gallbladder is moderately distended with anechoic bile as well as suspended and gravity dependent echogenic debris. The wall is smooth without visible thickening. There is no evidence of cystic or CBD dilation. There is no evidence of effusion or inflammation.

### ***Gastrointestinal***

The stomach wall is normal in thickness (canine < 0.5 cm and feline < 0.4 cm) and layering. The lumen of the stomach is empty with no evidence of obstruction, foreign material or infiltrative disease. Pyloric outflow tract appears patent.

The visible small intestines are normal in wall thickness and layering (canine duodenum < 0.5 cm and feline duodenum < 0.4 cm; other < 0.3 cm). Small intestinal motility appears adequate (1-3 contractions per min). The lumen of the small intestine is empty with no evidence of obstruction, foreign material or infiltrative disease.

The visible colon is normal in wall thickness (< 0.2 cm) and layering. Contents are consistent with normal formed feces and gas.

### ***Pancreas***

The pancreatic parenchyma is appropriately isoechoic to surrounding tissue. Visible capsule is smooth and normal in contour. There is no visible pancreatic duct dilation. There is no evidence of active peripancreatic inflammation.

### ***Free Abdomen***

There is no evidence of free peritoneal effusion noted in these images.

There is no apparent lymphadenopathy noted in these images.

## **PRIMARY FINDINGS**

- **Hyperechoic hepatomegaly** - This appearance is non-specific and most consistent with a benign steroid (endocrine) or vacuolar hepatopathy or reactive or idiopathic hepatopathy. Inflammatory and/or infiltrative disease (such as round cell neoplasia) are also possible. Given the marked change in echogenicity/bright appearance, a diffuse inflammatory/reactive process is suspected.

## **SECONDARY FINDINGS**

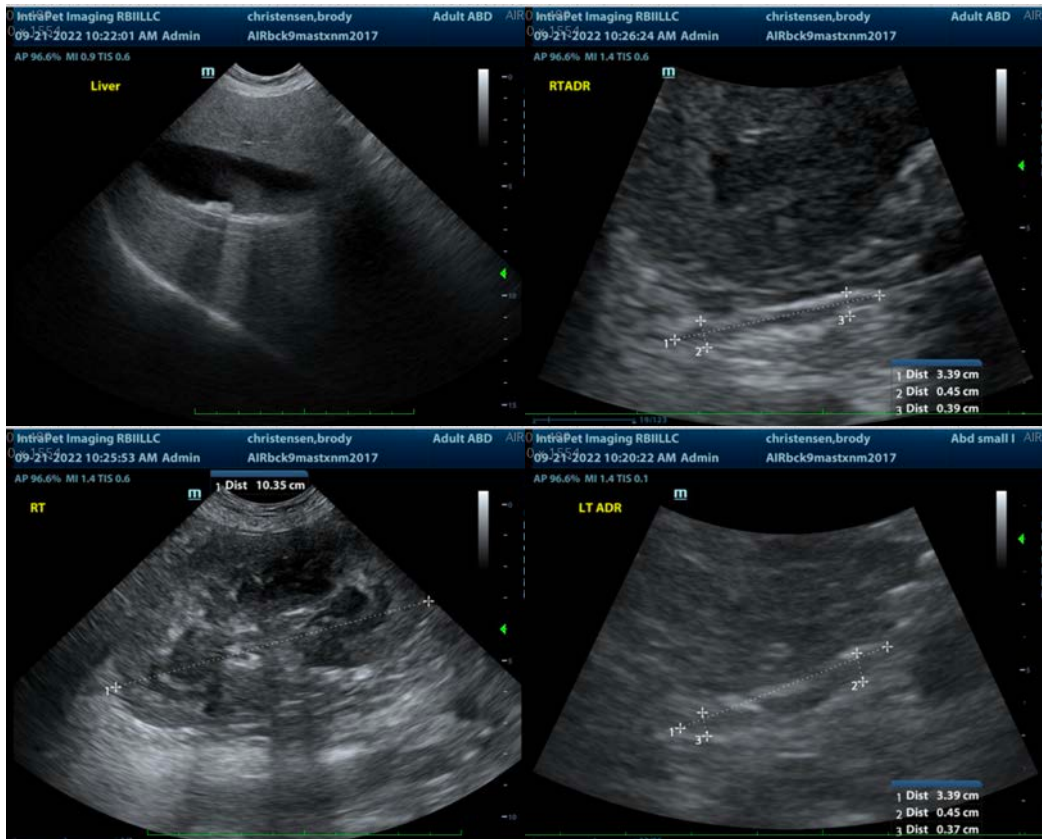
- **Spleen mineralization** - This is a benign change but can be associated with endocrinopathies, especially hyperadrenocorticism.
- **Flat adrenal glands** - Secondary to steroid administration.
- Urinary bladder sand and debris
- Non-obstructive nephrolithiasis in the kidneys bilaterally
- **Gallbladder debris** - Cholecystic debris is of unknown clinical significance. It can be seen with biliary stasis from fasting or illness. Cholecystic debris is not necessarily related to hepatobiliary disease. Echogenic bile is most commonly an incidental finding in dogs and should be interpreted in combination with clinical signs such as nausea, inappetence, cranial abdominal discomfort and/or laboratory changes such as increased ALP and/or increased Tbili.

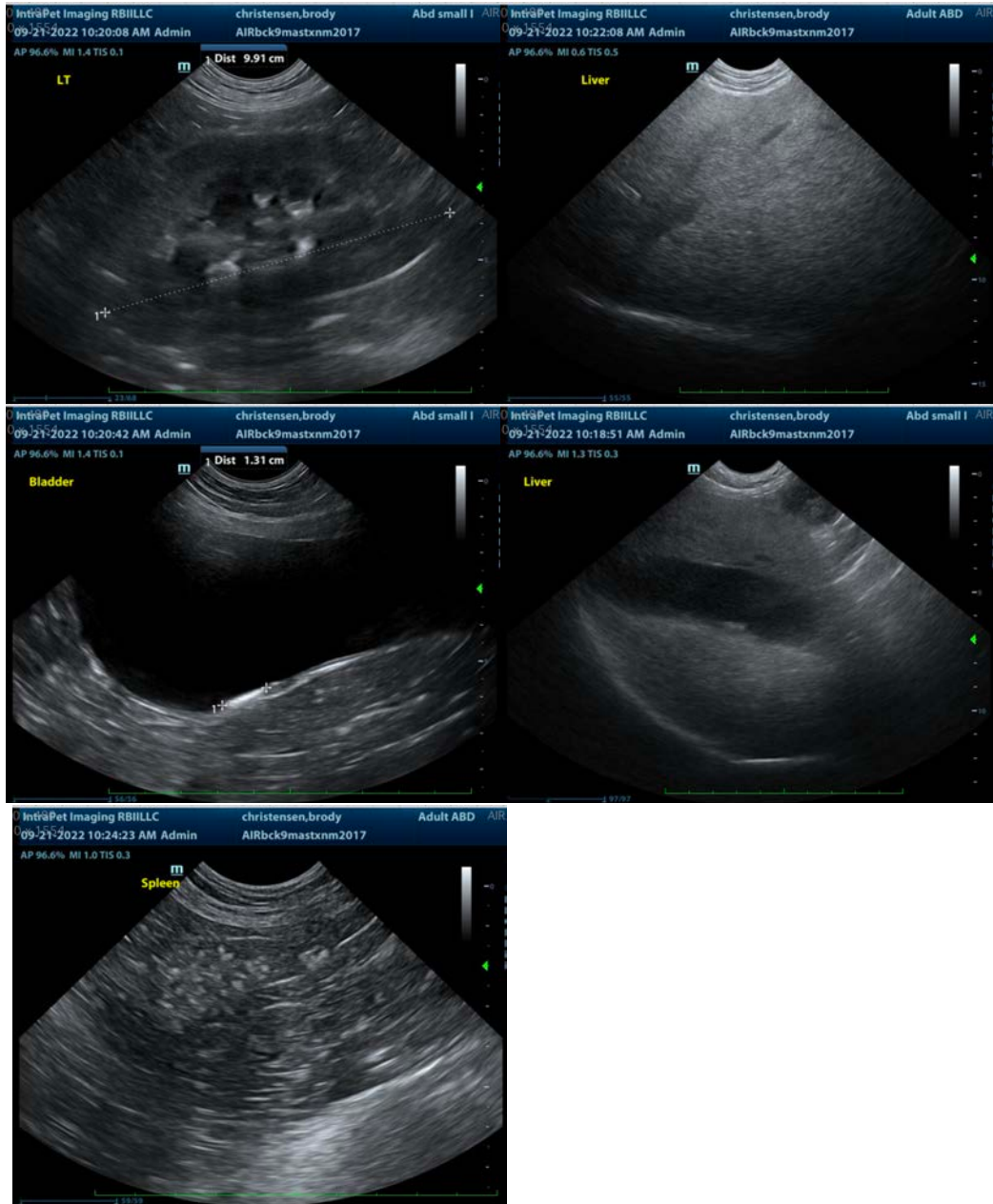
## INTERPRETATION OF THE FINDINGS & FURTHER RECOMMENDATIONS

There is not a specific cause to explain this patient's increased liver enzymes or leukocytosis present in these images currently. However, given the abnormal appearance to the liver, which is a change that can be seen with chronic high-dose steroids, a fine needle aspirate of the liver could be considered if patient's coagulation status is appropriate.

Comprehensive infectious disease testing is also warranted, given this patient's historical immune mediated disease and immunosuppression.

Both changes, however, the liver enzymes changes and the marked leukocytosis, while not routine, can occur with steroid therapy. At this patient's high dose, that differential is considered probable. Therefore, recommendations include the addition of a second immunosuppressant to allow rapid tapering of the Prednisone as tolerated by the patient to the lowest effective/tolerated dose. In the meantime, hepatic nutraceuticals are recommended.





The information and recommendations provided are based on the images presented by the referring veterinarian/sonographer. No evaluation can be communicated regarding pathology that was not visible in the image/video clips provided.

Thank you for this referral. If the clinical or image interpretation does not parallel your findings or if I can be of any further assistance please contact me.

**Beth Johnson, DVM, DACVIM**  
Beth.Johnson@sonopath.com