

**DATE PRESENTING CLINICAL SIGNS**

9/20/22 Not eating and vomiting.

PATIENT

Teddy Schneider

Current Medications: Cerenia 24 mg SID x 4 days, Entyce 1cc SID until eating well on own- both started 9/17.
Lab Results: ALP, WBC, TB, ALT, GGT all increased. HCTs slightly decreased.

Radiographs: Large abdominal mass- suspect spleen.

Date of Previous IntraPet Ultrasound: No previous.

Sedation: Declined.

Stat Report: Not requested.

SPECIES

Canine

ULTRASONOGRAPHIC EXAMINATION OF THE ABDOMEN**BREED**

Mix

Urinary System

Urinary bladder is adequately distended. It has a normal uniform wall thickness. Contents include primarily anechoic fluid with occasional echogenic non-shadowing debris, most consistent with exfoliated cells, mucous and/or small blood clots. There is some mineral/sandy debris settled along the dependent wall. Both sterile inflammation as well as urinary tract infection can also present with echogenic debris. No masses or cystoliths are observed. The trigone and visible pelvic urethra are normal in thickness with a smooth mucosal surface.

SEX

Neutered Male

AGE

1/1/07

Prostate is normal in size, echotexture and echogenicity for a neutered male.

WEIGHT

19.5 Pounds

Kidneys are overall normal in size and shape with smooth peripheral margination. A normal 1:3 cortex to medulla ratio is maintained. The medulla and cortices are uniform in texture with some mild increased cortical echogenicity and mild loss of corticomedullary distinction, expected in this age patient. There is no evidence of pyelectasia or infarcts observed. The left kidney measured 5.04 cm. The right kidney measures 5.46 cm. Non-obstructive linear multifocal hyperechoic diverticular foci with acoustic shadowing are noted in both kidneys. Cortical cysts are present in the right kidney.

INTERPRETED BYBeth Johnson, DVM
DACVIM**Adrenal Glands**

Adrenal glands are plump/swollen in size. Normal shape and contour are maintained without evidence of capsular invasion. Corticomedullary structure is unremarkable. Visible surrounding vasculature appears normal. The left adrenal gland measures 2.5 cm long x 1.0 cm at the cranial pole and 0.86 cm at the caudal pole. The right adrenal gland measures 2.3 cm long x 0.89 cm at the cranial pole and 0.97 cm at the caudal pole.

IMAGING PERFORMED BY

Rachel Brillhart RDMS

HOSPITAL NAME

Chadwell AH

Spleen

The spleen contains an approximately 7.0 cm in diameter hypo- to anechoic mass that disrupts normal contour off of the head of the spleen.

REFERRING VET

Dr. Gold

Liver

Liver is subjectively enlarged with mildly irregular margins. Parenchyma is mottled by multifocal discrete hypoechoic nodules of varying sizes "moth-eaten". In addition to the multifocal nodules, there is an approximately 5.0 cm in diameter, primarily homogeneous, isoechoic mass caudal to the gallbladder. Visible vasculature and biliary tree appear normal without distension or congestion.

INVOICE

41440

The gallbladder is non-distended in size. The wall is smooth without visible thickening. Luminal contents are primarily anechoic. There is no evidence of cystic or common bile duct dilation.

Gastrointestinal

The stomach wall is normal in thickness (canine < 0.5 cm and feline < 0.4 cm) and layering. The lumen of the stomach is empty with no evidence of obstruction, foreign material or infiltrative disease. Pyloric outflow tract appears patent.

The visible small intestines are normal in wall thickness and layering (canine duodenum < 0.5 cm and feline duodenum < 0.4 cm; other < 0.3 cm), except for just caudal to the stomach and medial to the spleen, where there is a focal bowel loop with emerging loss of layering that measures 0.90 cm thick. Small intestinal motility appears adequate (1-3 contractions per min). The lumen of the small intestine is empty with no evidence of obstruction, foreign material or infiltrative disease.

The visible colon is normal in wall thickness (< 0.2 cm) and layering. Contents are consistent with normal formed feces and gas.

Pancreas

The observed pancreas appears appropriately isoechoic to surrounding omental fat. The capsule is mildly irregular in shape. Parenchyma is mildly heterogenous and coarse. There is no visible pancreatic duct dilation. There is no evidence of active peripancreatic inflammation.

Free Abdomen

There is no evidence of free peritoneal effusion noted in these images. No pericardial effusion present in these images.

There is no apparent lymphadenopathy noted in these images.

PRIMARY FINDINGS

- **Nodular Liver** - This finding is concerning for infiltrative disease such as round cell neoplasia or metastatic neoplasia. Benign disease (nodular hyperplasia) cannot be ruled out but is considered less likely. The focal mass-like lesion caudal to the gallbladder may be a similar pathology to the nodules or may be a separate pathology, and differentials include both benign and/or malignant primary liver adenoma, hepatoma, or hepatocellular carcinoma versus other infiltrative malignant neoplasia such as round cell neoplasia. Marked benign nodular hyperplasia cannot be ruled out but is considered less likely.
- **Large, hypo- to anechoic splenic mass** – Concerning for infiltrative neoplasia such as sarcoma. However, benign hematoma, extramedullary hematopoiesis, etc. can mimic malignant lesions and cannot be differentiated or ruled out without tissue sampling.
- **Focal small bowel thickening with emerging loss of layering** – Concerning for infiltrative neoplasia such as round cell neoplasia, potentially the same process involving the liver and spleen, but that can't be determined without tissue sampling. Benign inflammatory change, potentially secondary to chronic active pancreatitis versus other is also considered a differential for the bowel changes.
- **Pancreatic age-related remodeling with possible chronic active pancreatitis** – Mild irregularities are consistent with benign age-related change. Low-grade smoldering chronic pancreatitis cannot be ruled out and should be suspected in the face of appropriate clinical signs.
- **Bilateral adrenomegaly** – consistent with adrenal hyperplasia secondary to pituitary dependent hyperadrenocorticism vs stress or normal variant. Interpret in combination with clinical signs of hyperadrenocorticism.

SECONDARY FINDINGS

- Urinary bladder debris including mineral sand debris
- Age related kidney changes with non-obstructive dystrophic mineralization bilaterally

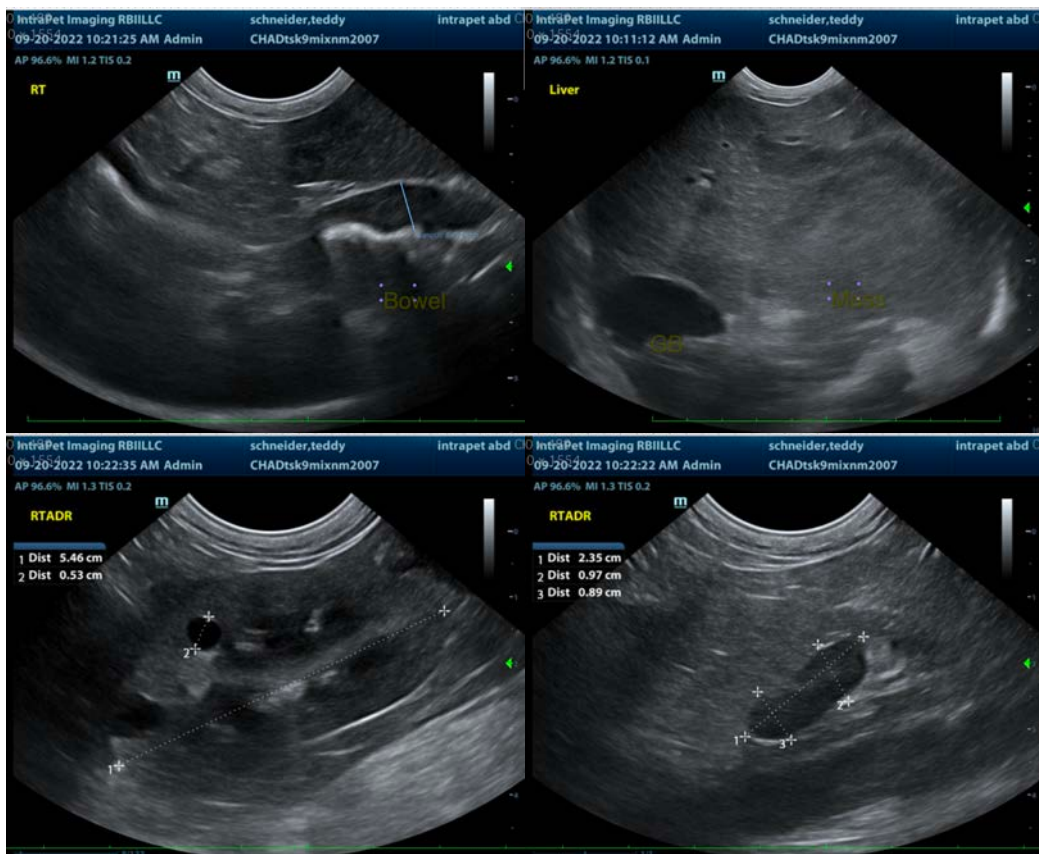
INTERPRETATION OF THE FINDINGS & FURTHER RECOMMENDATIONS

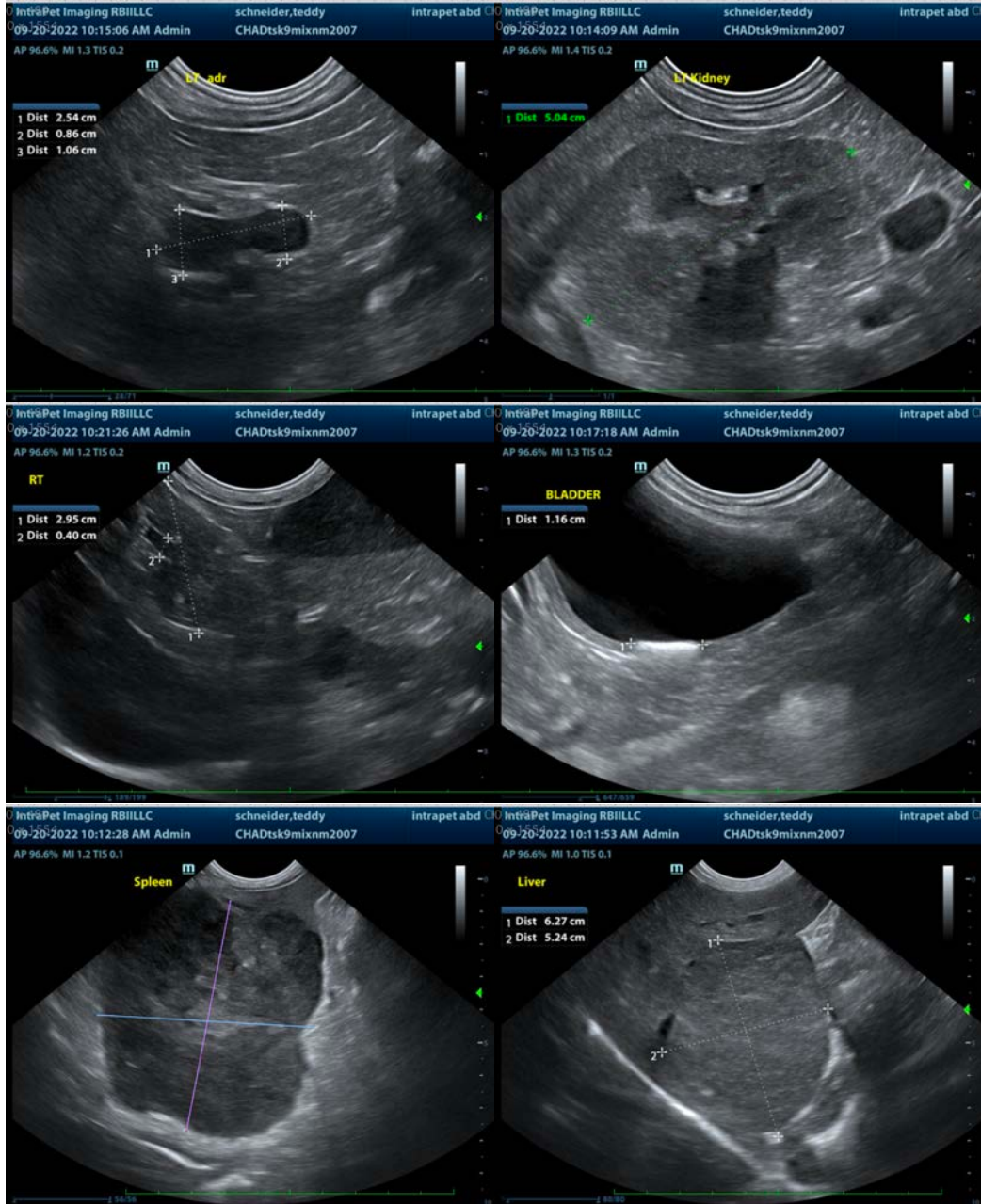
Three view thoracic radiographs are recommended for further assessment of cardio-pulmonary status as well as to further evaluate for any evidence of metastatic disease, if not recently evaluated.

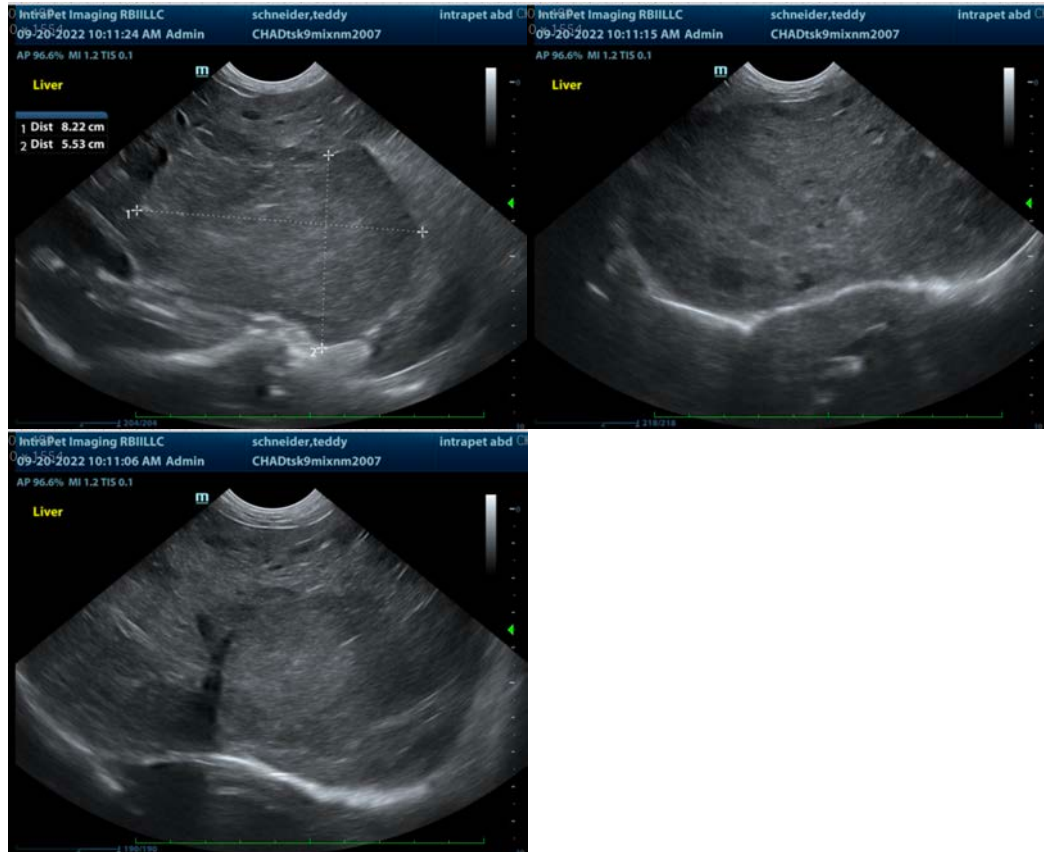
A fine needle aspirate of the diffuse liver nodular change as well as the focal liver mass +/- the spleen could be considered if patient's coagulation status is appropriate, understanding the risk of possible hemorrhage with the splenic aspirate. Alternatively, an exploratory laparotomy could be considered for further evaluation of the spleen, liver, and the bowel, with plans to biopsy all pathology and remove the spleen, focal liver mass +/- suspected bowel mass, if possible.

Urinalysis and, if indicated based on urinalysis results, urine culture are recommended. If protein is present in an otherwise quiet sediment, protein quantification with a urine protein to creatinine ration is recommended.

Finally, hyperadrenocorticism may be present in this patient, given the adrenomegaly. However, further evaluation of hyperadrenocorticism, including treatment, is not recommended in the face of the ongoing illness at this time.







The information and recommendations provided are based on the images presented by the referring veterinarian/sonographer. No evaluation can be communicated regarding pathology that was not visible in the image/video clips provided.

Thank you for this referral. If the clinical or image interpretation does not parallel your findings or if I can be of any further assistance please contact me.

Beth Johnson, DVM, DACVIM
Beth.Johnson@sonopath.com