

**DATE**

9/19/22

PRESENTING CLINICAL SIGNS

History: Grade 4/4 heart murmur, non clinical. Severe periodontal dz. So recommended echo prior to dental to assess anesthetic risk. ALT and ALP were elevated.

PATIENT

Toby Walsh

Current Medications: None.

Date of Previous IntraPet Ultrasound: No previous.

Sedation: Not required to complete full diagnostic ultrasound.

Stat Report: Not requested.

Imaging Performed By: Stephanie Warga RDCS, RVT.

SPECIES

Canine

BREED

Yorkshire Terrier Mix

ULTRASONOGRAPHIC EXAMINATION OF THE ABDOMEN**Urinary System**

Urinary bladder is adequately distended with anechoic contents. No masses, inflammatory changes, echogenic sediment or cystoliths are observed. The urinary bladder, trigone and visible pelvic urethra are normal in thickness with a smooth mucosal surface.

SEX

Neutered Male

Prostate is normal in size, echotexture and echogenicity for a neutered male.

AGE

4/28/09

Left kidney is normal is size (4.24 cm), shape and echogenicity. It has smooth peripheral margination. There is a normal 1:3 cortex to medulla ratio with appropriate corticomedullary distinction. There is no evidence of pyelectasia, mineral or infarcts observed.

WEIGHT

11/13 Pounds

Right kidney is normal is size (3.93 cm), shape and echogenicity. It has smooth peripheral margination. There is a normal 1:3 cortex to medulla ratio with appropriate corticomedullary distinction. There is no evidence of pyelectasia, mineral or infarcts observed.

INTERPRETED BYBeth Johnson, DVM
DACVIM**Adrenal Glands**

Adrenal glands are plump/swollen in size. Normal shape and contour are maintained without evidence of capsular invasion. Corticomedullary structure is unremarkable. Visible surrounding vasculature appears normal. The left adrenal gland measures 2.7 cm long x 0.87 cm at the cranial pole and 0.81 cm at the caudal pole. Hyperechoic nodules are noted, one in the cranial pole and another one in the caudal pole of the left adrenal gland. The nodules do not disrupt normal shape and/or architecture. The right adrenal gland measures 2.0 cm long x 0.77 cm at the cranial pole and 0.5 cm at the caudal pole.

HOSPITAL NAME

Everhart Wellpet

Spleen

Spleen is subjectively normal in size with a normal smooth capsular contour. Parenchyma is appropriately finely textured and homogenous with normal echogenicity relative to surrounding tissue (hyperechoic to liver). No focal nodules or masses are observed. Splenic vasculature appears normal.

REFERRING VET

Dr. Del Favero

INVOICE

17375

Liver

Liver is subjectively enlarged (swollen contour) without disruption of architecture. It has a normal homogenous echotexture. Parenchyma is diffusely hyperechoic characterized by less prominent than normal portal vein walls and increased echogenicity relative to the spleen and falciform fat. No focal lesions are observed. Visible vasculature and biliary tree appear normal without distension or congestion.

Gallbladder is moderately distended with anechoic bile as well as suspended and gravity dependent echogenic debris. The wall is smooth without visible thickening. There is no evidence of cystic or CBD dilation. There is no evidence of effusion or inflammation.

Gastrointestinal

The visible stomach wall is normal in thickness and layering. The lumen of the stomach is empty with no evidence of obstruction, foreign material or infiltrative disease. Pyloric outflow tract appears patent.

The visible small intestines are normal in wall thickness and layering. Small intestinal motility appears adequate (1-3 contractions per min). The lumen of the small intestine is empty with no evidence of obstruction, foreign material or infiltrative disease.

The visible colon is normal in wall thickness and layering. Contents are consistent with normal formed feces and gas.

Pancreas

Pancreas is prominent (enlarged) in size and mildly irregular in shape with a slightly undulating contour. Parenchyma is coarse in echotexture and heterogenous to hypoechoic in echogenicity.

Free Abdomen

There is no evidence of peritoneal effusion. There is no apparent lymphadenopathy.

ULTRASONOGRAPHIC FINDINGS

- Bilateral adrenomegaly– consistent with adrenal hyperplasia secondary to pituitary dependent hyperadrenocorticism vs stress or normal variant. Interpret in combination with clinical signs of hyperadrenocorticism.

* Hyperechoic nodules in the cranial and caudal pole of the left adrenal gland. Differentials for the left adrenal nodules include primary adrenal cortical adenoma or adenocarcinoma, pheochromocytoma, myelolipoma, adrenal hyperplasia secondary to pituitary disease or metastatic disease. Ultrasound alone cannot differentiate between functional and non-functional nodules and/or between benign and malignant disease. Small nodules without other evidence of abdominal disease (to suggest metastatic disease) and/or clinical signs (to suggest adrenal disease) are most often incidental and should be monitored.
- Hyperechoic hepatomegaly – This appearance is non-specific and most consistent with a benign steroid (endocrine) or vacuolar hepatopathy or reactive or idiopathic hepatopathy. Inflammatory and/or infiltrative disease (such as round cell neoplasia) are also possible but considered less likely.
- Gallbladder debris - Cholecystic debris is of unknown clinical significance. It can be seen with biliary stasis from fasting or illness. Cholecystic debris is not necessarily related to hepatobiliary disease. Echogenic bile is most commonly an incidental finding in dogs and should be interpreted in combination with clinical signs such as nausea, inappetence, cranial abdominal discomfort and/or laboratory changes such as increased ALP and/or increased Tbili.
- Chronic active pancreatitis

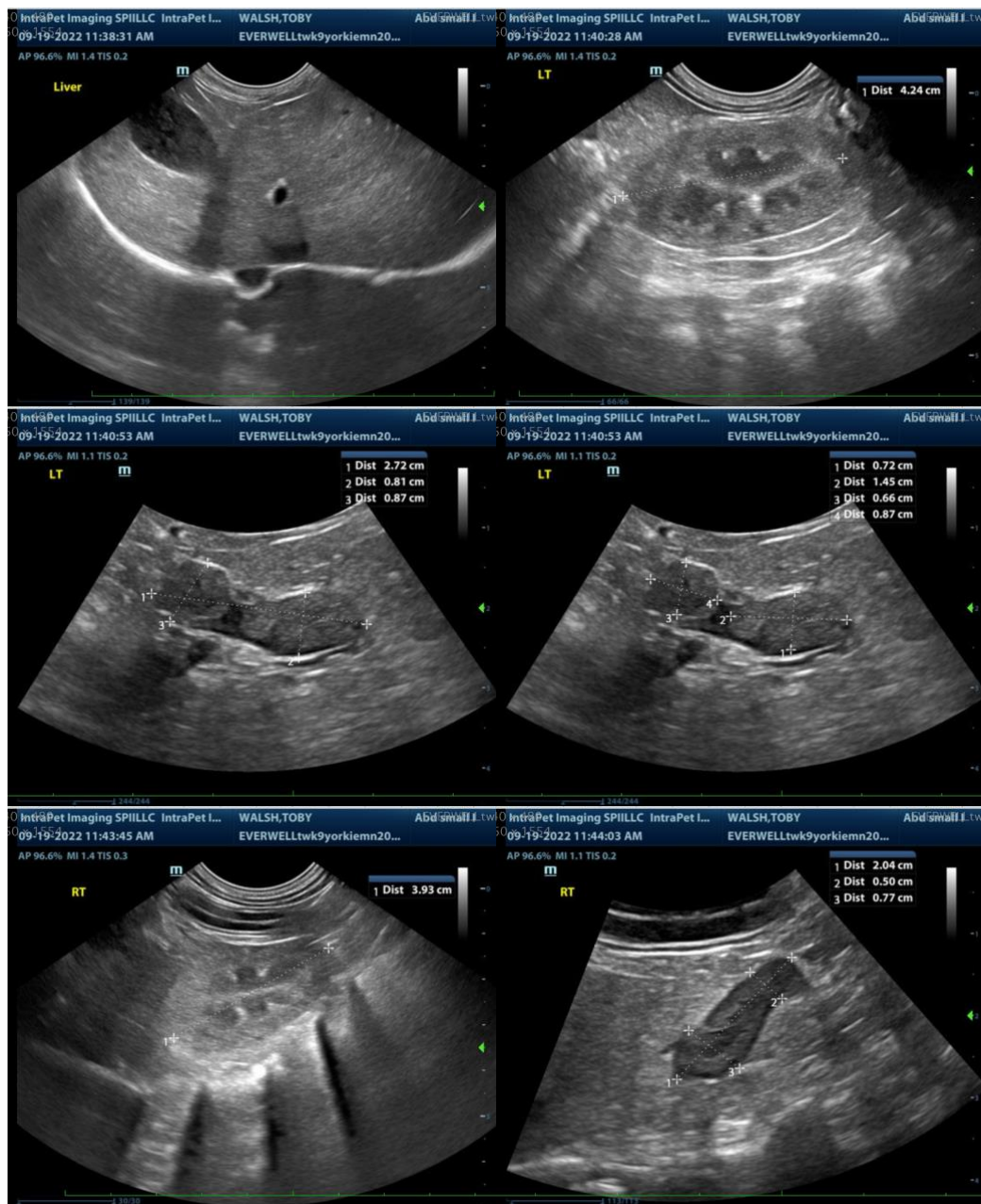
INTERPRETATION OF THE FINDINGS & FURTHER RECOMMENDATIONS

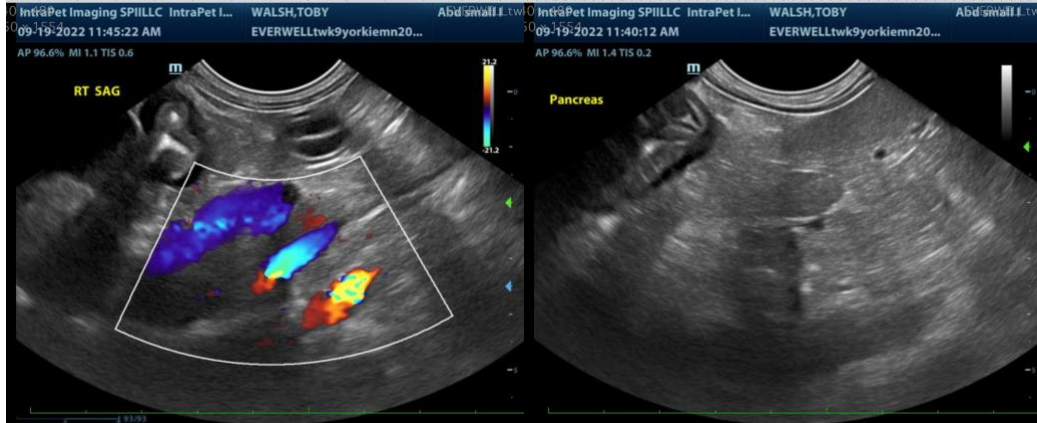
Further evaluation of this patients liver enzymes depends on whether the pattern is primarily cholestatic versus hepatocellular liver injury. However, given the ultrasound changes, the described adrenal gland, liver and gallbladder changes are all suggestive of hyperadrenocorticism. If clinical signs of hyperadrenocorticism, such as polyuria, polydipsia, polyphagia, panting, hair loss, hypertension, etc. are present, testing for hyperadrenocorticism with a LDDS test is warranted. If a LDDS test has been evaluated

with a normal result, investigation of possible atypical hyperadrenocorticism with a full ACTH stimulation adrenal panel to the University of Tennessee could be considered. If clinical signs are not present, monitoring is recommended with testing pursued when/if clinical signs develop.

If not recently evaluated, blood pressure is recommended.

If not recently evaluated, a urinalysis and, if indicated based on urinalysis results, urine culture are also recommended. If protein is present in an otherwise quiet sediment, protein quantification with a urine protein to creatinine ratio is recommended.





The information and recommendations provided are based on the images presented by the referring veterinarian. No evaluation can be communicated regarding pathology that was not visible in the image/video clips provided.

Thank you for this referral. If the clinical or image interpretation does not parallel your findings or if I can be of any further assistance please contact me.

Beth Johnson, DVM DACVIM
Beth.Johnson@SonoPath.com