

**DATE**

9/19/22

PRESENTING CLINICAL SIGNS

History: Inappetance/vomiting: aFAST/tFAST: negative for free fluid. 3-view thoracic and abdominal rads: splenomegaly, decreased serosal detail in mid/cranial abdomen, moderate ingesta in stomach. Hx of Ehrlichia positive.

PATIENT

Buddy Cook

Current Medications: Started on Doxycycline 500 mg/day and Cerenia 160 mg q 24 hrs PRN for vomiting and Gabapentin 300 q 12 hrs. (Started Doxy on 9/2 and Cerenia/Gaba on 9/8)

SPECIES

Lab Results: Ehrlichia positive (3+ yrs and again this year). CBC/Chem 21/T4/Free T4/UA all WNL.

Canine

Date of Previous IntraPet Ultrasound: No previous.

BREED

Mix

Sedation: Not required to complete full diagnostic ultrasound.

Stat Report: Not requested.

Imaging Performed By: Stephanie Warga RDCS, RVT.

SEX

Neutered Male

ULTRASONOGRAPHIC EXAMINATION OF THE ABDOMEN**Urinary System**

Urinary bladder is only mildly distended (empty). Visible contents are anechoic. Urinary bladder wall is unable to be fully assessed for pathology without further distension. No visible masses or cystoliths are observed. The trigone and visible pelvic urethra are normal thickness with a smooth mucosal surface. If there are urinary signs and/or concern for urinary bladder pathology, reassessment after complete filling is recommended.

AGE

9/24/14

Prostate is normal in size, echotexture and echogenicity for a neutered male.

WEIGHT

105 Pounds

Left kidney is normal is size (7.87 cm), shape and echogenicity. It has smooth peripheral margination. There is a normal 1:3 cortex to medulla ratio with appropriate corticomedullary distinction. There is no evidence of pyelectasia, mineral or infarcts observed.

INTERPRETED BYBeth Johnson, DVM
DACVIM

Right kidney is normal is size (7.2 cm), shape and echogenicity. It has smooth peripheral margination. There is a normal 1:3 cortex to medulla ratio with appropriate corticomedullary distinction. There is no evidence of pyelectasia, mineral or infarcts observed.

HOSPITAL NAME

North Laurel AH

Adrenal Glands

Left adrenal gland is normal in size (2.37 cm long x 0.62 cm at cranial pole and 0.56 cm at caudal pole), shape and overall architecture, echogenicity and echotexture. Visible surrounding vasculature appears normal.

REFERRING VET

Dr. Nelson

Right adrenal gland is normal in size (3.0 cm long x 0.66 cm at cranial pole and 0.74 cm at caudal pole), shape and overall architecture, echogenicity and echotexture. Visible surrounding vasculature appears normal.

INVOICE

17377

Spleen

Spleen is subjectively large in size with normal smooth margins. Parenchyma is normal in echogenicity with a coarse/heterogenous echotexture. No focal nodules or masses are observed. Splenic vasculature appears normal.

Liver

Liver is subjectively normal in size with normal smooth curvilinear peripheral contour. Parenchyma is appropriately hypoechoic to the spleen in echogenicity and appropriately mildly coarse and homogenous in

echotexture. No focal lesions are observed. Visible vasculature and biliary tree appear normal without distension or congestion.

Gallbladder is moderately distended with anechoic bile as well as suspended and gravity dependent echogenic debris. The wall is smooth without visible thickening. There is no evidence of cystic or CBD dilation. There is no evidence of effusion or inflammation.

Gastrointestinal

The visible stomach wall is normal in thickness and layering. The lumen of the stomach is mildly distended with very echogenic reverberation artifact from intraluminal gas. There is no evidence of obstruction, foreign material or infiltrative disease; however, complete visualization of far wall is partially inhibited by gas. Pyloric outflow tract appears patent.

The visible small intestines are normal in wall thickness and layering. Small intestinal motility appears adequate (1-3 contractions per min). The lumen of the small intestine is empty with no evidence of obstruction, foreign material or infiltrative disease.

The visible colon is normal in wall thickness and layering. Contents are consistent with normal formed feces and gas.

Pancreas

The observed pancreas appears appropriately isoechoic to surrounding omental fat. Visible capsule is smooth and normal in contour. Visible pancreatic parenchyma is homogenous and unremarkable. There is no visible pancreatic duct dilation. There is no evidence of active peripancreatic inflammation.

Free Abdomen

There is no evidence of peritoneal effusion. There is no apparent lymphadenopathy. No evidence of pericardial effusion is noted in these images.

ULTRASONOGRAPHIC FINDINGS

- Coarse splenomegaly – can be associated with congestion caused by sedation (if sedated) but can also be associated with diffuse infiltrative disease. Both benign conditions such as extramedullary hematopoiesis, lymphoid hyperplasia, amyloidosis (leave amyloidosis out if canine) as well as infiltrative neoplastic diseases such as round cell neoplasia should be considered.
- Gallbladder debris - Cholecystic debris is of unknown clinical significance. It can be seen with biliary stasis from fasting or illness. Cholecystic debris is not necessarily related to hepatobiliary disease. Echogenic bile is most commonly an incidental finding in dogs and should be interpreted in combination with clinical signs such as nausea, inappetence, cranial abdominal discomfort and/or laboratory changes such as increased ALP and/or increased Tbili. Some of the debris appears to be mineral and nonobstructive nonshadowing cholecystolith can't be ruled out.

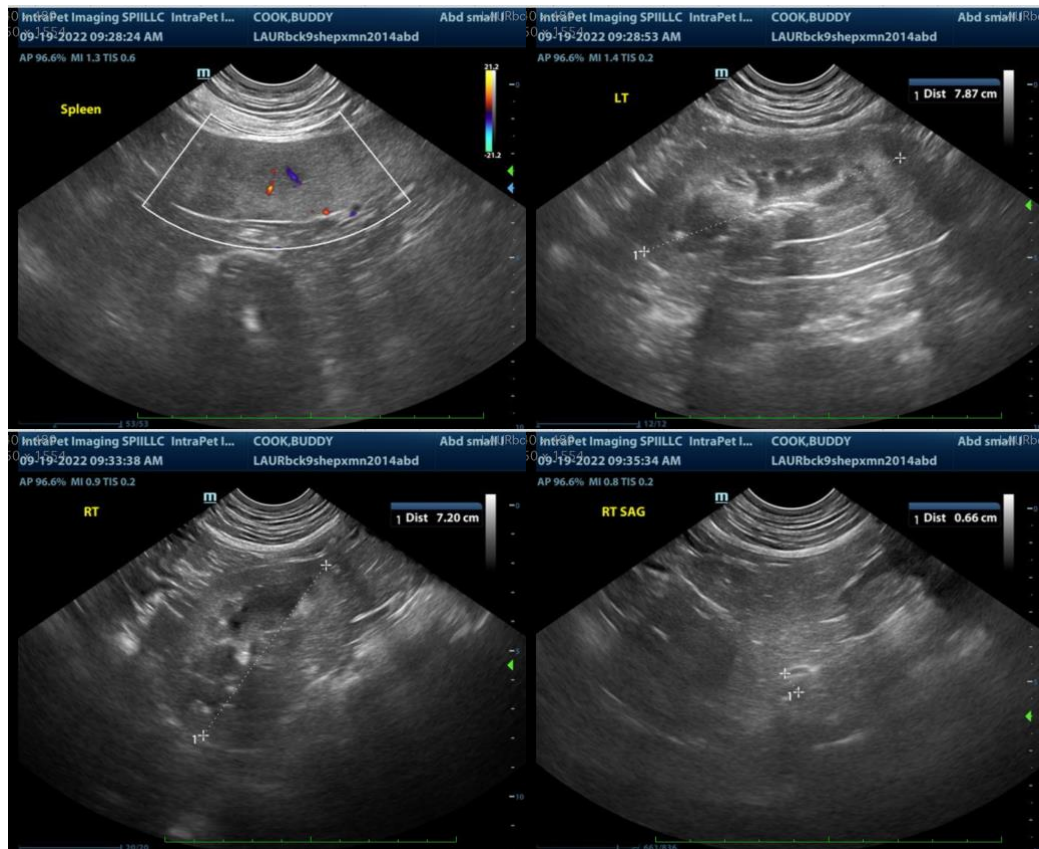
INTERPRETATION OF THE FINDINGS & FURTHER RECOMMENDATIONS

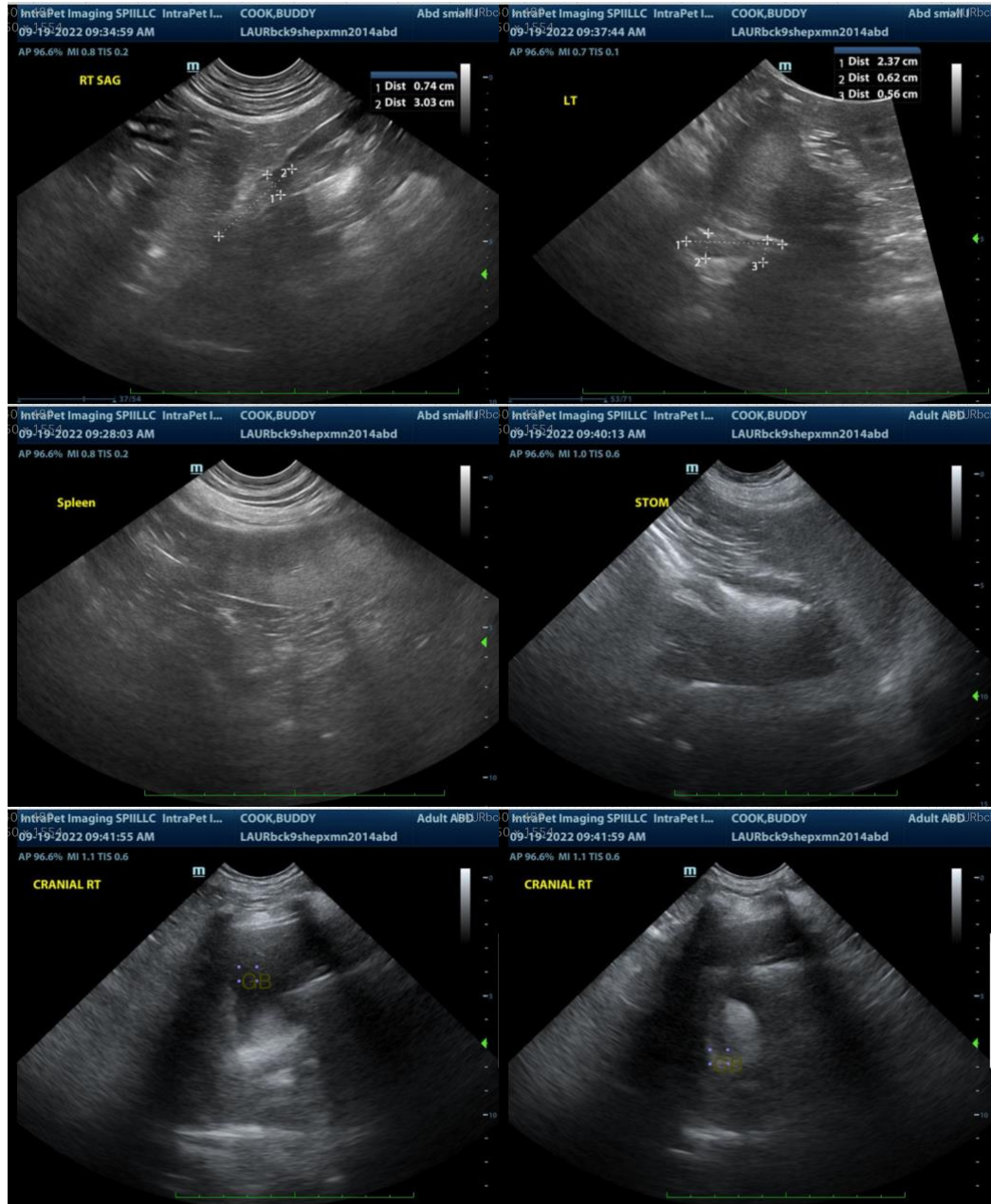
There is not a definitive obvious cause for this patient's reported vomiting in these images. The splenic changes are likely incidental and more likely related to the Ehrlichia than the vomiting. However, a fine needle aspirate of the spleen is recommended if patient's coagulation status is appropriate to more definitively rule out infiltrative disease.

In the meantime, supportive/symptomatic medical management of the gastrointestinal signs is

recommended in the form of antiemetics, gastroprotectants (such as Omeprazole), appetite stimulants if necessary and potentially a short term bland easy to digest diet. Empirical deworming is also recommended if not recently evaluated with a 5-day course of Panacur.

If gastrointestinal signs persist beyond medical management, next diagnostic considerations could include a gastrointestinal malabsorption panel (including cobalamin, folate, TLI and PLI) to Texas A&M GI Laboratory is recommended for further evaluation of GI and pancreatic function. A baseline cortisol is recommended. If baseline cortisol is less than 2, a full ACTH stimulation test is recommended to rule out hypoadrenocorticism, ultimately followed by an upper GI endoscopy if warranted based on progression of clinical signs.





The information and recommendations provided are based on the images presented by the referring veterinarian. No evaluation can be communicated regarding pathology that was not visible in the image/video clips provided.

Thank you for this referral. If the clinical or image interpretation does not parallel your findings or if I can be of any further assistance please contact me.

Beth Johnson, DVM DACVIM
Beth.Johnson@SonoPath.com