

**PATIENT**

Hollis Galvan

SPECIES

Canine

BREED

Mixed

SEX

Neutered Male

AGE

9 Years

WEIGHT

30 Pounds

INTERPRETED BYBeth Johnson, DVM
DACVIM**IMAGING PERFORMED BY**

Amy Mayhew, LVT

HOSPITAL NAME

SVS Imaging MI

REFERRING VETTown Center Vet
Associates**INVOICE**

41363

DATE

9/15/22

PRESENTING CLINICAL SIGNS

P started vomiting and being lethargic a week ago. O thought it was caused by him eating rodent feces in their yard. On Friday, P started having diarrhea and O noticed he was pale. O brought P to AEC in Novi on Monday. We could not obtain the records from AEC before the appointment, but O states they did BW, Radiographs, and gave fluids.

Abnormal PE/Chem/CBC/UA Results: Sent out CBC and Phenobarbital levels- pending. Concern for regenerative anemia. Please see attached labs

ULTRASONOGRAPHIC EXAMINATION OF THE ABDOMEN**Urinary System**

The urinary bladder is moderately distended with anechoic contents. No masses, inflammatory changes, echogenic sediment or cystoliths are observed. The urinary bladder, trigone and visible pelvic urethra are normal in thickness with a smooth mucosal surface.

Prostate is normal in size, echotexture and echogenicity for a neutered male.

The right kidney is normal in size (5.06 cm), shape and echogenicity. It has smooth peripheral margination. There is a normal 1:3 cortex to medulla ratio with appropriate corticomedullary distinction. There is no evidence of pyelectasia, mineral or infarcts observed.

The left kidney is normal in size (4.9 cm), shape and echogenicity. It has smooth peripheral margination. There is a normal 1:3 cortex to medulla ratio with appropriate corticomedullary distinction. There is no evidence of pyelectasia, mineral or infarcts observed.

Adrenal Glands

Adrenal glands are largely normal in size, shape and contour. Some parenchymal heterogeneity is present without concerning capsular distortion. These changes are likely normal for this age but should be monitored if there is any suspicion of adrenal disease. The left adrenal gland measures 0.38 cm at the cranial pole and 0.43 cm at the caudal pole. The right adrenal gland measures 0.53 cm at the cranial pole and 0.52 cm at the caudal pole.

Spleen

The spleen is subjectively normal in size with a normal smooth capsular contour. Parenchyma is appropriately finely textured and homogenous with normal echogenicity relative to surrounding tissue (hyperechoic to liver). A 1.0 cm hypoechoic mid body nodule is noted, non-capsule disrupting. Splenic vasculature appears normal.

Liver

The liver is subjectively normal in size with normal smooth curvilinear peripheral contour. Parenchyma is appropriately hypoechoic to the spleen in echogenicity and appropriately mildly coarse and homogenous in echotexture. No focal lesions are observed. Visible vasculature and biliary tree appear normal without distension or congestion.

The gallbladder is non-distended in size. The wall is smooth without visible thickening. Luminal contents are primarily anechoic. There is no evidence of cystic or common bile duct dilation.

Gastrointestinal

The visible stomach wall is normal in thickness and layering. The lumen of the stomach is mildly distended with very echogenic reverberation artifact from intraluminal gas. There is no evidence of

IMAGING PERFORMED BY

SVS Mobile Imaging MI 734-637-7711
svsimagingmi@gmail.com



PATIENT

Hollis Galvan

SPECIES

Canine

BREED

Mixed

SEX

Neutered Male

AGE

9 Years

WEIGHT

30 Pounds

INTERPRETED BY

Beth Johnson, DVM
DACVIM

IMAGING PERFORMED BY

Amy Mayhew, LVT

HOSPITAL NAME

SVS Imaging MI

REFERRING VET

Town Center Vet
Associates

INVOICE

41363

DATE

9/15/22

obstruction, foreign material or infiltrative disease; however, complete visualization of far wall is partially inhibited by gas. Pyloric outflow tract appears patent.

The visible small intestines are normal in wall thickness and layering (canine duodenum < 0.5 cm and feline duodenum < 0.4 cm; other < 0.3 cm). Small intestinal motility appears adequate (1-3 contractions per min). The lumen of the small intestine is empty with no evidence of obstruction, foreign material or infiltrative disease.

The visible colon is normal in wall thickness (< 0.2 cm) and layering. Contents are consistent with normal formed feces and gas.

Pancreas

The pancreatic parenchyma is appropriately isoechoic to surrounding tissue. Visible capsule is smooth and normal in contour. There is no visible pancreatic duct dilation. There is no evidence of active peripancreatic inflammation.

Free Abdomen

There is no evidence of free peritoneal effusion noted in these images.

The mesenteric lymph nodes are prominent in size with swollen capsular contour. Normal elongated shape (length to width ratio) is maintained. There is no loss of parenchymal detail.

ULTRASONOGRAPHIC FINDINGS

- **Hypo to anechoic splenic nodule** – likely represents a benign lesion such as a cyst, hematoma, nodular hyperplasia, extramedullary hematopoiesis, etc., however while considered less likely, infiltrative neoplasia can mimic benign lesions, and cannot be ruled out.
- **Reactive mesenteric lymph nodes** – infiltrative neoplastic disease cannot be ruled out but is considered less likely.
- Age related adrenal changes

INTERPRETATION OF THE FINDINGS & FURTHER RECOMMENDATIONS

Differentials for this patient's regenerative anemia include hemorrhage (which there is no evidence of ultrasonographically in the images provided) versus possibly hemolysis. Recommendations include a pathology review of the CBC to look for evidence of hemolysis, followed by comprehensive infectious disease testing. A fecal exam is also recommended in addition to empirical deworming with a 5-day course of Panacur.

To further work up underlying causes that may have contributed to hemolysis, as well as to look for other evidence of hemorrhage, three view thoracic radiographs are recommended.

If hemorrhage is ruled out and hemolysis is suspected, recommendations are to address any underlying causes such as infectious diseases that are diagnosed and/or manage likely autoimmune hemolysis with immunosuppression.

IMAGING PERFORMED BY

SVS Mobile Imaging MI 734-637-7711
svsimagingmi@gmail.com



PATIENT

Hollis Galvan

SPECIES

Canine

BREED

Mixed

SEX

Neutered Male

AGE

9 Years

WEIGHT

30 Pounds

INTERPRETED BY

Beth Johnson, DVM
DACVIM

IMAGING PERFORMED BY

Amy Mayhew, LVT

HOSPITAL NAME

SVS Imaging MI

REFERRING VET

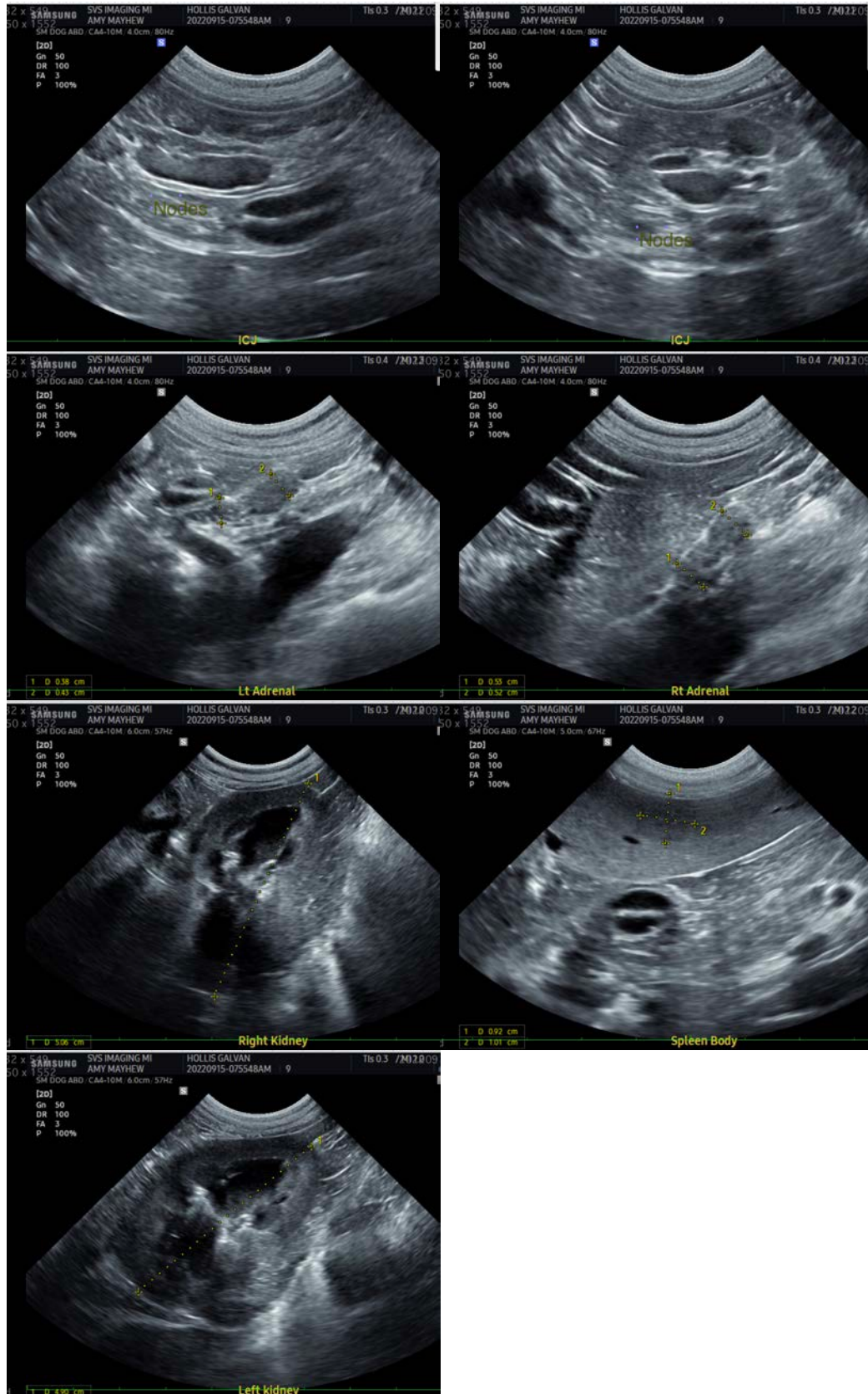
Town Center Vet
Associates

INVOICE

41363

DATE

9/15/22



IMAGING PERFORMED BY

SVS Mobile Imaging MI 734 - 637 - 7711
svsimagingmi@gmail.com



PATIENT

Hollis Galvan

The information and recommendations provided are based on the images presented by the referring veterinarian/sonographer. No evaluation can be communicated regarding pathology that was not visible in the image/video clips provided.

SPECIES

Canine

Thank you for this referral. If the clinical or image interpretation does not parallel your findings or if I can be of any further assistance please contact me.

Beth Johnson, DVM, DACVIM
Beth.Johnson@sonopath.com

BREED

Mixed

SEX

Neutered Male

AGE

9 Years

WEIGHT

30 Pounds

INTERPRETED BY

Beth Johnson, DVM
DACVIM

IMAGING PERFORMED BY

Amy Mayhew, LVT

HOSPITAL NAME

SVS Imaging MI

REFERRING VET

Town Center Vet
Associates

INVOICE

41363

DATE

9/15/22