

**DATE PRESENTING CLINICAL SIGNS**

9/15/22 Persistently elevated liver values and proteinuria.

**PATIENT**

Gemma Adams

Current Medications: Hepatosupport liver supplement, Welactin fish oil.

Lab Results: ALP 220, ALT 120.

Date of Previous IntraPet Ultrasound: No previous.

Sedation: Patient sedated with Torbugesic.

Stat Report: Not requested.

**SPECIES**

Canine

**ULTRASONOGRAPHIC EXAMINATION OF THE ABDOMEN****BREED**

Retriever X

**Urinary System**

The urinary bladder is moderately distended with anechoic contents. No masses, inflammatory changes, echogenic sediment or cystoliths are observed. The urinary bladder, trigone and visible pelvic urethra are normal in thickness with a smooth mucosal surface.

**SEX**

Spayed Female

The right kidney is normal in size (7.07 cm), shape and echogenicity. It has smooth peripheral margination. There is a normal 1:3 cortex to medulla ratio with appropriate corticomedullary distinction. There is no evidence of pyelectasia, mineral or infarcts observed.

**AGE**

2/15/11

The left kidney is normal in size (6.93 cm), shape and echogenicity. It has smooth peripheral margination. There is a normal 1:3 cortex to medulla ratio with appropriate corticomedullary distinction. There is no evidence of pyelectasia, mineral or infarcts observed.

**WEIGHT**

90.2 Pounds

**Adrenal Glands**

The right adrenal gland is small (flattened contour). Corticomedullary structure is unremarkable. Visible surrounding vasculature appears normal. The right adrenal gland measures 2.75 cm long x 0.53 cm at the cranial pole and 0.54 cm at the caudal pole.

**INTERPRETED BY**

Beth Johnson, DVM  
DACVIM

The left adrenal gland is enlarged (2.76 cm long x 1.1 cm at the cranial pole and 0.87 cm at the caudal pole) with mild heterogenous parenchymal changes. Swollen capsular expansion is noted without evident capsular escape or vascular invasion.

**IMAGING PERFORMED BY**

Andi Parkinson RDMS

**Spleen**

Spleen is subjectively normal in size with a normal smooth capsular contour. Parenchyma is appropriately finely textured and homogenous with normal echogenicity relative to surrounding tissue (hyperechoic to liver). Multifocal well-demarcated hyperechoic homogenous nodules are noted. Splenic vasculature appears normal.

**HOSPITAL NAME**

Everhart Vet Hospital

**Liver**

Liver is subjectively enlarged with mildly irregular margins. Parenchyma is mottled by multifocal discrete hypoechoic nodules with hyperechoic centers of varying sizes (target lesions). Visible vasculature and biliary tree appear normal without distension or congestion.

**REFERRING VET**

Dr. Rubinstein

**INVOICE**

41380

The gallbladder is non-distended in size. The wall is smooth without visible thickening. Luminal contents are primarily anechoic. There is no evidence of cystic or common bile duct dilation.

**Gastrointestinal**

The stomach wall is normal in thickness (canine < 0.5 cm and feline < 0.4 cm) and layering. The lumen of the stomach is empty with no evidence of obstruction, foreign material or infiltrative disease. Pyloric outflow tract appears patent.

The visible small intestines are normal in wall thickness and layering (canine duodenum < 0.5 cm and feline duodenum < 0.4 cm; other < 0.3 cm). Small intestinal motility appears adequate (1-3 contractions per min). The lumen of the small intestine is empty with no evidence of obstruction, foreign material or infiltrative disease.

The visible colon is normal in wall thickness (< 0.2 cm) and layering. Contents are consistent with normal formed feces and gas.

### ***Pancreas***

The pancreatic parenchyma is appropriately isoechoic to surrounding tissue. Visible capsule is smooth and normal in contour. There is no visible pancreatic duct dilation. There is no evidence of active peripancreatic inflammation.

### ***Free Abdomen***

There is no evidence of free peritoneal effusion noted in these images.

There is no apparent lymphadenopathy noted in these images.

The uterine stump with suture is visible.

## **PRIMARY FINDINGS**

- **Nodular Liver** - This finding is concerning for infiltrative disease such as round cell neoplasia or metastatic neoplasia, especially given the target lesion appearance of the nodules. Benign disease (nodular hyperplasia) cannot be ruled out but is considered less likely.
- **Left adrenal mass** – most consistent with a functional adrenal tumor, given the concurrently flat right adrenal gland with differentials including an adenoma as well as adenocarcinoma cannot be ruled out. Hyperplasia is possible but considered less likely, given the concurrently flat adrenal gland. An early pheochromocytoma is also possible but considered less likely.

## **SECONDARY FINDINGS**

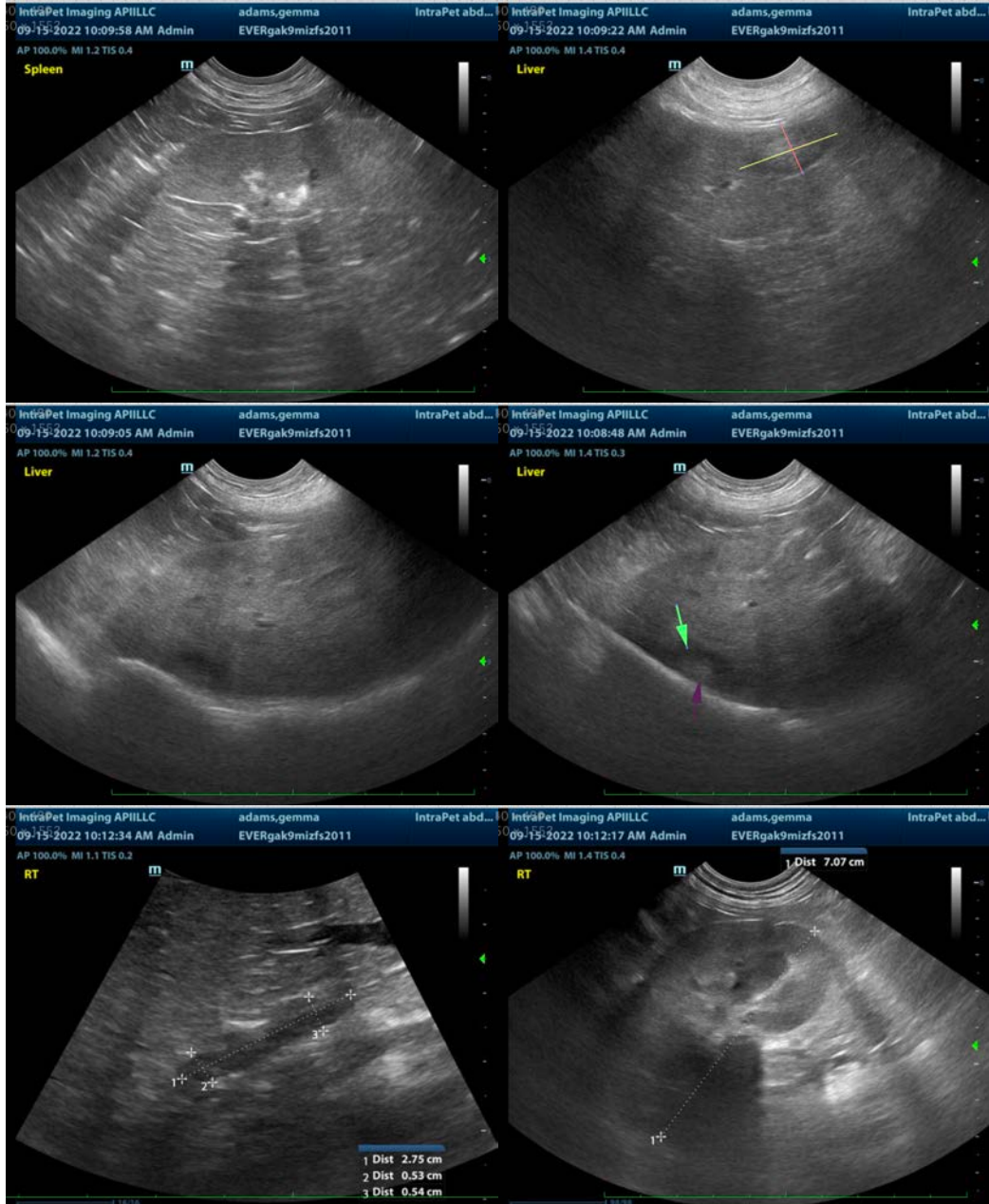
- **Hyperechoic splenic nodules** – most consistent with benign myelolipomas. Other differentials such as fibrosis or calcification caused by old hematomas or infarcts, chronic inflammation, granulomatous disease or metastatic disease cannot be ruled out, but are considered less likely.

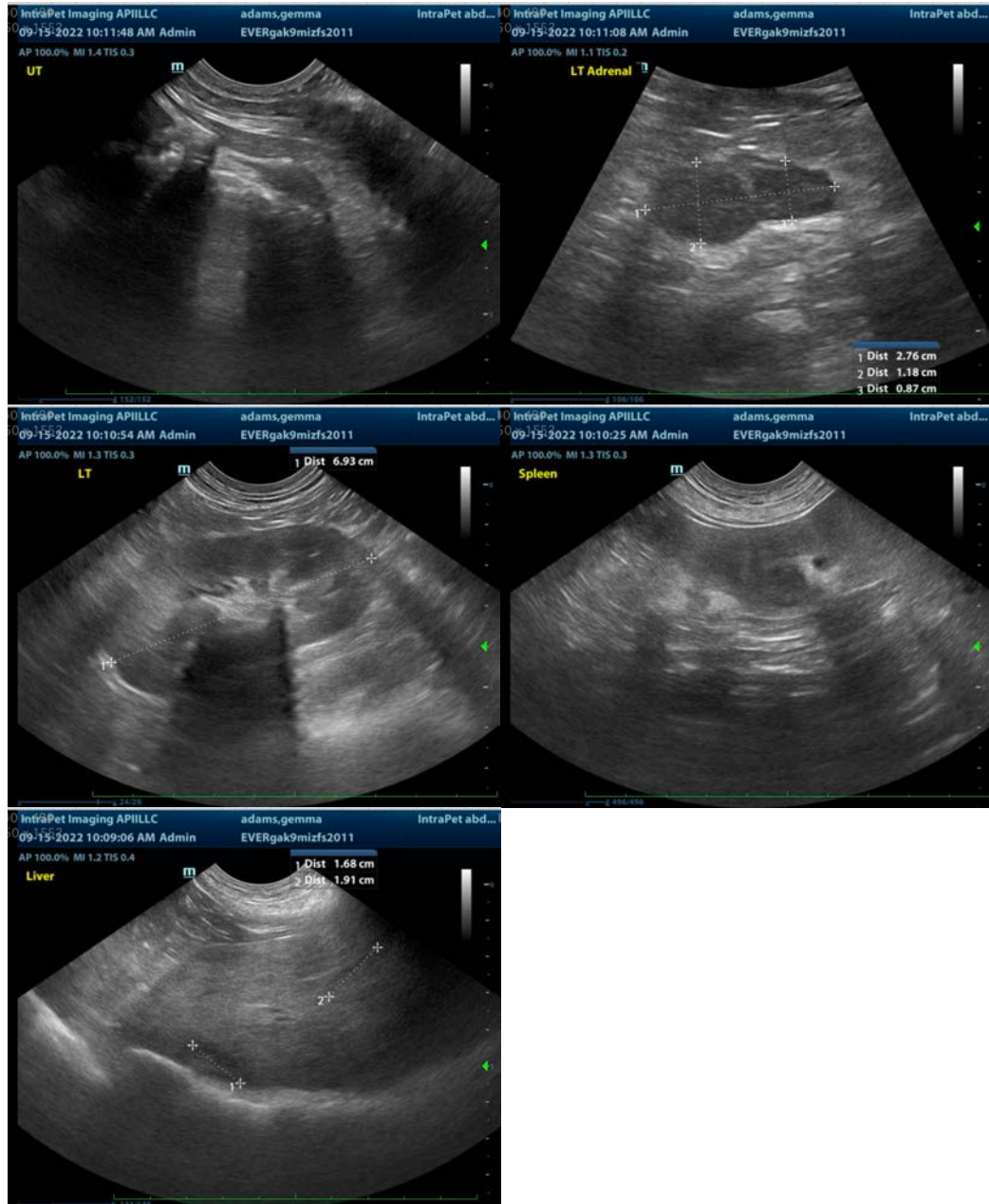
## **INTERPRETATION OF THE FINDINGS & FURTHER RECOMMENDATIONS**

Three view thoracic radiographs are recommended for further assessment of cardio-pulmonary status as well as to further evaluate for any evidence of metastatic disease, if not recently evaluated.

A fine needle aspirate of the liver nodules is recommended if patient's coagulation status is appropriate to look for evidence of infiltrative malignant or metastatic neoplasia.

The liver nodules appear to be the primary lesion of interest, and recommendations are to evaluate those as described above first. However, this patient's reported proteinuria and adrenal mass, etc. are likely consistent with hyperadrenocorticism. Therefore, adrenal hormone testing in the form of a low-dose Dexamethasone suppression test could be considered if clinical signs of hyperadrenocorticism such as polyuria, polydipsia, etc. are present. Regardless of whether clinical signs are present, a urine protein to creatinine ratio is recommended to further quantify the proteinuria and determine whether or not treatment is necessary. A blood pressure is recommended if not recently evaluated.





The information and recommendations provided are based on the images presented by the referring veterinarian/sonographer. No evaluation can be communicated regarding pathology that was not visible in the image/video clips provided.

Thank you for this referral. If the clinical or image interpretation does not parallel your findings or if I can be of any further assistance please contact me.

**Beth Johnson, DVM, DACVIM**  
Beth.Johnson@sonopath.com