

**DATE PRESENTING CLINICAL SIGNS**

9/15/22

History of gallop rhythm and mild hypertrophy and LA dilation on echo in 4/2019. No medications needed at that time. Thyroid disease diagnosed in January of 2022. Pet has been on methimazole, but owner noticed decreased appetite and weight loss of 4 pounds over the past few months. Labs yesterday showed mild liver value elevations and early renal; pet had been off methimazole for 3 days. Currently no gallop ausculted; 1/6 systolic PMI L apex.

PATIENT

Fergus Holthouse

SPECIES

Feline

Current Medications: methimazole 1.25 mg BID

Lab Results: 9/13/22 ALT 105, ALKP 202, amyl 1722, CPK 1052, T4 3.9, SG 1.011, 2+ protein. 3/24/22 BUN 51, T4 1.8

BREED

DSH

Date of Previous IntraPet Ultrasound: No previous.

Sedation: Patient sedated with Gabapentin & Torbugesic.

Stat Report: Not requested.

SEX

Neutered Male

ULTRASONOGRAPHIC EXAMINATION OF THE ABDOMEN**Urinary System**

The urinary bladder is moderately distended with anechoic contents. No masses, inflammatory changes, echogenic sediment or cystoliths are observed. The urinary bladder, trigone and visible pelvic urethra are normal in thickness with a smooth mucosal surface.

AGE

6/1/04

Kidneys are bilaterally irregular and diffusely echogenic with decreased corticomedullary distinction and poor visualization of internal architecture. No mineral is observed. The left kidney is small in size (2.81 cm). The right kidney is normal in size (3.47 cm). Moderate to severe pyelectasia is noted bilaterally, measuring 0.90 cm in the transverse view on the left kidney and 0.60 cm in the transverse view on the right kidney.

WEIGHT

12.94 Pounds

INTERPRETED BYBeth Johnson, DVM
DACVIM**Adrenal Glands**

The areas of the adrenal glands are examined without evident pathology.

IMAGING PERFORMED BY

Andi Parkinson RDMS

Spleen

Spleen is subjectively large in size with subtly scalloped or undulating capsular contour. Parenchyma is normal in echogenicity with a mildly coarse/heterogenous echotexture, characterized by multiple nodules/masses throughout the spleen. Splenic vasculature appears normal.

HOSPITAL NAME

Everhart Vet Hospital

Liver

The liver is subjectively normal in size with normal smooth curvilinear peripheral contour. Parenchyma is appropriately hypoechoic to the spleen in echogenicity and appropriately mildly coarse and homogenous in echotexture. A 3.0 cm x 5.0 cm heterogeneous mass is noted in the left caudal liver. Visible vasculature and biliary tree appear normal without distension or congestion.

REFERRING VET

Dr. Notarangelo

The gallbladder is non-distended in size. The wall is smooth without visible thickening. Luminal contents are primarily anechoic. There is no evidence of cystic or common bile duct dilation.

INVOICE

41381

Gastrointestinal

The stomach wall is normal in thickness (canine < 0.5 cm and feline < 0.4 cm) and layering. The lumen of the stomach is empty with no evidence of obstruction, foreign material or infiltrative disease. Pyloric outflow tract appears patent.

The visible small intestines are normal in wall thickness and layering (canine duodenum < 0.5 cm and feline duodenum < 0.4 cm; other < 0.3 cm). Small intestinal motility appears adequate (1-3 contractions per min).

The lumen of the small intestine is empty with no evidence of obstruction, foreign material or infiltrative disease.

The visible colon is normal in wall thickness (< 0.2 cm) and layering. Contents are consistent with normal formed feces and gas.

Pancreas

The pancreatic parenchyma is appropriately isoechoic to surrounding tissue. Visible capsule is smooth and normal in contour. There is no visible pancreatic duct dilation. There is no evidence of active peripancreatic inflammation.

Free Abdomen

There is no evidence of free peritoneal effusion noted in these images.

There is no apparent lymphadenopathy noted in these images.

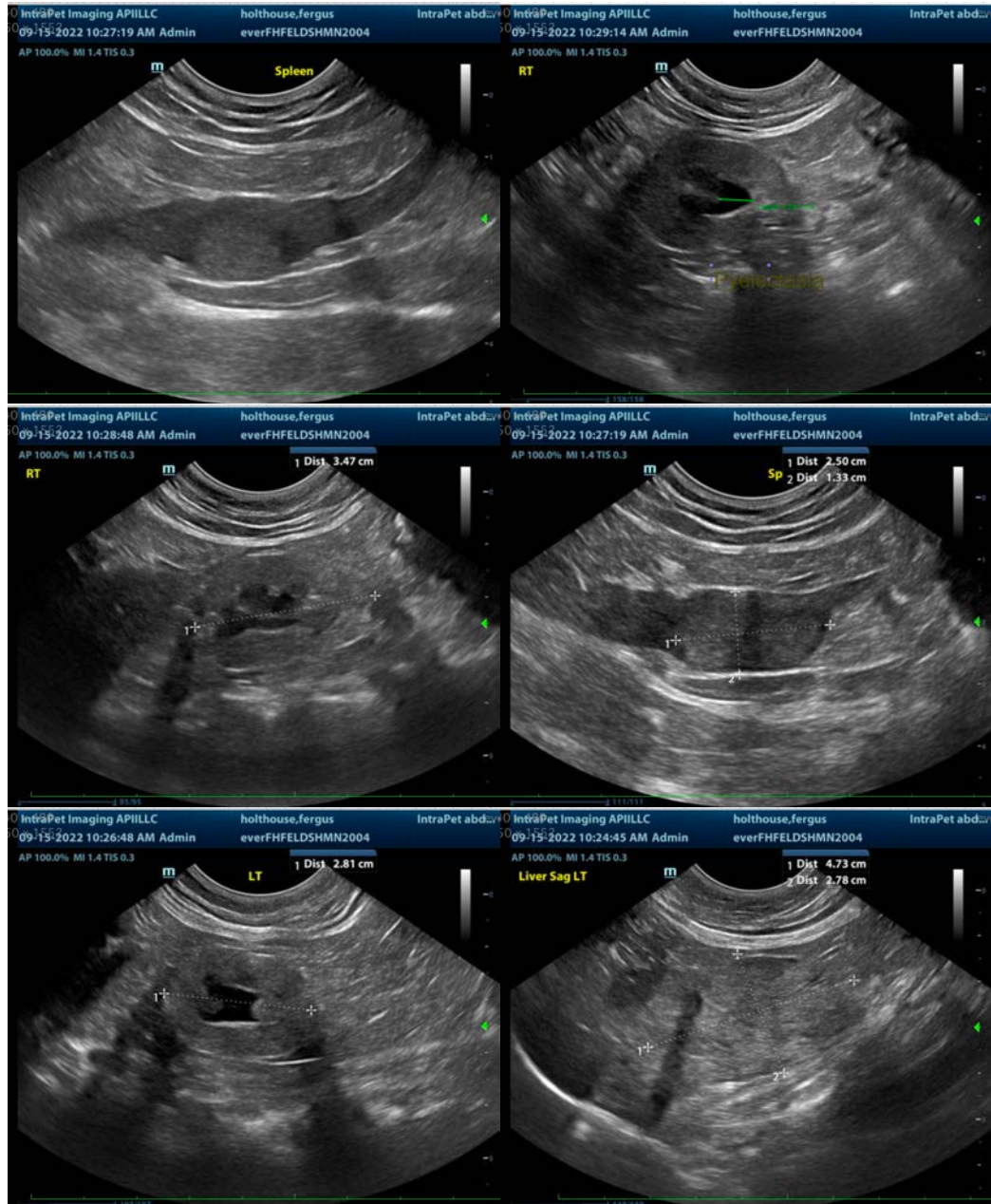
ULTRASONOGRAPHIC FINDINGS

- **Scalloped/Undulating spleen due to the presence of nodules/masses disrupting contour** - most concerning for infiltrative round cell neoplasia such as lymphoma or mast cell tumor. Benign inflammatory disease cannot be definitively ruled out, but given the concurrent liver pathology, infiltrative neoplasia is considered most likely.
- **Heterogeneous liver mass** – concerning for infiltrative malignant neoplasia such as round cell neoplasia or potentially metastatic neoplasia, given the concurrent splenic lesions. Primary liver tumor is possible, but these are rare in cats. A benign lesion such as a biliary cystadenoma is also possible but again considered less likely, given the concurrent splenic pathology.
- **Chronic Kidney Disease with bilateral pyelectasia** – This appearance of the kidneys is consistent with chronic kidney disease such as chronic glomerular or interstitial nephritis, chronic pyelonephritis, etc.

INTERPRETATION OF THE FINDINGS & FURTHER RECOMMENDATIONS

Three view thoracic radiographs are recommended for further assessment of cardio-pulmonary status as well as to further evaluate for any evidence of metastatic disease, if not recently evaluated.

A fine needle aspirate of the spleen and the liver mass are recommended if patient's coagulation status is appropriate. Additionally, given the kidney changes and reported proteinuria, a blood pressure is recommended if not recently evaluated, as is a urine protein to creatinine ratio to help further dictate appropriate therapy of the kidney disease.



The information and recommendations provided are based on the images presented by the referring veterinarian/sonographer. No evaluation can be communicated regarding pathology that was not visible in the image/video clips provided.

Thank you for this referral. If the clinical or image interpretation does not parallel your findings or if I can be of any further assistance please contact me.

Beth Johnson, DVM, DACVIM
 Beth.Johnson@sonopath.com