



**PATIENT**

Baylor Robbins

**PRESENTING CLINICAL SIGNS**

Recently had symptoms of gastroenteritis. Radiographs taken showed hepatomegaly.

**SPECIES**

Canine

Abnormal PE/Chem/CBC/UA Results: ALKP 779 (23-212)

**ULTRASONOGRAPHIC EXAMINATION OF THE ABDOMEN**

**Urinary System**

**BREED**

Lab X

Urinary bladder is adequately distended. It has a normal uniform wall thickness. Contents include primarily anechoic fluid with occasional echogenic non-shadowing debris, most consistent with exfoliated cells, mucous and/or small blood clots. Both sterile inflammation as well as urinary tract infection can also present with echogenic debris. No masses or cystoliths are observed. The trigone and visible pelvic urethra are normal in thickness with a smooth mucosal surface.

**SEX**

Neutered Male

The area of the prostate is examined without evident pathology.

**AGE**

11 Years

Kidneys are overall normal in size and shape with smooth peripheral margination. A normal 1:3 cortex to medulla ratio is maintained. The medulla and cortices are uniform in texture with some mild increased cortical echogenicity and mild loss of corticomedullary distinction, expected in this age patient. There is no evidence of pyelectasia, mineral or infarcts observed. The left kidney measures 6.25 cm. The right kidney measures 8.93 cm.

**WEIGHT**

93.4 Pounds

**Adrenal Glands**

Adrenal glands are plump/swollen in size. Normal shape and contour are maintained without evidence of capsular invasion. Corticomedullary structure is unremarkable. Visible surrounding vasculature appears normal. The left adrenal gland measures 0.86 cm at the cranial pole and 0.96 cm at the caudal pole. The right adrenal gland measures 1.7 cm at the cranial pole and 1.38 cm at the caudal pole.

**INTERPRETED BY**

Beth Johnson, DVM  
DACVIM

**Spleen**

The spleen is subjectively normal in size with a normal smooth capsular contour. Parenchyma is appropriately finely textured and homogenous with normal echogenicity relative to surrounding tissue (hyperechoic to liver). No focal nodules or masses are observed. Splenic vasculature appears normal.

**IMAGING PERFORMED BY**

Dr. Michelle Bartus

**Liver**

Liver is subjectively enlarged (swollen contour) without disruption of architecture. It has a normal homogenous echotexture. Parenchyma is diffusely hyperechoic characterized by less prominent than normal portal vein walls and increased echogenicity relative to the spleen and falciform fat. No focal lesions are observed. Visible vasculature and biliary tree appear normal without distension or congestion.

**HOSPITAL NAME**

Valley Vet Service

**REFERRING VET**

Dr. Michelle Bartus

Gallbladder is moderately distended with anechoic bile as well as suspended and gravity dependent echogenic debris. The wall is smooth without visible thickening. There is no evidence of cystic or CBD dilation. There is no evidence of effusion or inflammation.

**INVOICE**

41397

**Gastrointestinal**

The stomach wall is normal in thickness (canine < 0.5 cm and feline < 0.4 cm) and layering. The lumen of the stomach is empty with no evidence of obstruction, foreign material or infiltrative disease. Pyloric outflow tract appears patent.

**DATE**

9/15/22

The visible small intestines are normal in wall thickness and layering (canine duodenum < 0.5 cm and feline duodenum < 0.4 cm; other < 0.3 cm). Small intestinal motility appears adequate (1-3 contractions



**PATIENT**

Baylor Robbins

per min). The lumen of the small intestine is empty with no evidence of obstruction, foreign material or infiltrative disease.

The visible colon is normal in wall thickness (< 0.2 cm) and layering. Contents are consistent with normal formed feces and gas.

**SPECIES**

Canine

**Pancreas**

The pancreatic parenchyma is appropriately isoechoic to surrounding tissue. Visible capsule is smooth and normal in contour. There is no visible pancreatic duct dilation. There is no evidence of active peripancreatic inflammation.

**BREED**

Lab X

**Free Abdomen**

There is no evidence of free peritoneal effusion noted in these images.

**SEX**

Neutered Male

There is no apparent lymphadenopathy noted in these images.

**PRIMARY FINDINGS**

**AGE**

11 Years

- **Bilateral adrenomegaly** – consistent with adrenal hyperplasia secondary to pituitary dependent hyperadrenocorticism vs stress or normal variant. Interpret in combination with clinical signs of hyperadrenocorticism.

**WEIGHT**

93.4 Pounds

- **Hyperechoic hepatomegaly** - This appearance is non-specific and most consistent with a benign steroid (endocrine) or vacuolar hepatopathy or reactive or idiopathic hepatopathy. Inflammatory and/or infiltrative disease (such as round cell neoplasia) are also possible, but considered less likely.

**INTERPRETED BY**

Beth Johnson, DVM  
DACVIM

- **Gallbladder debris** - Cholecystic debris is of unknown clinical significance. It can be seen with biliary stasis from fasting or illness. Cholecystic debris is not necessarily related to hepatobiliary disease. Echogenic bile is most commonly an incidental finding in dogs and should be interpreted in combination with clinical signs such as nausea, inappetence, cranial abdominal discomfort and/or laboratory changes such as increased ALP and/or increased Tbili.

**IMAGING PERFORMED BY**

Dr. Michelle Bartus

**SECONDARY FINDINGS**

- Urinary bladder debris
- Age related kidney changes

**HOSPITAL NAME**

Valley Vet Service

**INTERPRETATION OF THE FINDINGS & FURTHER RECOMMENDATIONS**

The described adrenal gland, liver and gallbladder changes are all suggestive of hyperadrenocorticism. If clinical signs of hyperadrenocorticism, such as polyuria, polydipsia, polyphagia, panting, hair loss, hypertension, etc. are present, testing for hyperadrenocorticism with a LDDS test is warranted. If a LDDS test has been evaluated with a normal result, investigation of possible atypical hyperadrenocorticism with a full ACTH stimulation adrenal panel to the University of Tennessee could be considered. If clinical signs are not present, monitoring is recommended with testing pursued when/if clinical signs develop. If not recently evaluated, blood pressure is recommended. If not recently evaluated, a urinalysis and, if indicated based on urinalysis results, urine culture are also recommended. If protein is present in an otherwise quiet sediment, protein quantification with a urine protein to creatinine ratio is recommended.

**REFERRING VET**

Dr. Michelle Bartus

**INVOICE**

41397

**DATE**

9/15/22

There are no ultrasonographic reasons to explain this patient's recent episode of gastroenteritis. If gastroenteritis persists and/or returns, further evaluation of the GI tract could be pursued with a



**PATIENT**

Baylor Robbins

gastrointestinal malabsorption panel (including cobalamin, folate, TLI and PLI) to Texas A&M GI Laboratory for further evaluation of GI and pancreatic function, as well as a fecal exam, followed by empirical deworming with a 5-day course of Panacur +/- transition to a hydrolyzed protein diet.

**SPECIES**

Canine

**BREED**

Lab X

**SEX**

Neutered Male

**AGE**

11 Years

**WEIGHT**

93.4 Pounds

**INTERPRETED BY**

Beth Johnson, DVM  
DACVIM

**IMAGING PERFORMED BY**

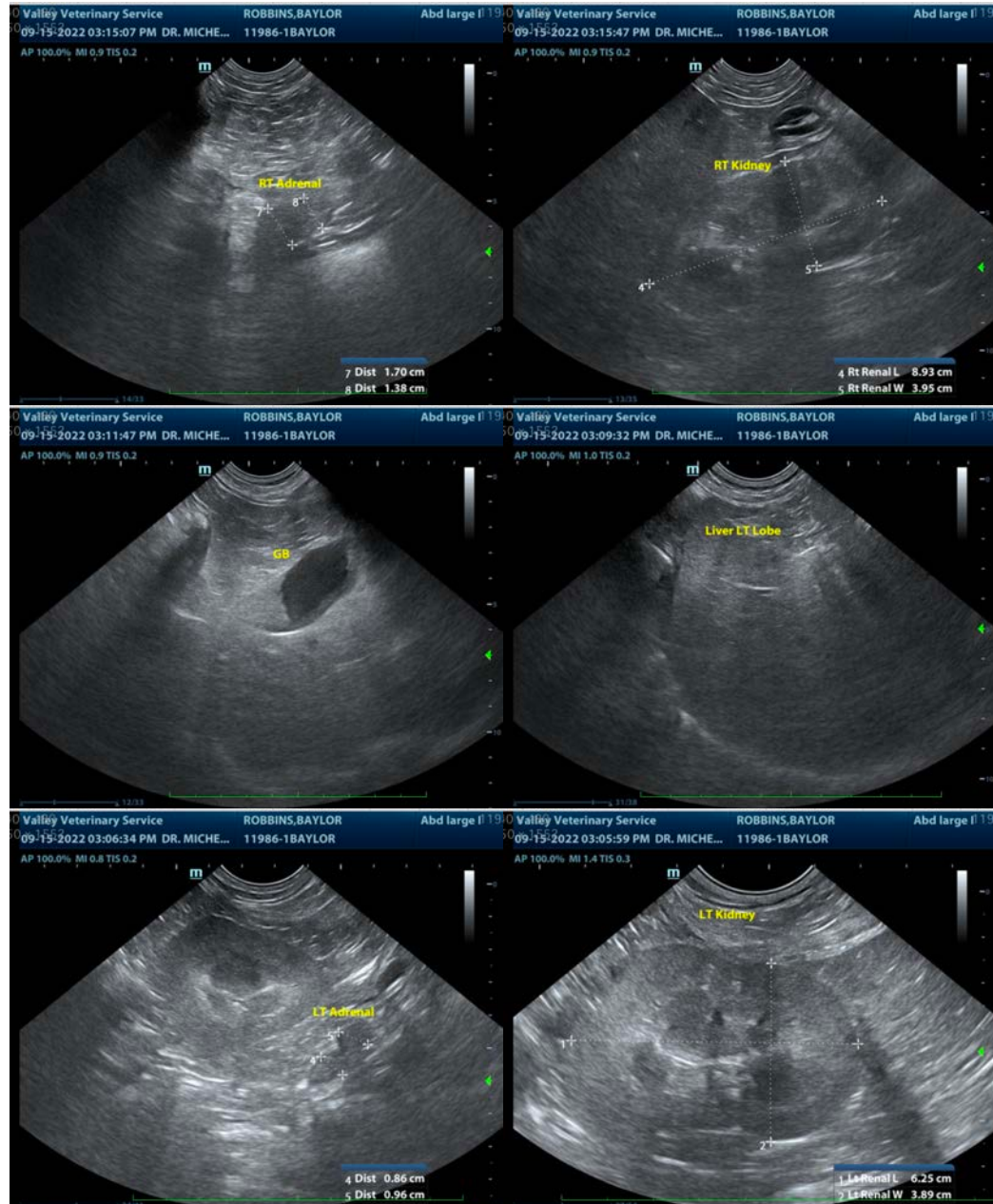
Dr. Michelle Bartus

**HOSPITAL NAME**

Valley Vet Service

**REFERRING VET**

Dr. Michelle Bartus



**INVOICE**

41397

**DATE**

9/15/22



**PATIENT**

Baylor Robbins

**SPECIES**

Canine

**BREED**

Lab X

**SEX**

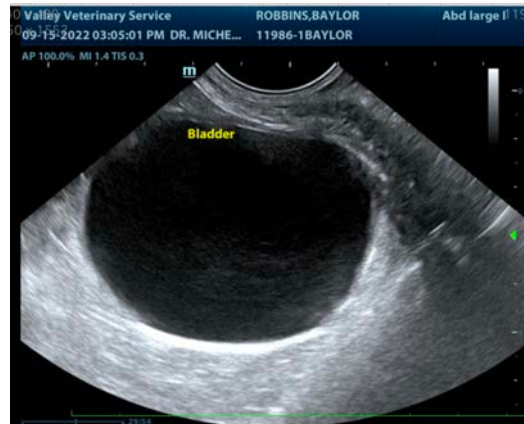Neutered Male

**AGE**

11 Years

**WEIGHT**

93.4 Pounds



The information and recommendations provided are based on the images presented by the referring veterinarian/sonographer. No evaluation can be communicated regarding pathology that was not visible in the image/video clips provided.

Thank you for this referral. If the clinical or image interpretation does not parallel your findings or if I can be of any further assistance please contact me.

**Beth Johnson, DVM, DACVIM**  
Beth.Johnson@sonopath.com

**INTERPRETED BY**

Beth Johnson, DVM  
DACVIM

**IMAGING PERFORMED BY**

Dr. Michelle Bartus

**HOSPITAL NAME**

Valley Vet Service

**REFERRING VET**

Dr. Michelle Bartus

**INVOICE**

41397

**DATE**

9/15/22