



<b>PATIENT</b>	<b>PRESENTING CLINICAL SIGNS</b>
Sylvia Hildebrandt	Losing weight over the past 6-8 months. Weight loss of 3 lbs over the past year without change in appetite, and no reported vomiting or change in BM. Eats both dry and canned OTC diet. Occasionally regurgitates after rapid eating. Indoor-only cat. On Laxaire supplement to prevent hairballs and constipation - well-controlled, normal BM's.
<b>SPECIES</b>	
Feline	Abnormal PE/Chem/CBC/UA Results: 9/9/2022: PE normal aside from a BCS of 2-3/9 with a poor muscle condition of 1/3 (epaxial, hindquarter, and temporal muscle wasting). CBC/Chem: Mild elevations in SDMA (16ug/dL), Crea (2.7mg/dL), and BUN (39mg/dL). Remainder WRI, including TT4. FeLV/FIV/Heartworm SNAP negative. 9/14/2022: Three-view thoracic rads - no metastatic/miliary/micronodular pattern noted pulmonary parenchyma. Cardiac silhouette and vasculature WNL. Multifocal mineralized foci apparent in left kidney.
<b>BREED</b>	
DSH	
<b>SEX</b>	<b>ULTRASONOGRAPHIC EXAMINATION OF THE ABDOMEN</b>
Spayed Female	<b>Urinary System</b>
	The urinary bladder is moderately distended with anechoic contents. No masses, inflammatory changes, echogenic sediment or cystoliths are observed. The urinary bladder, trigone and visible pelvic urethra are normal in thickness with a smooth mucosal surface.
<b>AGE</b>	
13 Years	Kidneys are bilaterally uniformly enlarged/swollen with an overall hyperechoic echogenicity and slight loss of corticomedullary definition. Normal smooth peripheral margination and shape are maintained. The renal pelvises are dilated with anechoic fluid and hyperechoic thickened pelvic fat. No overt evidence of neoplasia. The perinephric area is enhanced by hyperechoic fat and mesentery. Non-obstructive areas of mineralization/nephroliths are noted in both kidneys. The left kidney measures 3.04 cm. The right kidney measures 3.95 cm.
<b>WEIGHT</b>	
8.3 Pounds	
<b>INTERPRETED BY</b>	<b>Adrenal Glands</b>
Beth Johnson, DVM DACVIM	The right adrenal gland is normal in size (0.49 cm), shape and contour. Corticomedullary structure is unremarkable. Visible surrounding vasculature appears normal.
<b>IMAGING PERFORMED BY</b>	The left adrenal gland is normal in size (0.23 cm), shape and contour. Corticomedullary structure is unremarkable. Visible surrounding vasculature appears normal.
Dr. Bethany Coe	<b>Spleen</b>
<b>HOSPITAL NAME</b>	The spleen is subjectively normal in size with a normal smooth capsular contour. Parenchyma is appropriately finely textured and homogenous with normal echogenicity relative to surrounding tissue (hyperechoic to liver). No focal nodules or masses are observed. Splenic vasculature appears normal.
Riverside AC	<b>Liver</b>
<b>REFERRING VET</b>	The liver is subjectively normal in size with normal smooth curvilinear peripheral contour. Parenchyma is appropriately hypoechoic to the spleen in echogenicity and appropriately mildly coarse and homogenous in echotexture. No focal lesions are observed. Visible vasculature and biliary tree appear normal without distension or congestion.
Dr. Bethany Coe	
<b>INVOICE</b>	The gallbladder is non-distended in size. The wall is smooth without visible thickening. Luminal contents are primarily anechoic. There is no evidence of cystic or common bile duct dilation.
41323	
<b>DATE</b>	
9/14/22	



<b>PATIENT</b>	<b><i>Gastrointestinal</i></b>
Sylvia Hildebrandt	The stomach wall is normal in thickness (canine < 0.5 cm and feline < 0.4 cm) and layering. The lumen of the stomach is empty with no evidence of obstruction, foreign material or infiltrative disease. Pyloric outflow tract appears patent.
<b>SPECIES</b>	
Feline	The visible small intestines are normal in wall thickness and layering (canine duodenum < 0.5 cm and feline duodenum < 0.4 cm; other < 0.3 cm). Small intestinal motility appears adequate (1-3 contractions per min). The lumen of the small intestine is empty with no evidence of obstruction, foreign material or infiltrative disease.
<b>BREED</b>	
DSH	The visible colon is normal in wall thickness (< 0.2 cm) and layering. Contents are consistent with normal formed feces and gas.
<b>SEX</b>	<b><i>Pancreas</i></b>
Spayed Female	The observed pancreas is prominent (enlarged) in size, hypoechoic to surrounding tissue and irregular in shape with a swollen undulating contour. Pancreatic duct dilation is noted. Enhanced hyperechoic ill-defined surrounding fat is noted. (See other).
<b>AGE</b>	<b><i>Free Abdomen</i></b>
13 Years	In the mid right abdomen, there is a non-discrete area of markedly enhanced hyperechoic fat and mesentery in the area of the right limb of the pancreas.
<b>WEIGHT</b>	
8.3 Pounds	There is no evidence of free peritoneal effusion noted in these images. There is no apparent lymphadenopathy noted in these images.
<b>INTERPRETED BY</b>	<b>ULTRASONOGRAPHIC FINDINGS</b>
Beth Johnson, DVM DACVIM	<ul style="list-style-type: none"> <li>• <b>Pyelonephritis</b> – These changes are most consistent with chronic pyelonephritis. Chronic scarring and fibrosis and/or chronic nephrolith passage can also result in these pelvic dilation changes. Early infiltrative disease cannot be ruled out but is considered less likely.</li> <li>• Acute pancreatitis is suspected based on the non-discrete changes suggestive of inflammation in the mid right abdomen because the enhanced fat and mesentery surrounds the area of the right limb of the pancreas. However, the area around the right kidney also appears to be inflamed, and so the changes may all be perinephric versus concurrent pancreatitis.</li> </ul>
<b>IMAGING PERFORMED BY</b>	<b><u>INTERPRETATION OF THE FINDINGS &amp; FURTHER RECOMMENDATIONS</u></b>
Dr. Bethany Coe	A urine culture is recommended, given this patient's suspicion for pyelonephritis. Pending results of a urinary bladder cystocentesis, direct sampling of the right renal pelvis with ultrasound guided pyelocentesis for cytology and culture could also be considered if a representative sample cannot be obtained via cystocentesis.
<b>HOSPITAL NAME</b>	
Riverside AC	A blood pressure is recommended if not recently evaluated.
<b>REFERRING VET</b>	
Dr. Bethany Coe	
<b>INVOICE</b>	Given the reported weight loss with a reportedly normal appetite and the possible pancreatic changes, A gastrointestinal malabsorption panel (including cobalamin, folate, TLI and PLI) to Texas A&M GI Laboratory is recommended for further evaluation of GI and pancreatic function.
41323	
<b>DATE</b>	In the meantime, supportive/symptomatic management of this patient's clinical signs and suspected pyelonephritis is recommended in the form of fluid therapy if clinical hydration status supports the need for fluid therapy, broad-spectrum antibiotics, as well as gastrointestinal support in the form of
9/14/22	



**PATIENT**

Sylvia Hildebrandt

antiemetics +/- an appetite stimulant in case the patient's appetite is not quite as normal as suspected, resulting in the reported weight loss.

**SPECIES**

Feline

**BREED**

DSH

**SEX**

Spayed Female

**AGE**

13 Years

**WEIGHT**

8.3 Pounds

**INTERPRETED BY**

Beth Johnson, DVM  
DACVIM

**IMAGING PERFORMED BY**

Dr. Bethany Coe

**HOSPITAL NAME**

Riverside AC

**REFERRING VET**

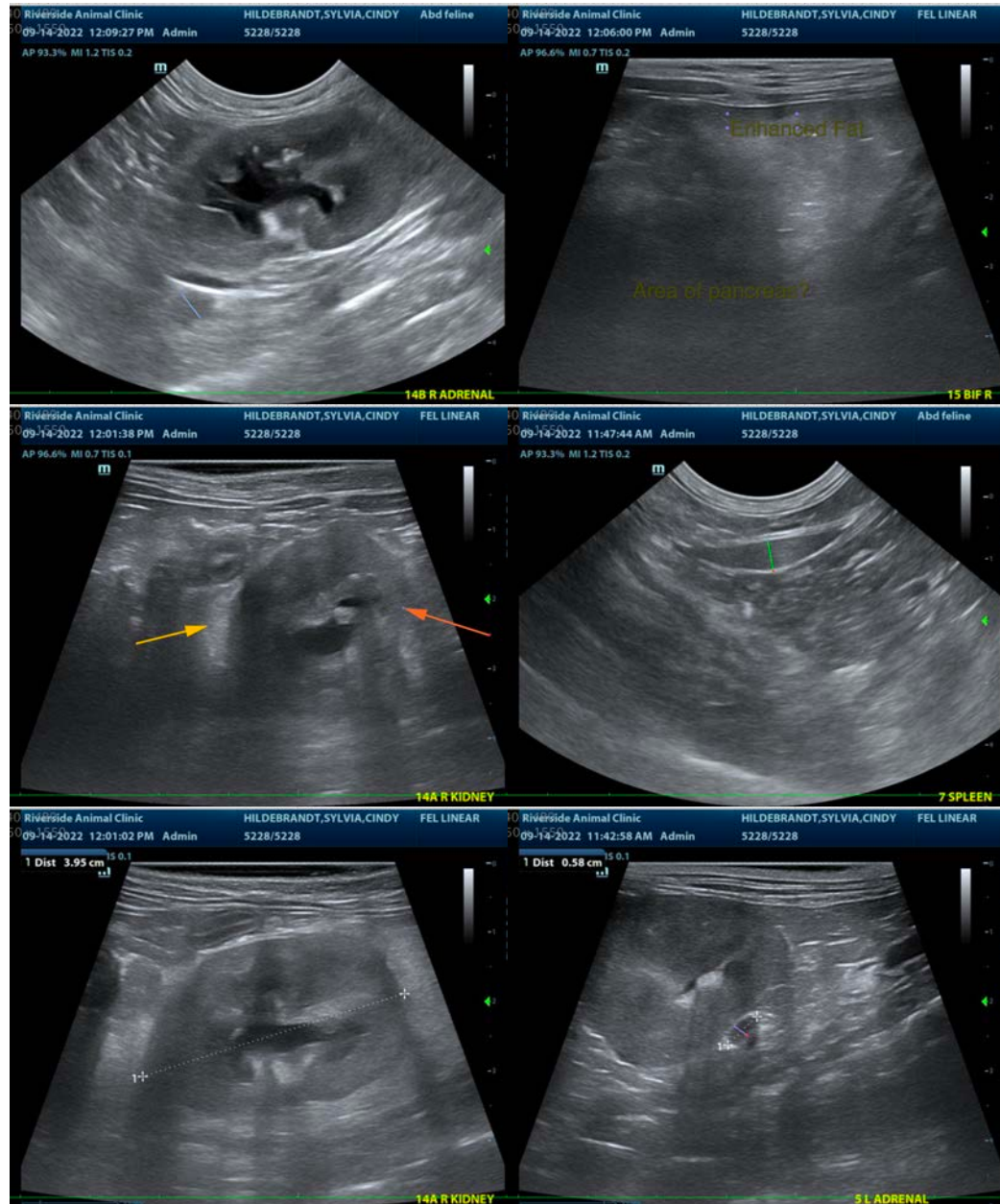
Dr. Bethany Coe

**INVOICE**

41323

**DATE**

9/14/22





**PATIENT**

Sylvia Hildebrandt

**SPECIES**

Feline

**BREED**

DSH

**SEX**

Spayed Female

**AGE**

13 Years

**WEIGHT**

8.3 Pounds

**INTERPRETED BY**

Beth Johnson, DVM  
DACVIM

**IMAGING  
PERFORMED BY**

Dr. Bethany Coe

**HOSPITAL NAME**

Riverside AC

**REFERRING VET**

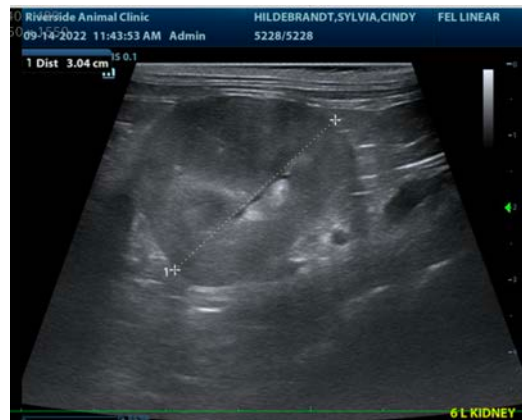Dr. Bethany Coe

**INVOICE**

41323

**DATE**

9/14/22



The information and recommendations provided are based on the images presented by the referring veterinarian/sonographer. No evaluation can be communicated regarding pathology that was not visible in the image/video clips provided.

Thank you for this referral. If the clinical or image interpretation does not parallel your findings or if I can be of any further assistance please contact me.

**Beth Johnson, DVM, DACVIM**  
Beth.Johnson@sonopath.com