



**PATIENT**

Chloe Rotondi

**PRESENTING CLINICAL SIGNS**

Vomiting, diarrhea, decreased appetite. Current meds: famotidine, cerenia, metro, entyce.

**SPECIES**

Canine

Abnormal PE/Chem/CBC/UA Results: Elevated BUN/neutrophils/globulins.

**BREED**

Yorkshire Terrier

**ULTRASONOGRAPHIC EXAMINATION OF THE ABDOMEN**

**Urinary System**

Urinary bladder is adequately distended. It has a normal uniform wall thickness. Contents include primarily anechoic fluid with occasional echogenic non-shadowing debris, most consistent with exfoliated cells, mucous and/or small blood clots. Both sterile inflammation as well as urinary tract infection can also present with echogenic debris. No masses or cystoliths are observed. The trigone and visible pelvic urethra are normal in thickness with a smooth mucosal surface.

**SEX**

Spayed Female

Kidneys are overall normal in size and shape with smooth peripheral margination. A normal 1:3 cortex to medulla ratio is maintained. The medulla and cortices are uniform in texture with some mild increased cortical echogenicity and mild loss of corticomedullary distinction, expected in this age patient. There is no evidence of infarcts observed. The left kidney measured 3.41 cm. The right kidney measures 3.87 cm. Non-obstructive areas of mineralization/nephroliths are noted in both kidneys. Mild pyelectasia noted in both kidneys.

**AGE**

14 Years

**WEIGHT**

10.1 Pounds

**Adrenal Glands**

The right adrenal gland is normal in size (1.26 cm long x 0.75 cm at the cranial pole and 0.63 cm at the caudal pole), shape and contour. Corticomedullary structure is unremarkable. Visible surrounding vasculature appears normal.

**INTERPRETED BY**

Beth Johnson, DVM  
DACVIM

The left adrenal gland is normal in size (1.67 cm long x 0.54 cm at the cranial pole and 0.48 cm at the caudal pole), shape and contour. Corticomedullary structure is unremarkable. Visible surrounding vasculature appears normal.

**Spleen**

**IMAGING PERFORMED BY**

Kelly Vazquez

Spleen is subjectively normal in size with a normal smooth capsular contour. Parenchyma is appropriately finely textured and homogenous with normal echogenicity relative to surrounding tissue (hyperechoic to liver). Multifocal well-demarcated hyperechoic homogenous nodules are noted. Splenic vasculature appears normal.

**HOSPITAL NAME**

Animal General  
on the Hudson

**Liver**

Liver is subjectively enlarged with mildly irregular margins. Parenchyma is heterogenous characterized by multiple poorly defined hypoechoic nodules within otherwise hyperechoic liver parenchyma. Visible vasculature and biliary tree appear normal without distension or congestion.

**REFERRING VET**

Dr. Vivian Ng

The gallbladder is non-distended in size. The wall is smooth without visible thickening. Luminal contents are primarily anechoic. There is no evidence of cystic or common bile duct dilation.

**INVOICE**

41337

**Gastrointestinal**

The visible stomach wall is normal in thickness and layering. The lumen of the stomach is mildly distended with echogenic non-shadowing luminal contents and gas consistent with normal ingesta.

**DATE**

9/14/22

There is no evidence of obstruction or foreign material. An approximately 1-1.5 cm in diameter hypoechoic mucosal lesion is noted, appearing to extend from the greater curvature body area of the stomach into the lumen. Pyloric outflow tract appears patent.



**PATIENT**

Chloe Rotondi

The visible small intestines are normal in wall thickness and layering. Small intestinal motility appears adequate (1-3 contractions per min). The lumen of the small intestine is mildly distended with echogenic non-shadowing luminal contents and gas consistent with normal ingesta. There is no evidence of obstruction, foreign material or infiltrative disease.

**SPECIES**

Canine

The visible colon is normal in wall thickness (< 0.2 cm) and layering. Contents are consistent with normal formed feces and gas.

**Pancreas**

**BREED**

Yorkshire Terrier

The pancreatic parenchyma is appropriately isoechoic to surrounding tissue. Visible capsule is smooth and normal in contour. There is no visible pancreatic duct dilation. There is no evidence of active peripancreatic inflammation.

**SEX**

Spayed Female

**Free Abdomen**

There is no evidence of free peritoneal effusion noted in these images.

There is no apparent lymphadenopathy noted in these images.

**AGE**

14 Years

**PRIMARY FINDINGS**

- **Hypoechoic gastric mucosal lesion** – differentials include both a benign polyp as well as a malignant neoplasia.
- **Heterogenous Liver** – These changes are most consistent with benign processes such as nodular hyperplasia, steroid (vacuolar) hepatopathy, extramedullary hematopoiesis or possibly chronic inflammatory disease and less commonly infiltrative round cell or metastatic neoplasia.

**WEIGHT**

10.1 Pounds

**SECONDARY FINDINGS**

- **Hyperechoic splenic nodules** – most consistent with benign myelolipomas. Other differentials such as fibrosis or calcification caused by old hematomas or infarcts, chronic inflammation, granulomatous disease or metastatic disease cannot be ruled out, but are considered less likely.
- Urinary bladder debris

**INTERPRETED BY**

Beth Johnson, DVM  
DACVIM

**INTERPRETATION OF THE FINDINGS & FURTHER RECOMMENDATIONS**

Three view thoracic radiographs are recommended for further assessment of cardio-pulmonary status as well as to further evaluate for any evidence of metastatic disease, if not recently evaluated.

**IMAGING PERFORMED BY**

Kelly Vazquez

Tissue sampling of the gastric lesion is recommended. If it can safely be reached, a fine needle aspirate of the nodule could be considered if patient's coagulation status is appropriate, or gastroscopy could be considered for biopsy.

**HOSPITAL NAME**

Animal General  
on the Hudson

**REFERRING VET**

Dr. Vivian Ng

Alternatively, an exploratory laparotomy could be considered for a complete excisional biopsy to both diagnose and remove the structure. The lesion does not appear overtly obstructive. Therefore, the gastrointestinal signs may be related to a concurrent gastritis/microulceration, etc., so in the meantime, empirical management of possible gastritis/gastroenteritis with antiemetics and gastroprotectants including an antacid and sucralfate may be helpful to alleviate clinical signs.

**INVOICE**

41337

**DATE**

9/14/22



**PATIENT**

Chloe Rotondi

**SPECIES**

Canine

**BREED**

Yorkshire Terrier

**SEX**

Spayed Female

**AGE**

14 Years

**WEIGHT**

10.1 Pounds

**INTERPRETED BY**

Beth Johnson, DVM  
DACVIM

**IMAGING PERFORMED BY**

Kelly Vazquez

**HOSPITAL NAME**

Animal General  
on the Hudson

**REFERRING VET**

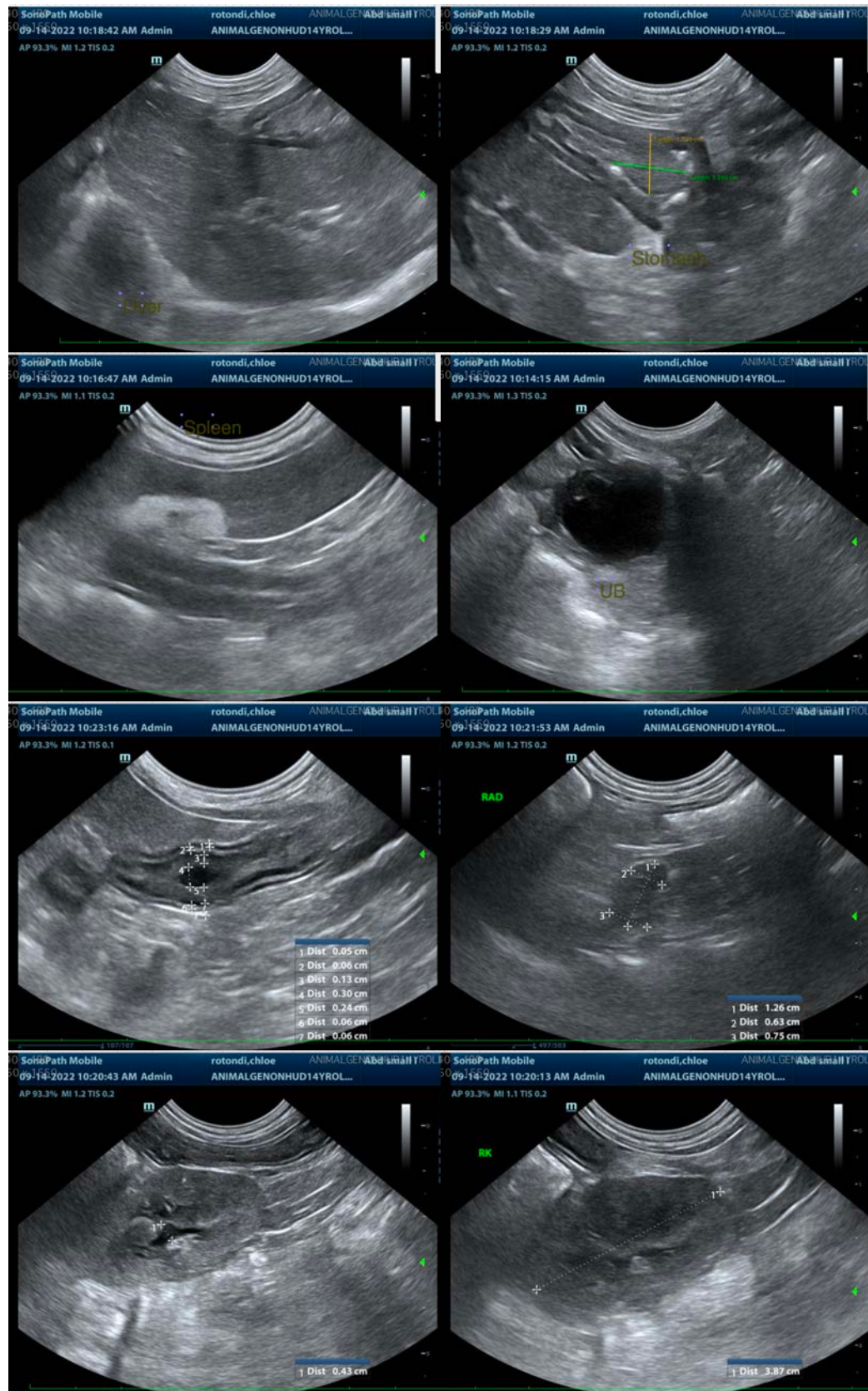
Dr. Vivian Ng

**INVOICE**

41337

**DATE**

9/14/22





**PATIENT**

Chloe Rotondi

**SPECIES**

Canine

**BREED**

Yorkshire Terrier

**SEX**

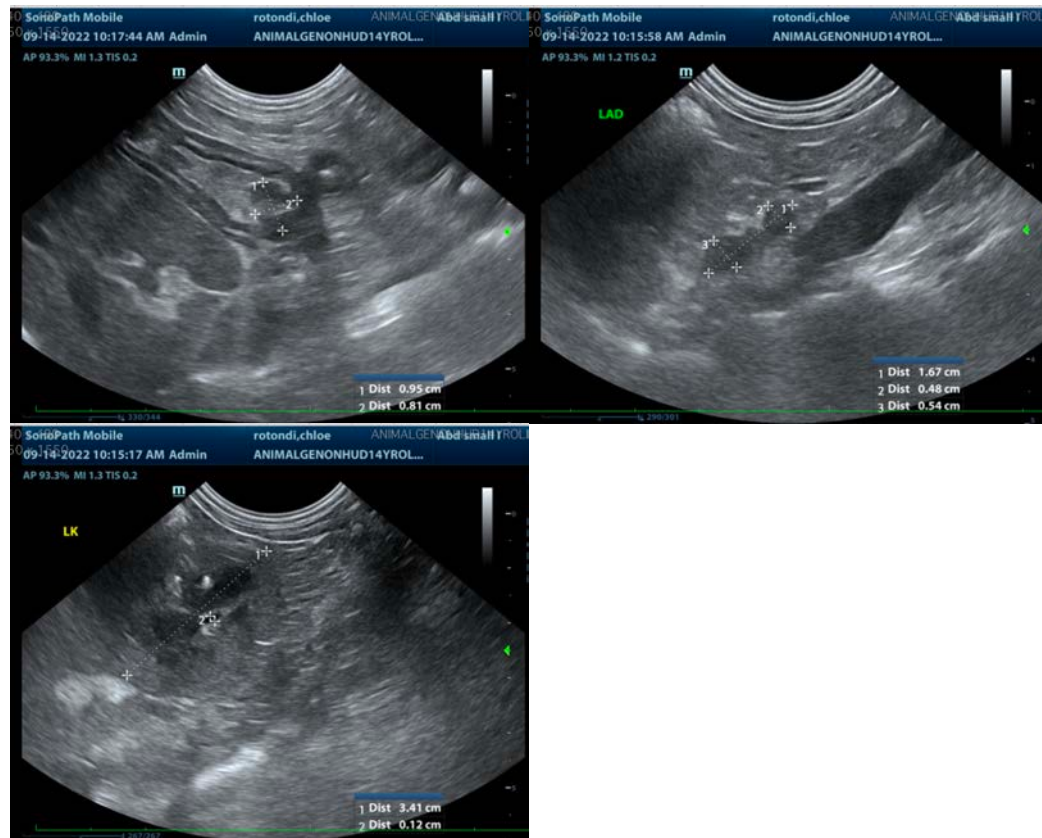
Spayed Female

**AGE**

14 Years

**WEIGHT**

10.1 Pounds



**INTERPRETED BY**

Beth Johnson, DVM  
DACVIM

**IMAGING PERFORMED BY**

Kelly Vazquez

**HOSPITAL NAME**

Animal General  
on the Hudson

**REFERRING VET**

Dr. Vivian Ng

**INVOICE**

41337

**DATE**

9/14/22

The information and recommendations provided are based on the images presented by the referring veterinarian/sonographer. No evaluation can be communicated regarding pathology that was not visible in the image/video clips provided.

Thank you for this referral. If the clinical or image interpretation does not parallel your findings or if I can be of any further assistance please contact me.

**Beth Johnson, DVM, DACVIM**  
Beth.Johnson@sonopath.com