



PATIENT

Wasabi Bustos

SPECIES

Canine

BREED

Terrier X

SEX

Neutered Male

AGE

8 Years

WEIGHT

41 Pounds

INTERPRETED BY

Beth Johnson, DVM
DACVIM

IMAGING PERFORMED BY

Dr. Amanda Favis

HOSPITAL NAME

Ruidoso AC

REFERRING VET

Dr. Amanda Favis

INVOICE

41282

DATE

9/13/22

PRESENTING CLINICAL SIGNS

Hx of myasthenia gravis and megaesophagus. In remission after dialysis for removal of ACHR antibodies and pyridostigmine/mycophenolate. Has been weaned off of mycophenolate and is still on pyridostigmine with a tapering dose.

Abnormal PE/Chem/CBC/UA Results: Ultrasound was requested because of the recent mild increase in hepatic enzymes - ALT 256, GGT 24, cholesterol 425, globulins - 4.1

ULTRASONOGRAPHIC EXAMINATION OF THE ABDOMEN

Urinary System

The urinary bladder is moderately distended with anechoic contents. No masses, inflammatory changes, echogenic sediment or cystoliths are observed. The urinary bladder, trigone and visible pelvic urethra are normal in thickness with a smooth mucosal surface.

Prostate is normal in size, echotexture and echogenicity for a neutered male.

The right kidney is normal in size (5.8 cm), shape and echogenicity. It has smooth peripheral margination. There is a normal 1:3 cortex to medulla ratio with appropriate corticomedullary distinction. There is no evidence of pyelectasia, mineral or infarcts observed.

The left kidney is normal in size (4.6 cm), shape and echogenicity. It has smooth peripheral margination. There is a normal 1:3 cortex to medulla ratio with appropriate corticomedullary distinction. There is no evidence of pyelectasia, mineral or infarcts observed.

Adrenal Glands

The areas of the adrenal glands are examined without evident pathology.

Spleen

The spleen is subjectively normal in size with a normal smooth capsular contour. Parenchyma is appropriately finely textured and homogenous with normal echogenicity relative to surrounding tissue (hyperechoic to liver). No focal nodules or masses are observed. Splenic vasculature appears normal.

Liver

Liver is normal to subjectively small in size with slightly undulating or scalloped capsular contour or margins. Parenchyma is diffusely heterogenous with increased portal markings and coarse architecture. No focal nodules or masses are observed. Visible vasculature and biliary tree appear normal without distension or congestion.

The gallbladder is non-distended in size. The wall is smooth without visible thickening. Luminal contents are primarily anechoic. There is no evidence of cystic or common bile duct dilation.

Gastrointestinal

The visible stomach wall is normal in thickness and layering. The lumen of the stomach is mildly distended with very echogenic reverberation artifact from intraluminal gas. There is no evidence of obstruction, foreign material or infiltrative disease; however, complete visualization of far wall is partially inhibited by gas. Pyloric outflow tract appears patent.

The visible small intestines are normal in wall thickness and layering (canine duodenum < 0.5 cm and feline duodenum < 0.4 cm; other < 0.3 cm). Small intestinal motility appears adequate (1-3 contractions



PATIENT

Wasabi Bustos

per min). The lumen of the small intestine is empty with no evidence of obstruction, foreign material or infiltrative disease.

SPECIES

Canine

The visible colon is normal in wall thickness (< 0.2 cm) and layering. Contents are consistent with normal formed feces and gas.

Pancreas

The pancreatic parenchyma is appropriately isoechoic to surrounding tissue. Visible capsule is smooth and normal in contour. There is no visible pancreatic duct dilation. There is no evidence of active peripancreatic inflammation.

BREED

Terrier X

Free Abdomen

There is no evidence of free peritoneal effusion noted in these images.

SEX

Neutered Male

There is no apparent lymphadenopathy noted in these images.

ULTRASONOGRAPHIC FINDINGS

AGE

8 Years

- Chronic inflammatory hepatopathy pattern – An obvious cause for the reported increased liver enzymes is not identified in these images. Microscopic disease such as Leptospirosis, bacterial cholangiohepatitis, chronic active hepatitis, copper-associated hepatotoxicity, other hepatotoxicity, infiltrative neoplasia (considered unlikely), etc. cannot be definitively ruled out.

WEIGHT

41 Pounds

INTERPRETATION OF THE FINDINGS & FURTHER RECOMMENDATIONS

Recommendations include an “antigen search” for sources of reactive hepatopathy (including testing for Leptospirosis), followed by a course of empirical antibiotics and hepatic nutraceuticals, with monitoring of ALT for improvement. If improvement is not noted and/or enzyme increase progresses, liver sampling in the form of a fine needle aspirate and/or liver biopsy may be warranted.

INTERPRETED BY

Beth Johnson, DVM
DACVIM

IMAGING PERFORMED BY

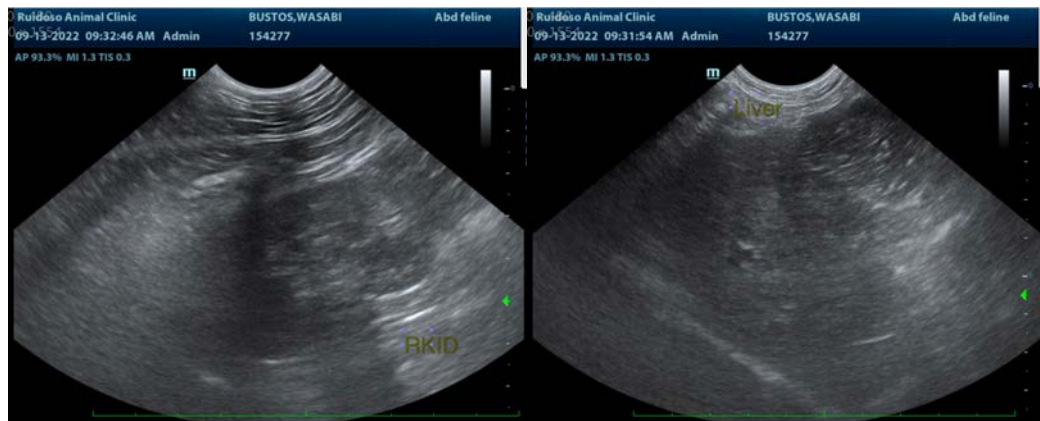
Dr. Amanda Favis

HOSPITAL NAME

Ruidoso AC

REFERRING VET

Dr. Amanda Favis



INVOICE

41282

DATE

9/13/22



PATIENT

Wasabi Bustos

SPECIES

Canine

BREED

Terrier X

SEX

Neutered Male

AGE

8 Years

WEIGHT

41 Pounds

INTERPRETED BY

Beth Johnson, DVM
DACVIM

**IMAGING
PERFORMED BY**

Dr. Amanda Favis

HOSPITAL NAME

Ruidoso AC

REFERRING VET

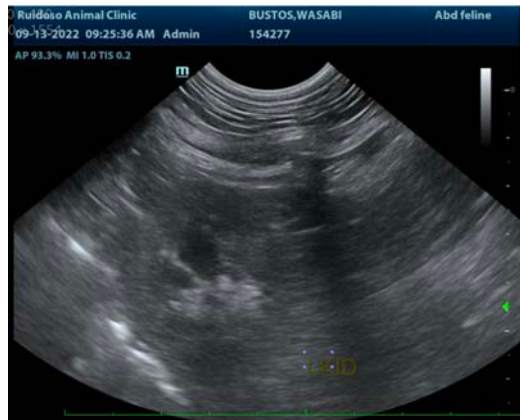Dr. Amanda Favis

INVOICE

41282

DATE

9/13/22



The information and recommendations provided are based on the images presented by the referring veterinarian/sonographer. No evaluation can be communicated regarding pathology that was not visible in the image/video clips provided.

Thank you for this referral. If the clinical or image interpretation does not parallel your findings or if I can be of any further assistance please contact me.

Beth Johnson, DVM, DACVIM
Beth.Johnson@sonopath.com