



<b>PATIENT</b>	<b>PRESENTING CLINICAL SIGNS</b>
Finn Smiddy	O has noted PU/PD recently. Having accidents in the house.
<b>SPECIES</b>	Abnormal PE/Chem/CBC/UA Results: CBC/Chemistry within normal limits. UA overall WNL, but USG 1.007. Repeated USG after overnight fast and it was 1.022. Urine culture and sensitivity negative. Cortisol 1.4, cleft lip, indentation on rump.
Canine	
<b>BREED</b>	<b>ULTRASONOGRAPHIC EXAMINATION OF THE ABDOMEN</b>
Lab Retriever Mix	<b>Urinary System</b>
<b>SEX</b>	The urinary bladder is moderately distended with anechoic contents. No masses, inflammatory changes, echogenic sediment or cystoliths are observed. The urinary bladder, trigone and visible pelvic urethra are normal in thickness with a smooth mucosal surface.
Neutered Male	The area of the prostate is examined without evident pathology.
<b>AGE</b>	The right kidney is normal in size (5.4 cm), shape and echogenicity. It has smooth peripheral margination. There is a normal 1:3 cortex to medulla ratio with appropriate corticomedullary distinction. There is no evidence of pyelectasia, mineral or infarcts observed.
2 Years 8 Months	The left kidney is normal in size (5.0 cm), shape and echogenicity. It has smooth peripheral margination. There is a normal 1:3 cortex to medulla ratio with appropriate corticomedullary distinction. There is no evidence of pyelectasia, mineral or infarcts observed.
<b>WEIGHT</b>	<b>Adrenal Glands</b>
33 Pounds	The areas of both adrenal glands are examined without evident pathology.
<b>INTERPRETED BY</b>	<b>Spleen</b>
Beth Johnson, DVM DACVIM	The spleen is subjectively normal in size with a normal smooth capsular contour. Parenchyma is appropriately finely textured and homogenous with normal echogenicity relative to surrounding tissue (hyperechoic to liver). No focal nodules or masses are observed. Splenic vasculature appears normal.
<b>IMAGING PERFORMED BY</b>	<b>Liver</b>
Dr. Katie Freson	The liver is subjectively small in size with normal smooth curvilinear peripheral contour. Parenchyma is appropriately hypoechoic to the spleen in echogenicity and appropriately mildly coarse and homogenous in echotexture. No focal lesions are observed. Visible vasculature and biliary tree appear normal without distension or congestion.
<b>HOSPITAL NAME</b>	Gallbladder is moderately distended with anechoic bile as well as suspended and gravity dependent echogenic debris. The wall is smooth without visible thickening. There is no evidence of cystic or CBD dilation. There is no evidence of effusion or inflammation.
Kings Vet Hospital	
<b>REFERRING VET</b>	<b>Gastrointestinal</b>
Dr. Katie Freson	The stomach wall is normal in thickness (canine < 0.5 cm and feline < 0.4 cm) and layering. The lumen of the stomach is empty with no evidence of obstruction, foreign material or infiltrative disease. Pyloric outflow tract appears patent.
<b>INVOICE</b>	The visible small intestines are normal in wall thickness and layering (canine duodenum < 0.5 cm and feline duodenum < 0.4 cm; other < 0.3 cm). Small intestinal motility appears adequate (1-3 contractions per min). The lumen of the small intestine is empty with no evidence of obstruction, foreign material or infiltrative disease.
41293	
<b>DATE</b>	
9/13/22	



**PATIENT**

Finn Smiddy The visible colon is normal in wall thickness (< 0.2 cm) and layering. Contents are consistent with normal formed feces and gas.

**SPECIES** *Pancreas*

Canine The pancreatic parenchyma is appropriately isoechoic to surrounding tissue. Visible capsule is smooth and normal in contour. There is no visible pancreatic duct dilation. There is no evidence of active peripancreatic inflammation.

**BREED**

Lab Retriever Mix

*Free Abdomen*

There is no evidence of free peritoneal effusion noted in these images.

**SEX**

There is no apparent lymphadenopathy noted in these images.

Neutered Male

**PRIMARY FINDINGS**

- **Subjectively mildly small liver** – Rule outs include normal patient variant versus vascular anomaly such as portosystemic shunt versus other.

**AGE**

2 Years 8 Months

**SECONDARY FINDINGS**

- **Gallbladder debris** - Cholecystic debris is of unknown clinical significance. It can be seen with biliary stasis from fasting or illness. Cholecystic debris is not necessarily related to hepatobiliary disease. Echogenic bile is most commonly an incidental finding in dogs and should be interpreted in combination with clinical signs such as nausea, inappetence, cranial abdominal discomfort and/or laboratory changes such as increased ALP and/or increased Tbili.

**WEIGHT**

33 Pounds

**INTERPRETED BY**

Beth Johnson, DVM  
DACVIM

**INTERPRETATION OF THE FINDINGS & FURTHER RECOMMENDATIONS**

Given this patient's at least partial concentration when urine is checked first thing in the morning, a primary polydipsia versus primary polyuria could be a contributing factor, differentials for which include behavioral/psychogenic polydipsia, pain, GI disease, central nervous system disease, etc. However, given the lack of full concentration to >1.030, testing for diseases that cause primary polyuria is still recommended.

**IMAGING PERFORMED BY**

Dr. Katie Freson

Given this patient's reported PU/PD and low baseline cortisol, a full ACTH stimulation test is recommended to rule out hypoadrenocorticism.

**HOSPITAL NAME**

Kings Vet Hospital

Given the subjectively small liver, bile acids are also recommended.

Testing for Leptospirosis is indicated.

**REFERRING VET**

Dr. Katie Freson

In the meantime, empirical therapies could include a course of antibiotics, and if a diagnostic is not obtained and/or clinical signs persist, more advanced workup including a full water deprivation test and/or desmopressin trial may be indicated.

**INVOICE**

41293

**DATE**

9/13/22



**PATIENT**

Finn Smiddy

**SPECIES**

Canine

**BREED**

Lab Retriever Mix

**SEX**

Neutered Male

**AGE**

2 Years 8 Months

**WEIGHT**

33 Pounds

**INTERPRETED BY**

Beth Johnson, DVM  
DACVIM

**IMAGING PERFORMED BY**

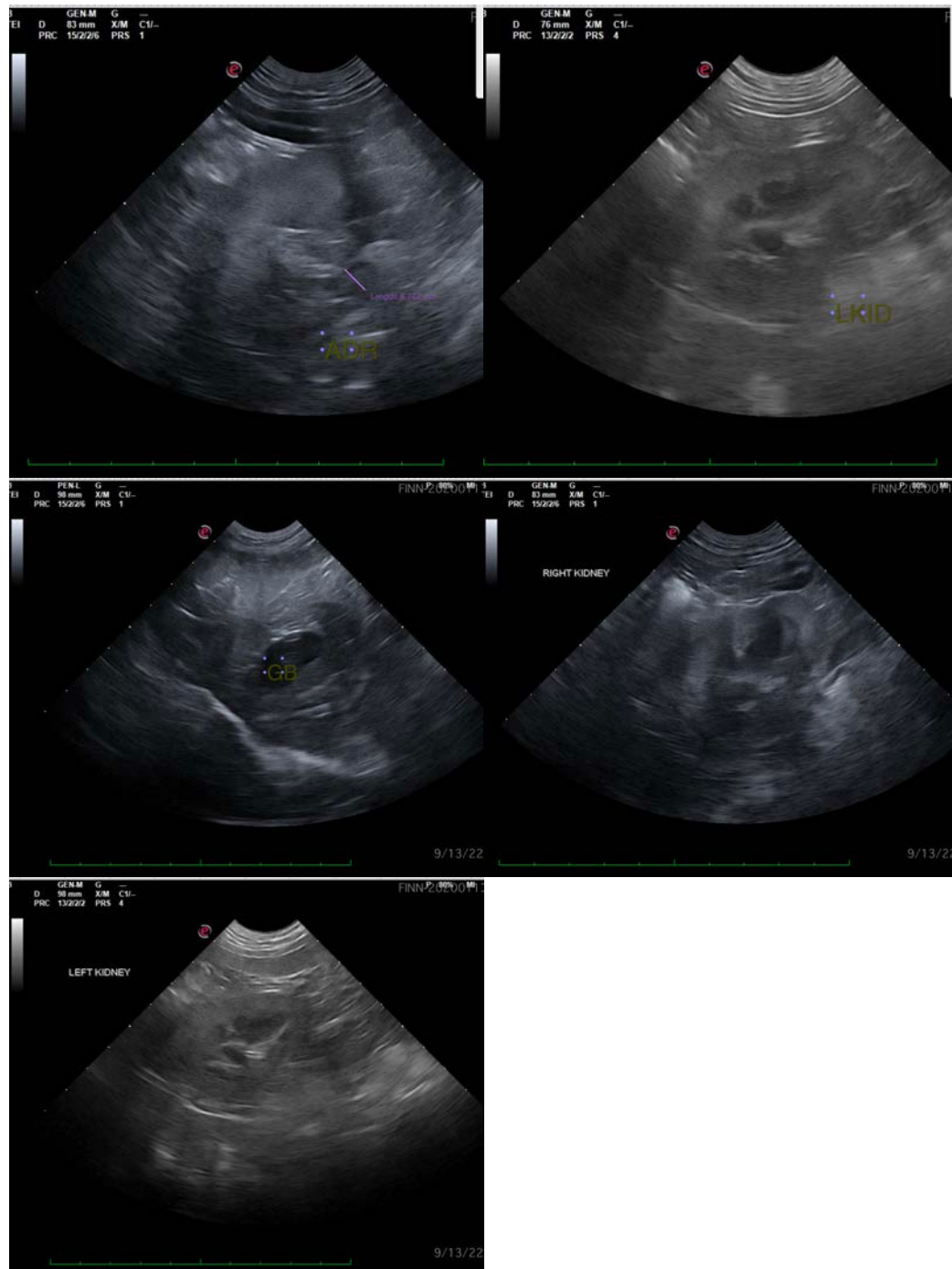
Dr. Katie Freson

**HOSPITAL NAME**

Kings Vet Hospital

**REFERRING VET**

Dr. Katie Freson



**INVOICE**

41293

**DATE**

9/13/22

The information and recommendations provided are based on the images presented by the referring veterinarian/sonographer. No evaluation can be communicated regarding pathology that was not visible in the image/video clips provided.

Thank you for this referral. If the clinical or image interpretation does not parallel your findings or if I can be of any further assistance please contact me.

**Beth Johnson, DVM, DACVIM** Beth.Johnson@sonopath.com