



PATIENT PRESENTING CLINICAL SIGNS

Oliver Mac History: Vomiting and Diarrhea. PU/PD. Been going on since June 2022.

SPECIES Abnormal PE/Chem/CBC/UA Results: Intestines feel thickened. Abnormal FPL Abnormal values June 2022 RBC- 6.99 (7.12-11.46 Hemoglobin-9.4 (10.3-16.2) Retic-14.1 (15.3-22.9) Idexx SDMA-16 (0-14) ALP-96 (12-59) T4- 1.3 (0.8-4.7) Comment or Message: Oliver is on Methimazole 5mg. 1 BID Atenolol 25mg. 1/4 T BID Ventricular Hypertrophy

Feline

BREED ULTRASONOGRAPHIC EXAMINATION OF THE ABDOMEN

DSH **Urinary System**

SEX Urinary bladder is adequately distended with anechoic contents. No masses, inflammatory changes, echogenic sediment or cystoliths are observed. The urinary bladder, trigone and visible pelvic urethra are normal in thickness with a smooth mucosal surface.

Neutered Male

AGE Left kidney is normal is size (4.06 cm), shape and echogenicity. It has smooth peripheral margination. There is a normal 1:3 cortex to medulla ratio with appropriate corticomedullary distinction. There is no evidence of mineral or infarcts observed. Mild pyelectasia was noted.

6 Years

WEIGHT Right kidney is normal is size (4.02 cm), shape and echogenicity. It has smooth peripheral margination. There is a normal 1:3 cortex to medulla ratio with appropriate corticomedullary distinction. There is no evidence of mineral or infarcts observed. Mild pyelectasia was noted.

9 Pounds 11 Ounces

Adrenal Glands

INTERPRETED BY Left adrenal gland is normal in size (0.41 cm), shape and overall architecture, echogenicity and echotexture. Visible surrounding vasculature appears normal.

Beth Johnson, DVM Right adrenal gland is normal in size (0.48 cm), shape and overall architecture, echogenicity and echotexture. Visible surrounding vasculature appears normal.
DACVIM

Spleen

IMAGING PERFORMED BY Spleen is subjectively normal in size with a normal smooth capsular contour. Parenchyma is appropriately finely textured and homogenous with normal echogenicity relative to surrounding tissue (hyperechoic to liver). No focal nodules or masses are observed. Splenic vasculature appears normal.

Amy Mayhew, LVT

HOSPITAL NAME Liver

SVS Imaging Michigan Liver is subjectively enlarged (swollen contour). Mild parenchymal remodeling with diffusely mildly coarse architecture and increased portal markings is present. Several small <0.5 cm in diameter hyperechoic nodule were noted. Visible vasculature and biliary tree appear normal without distension or congestion.

REFERRING VET

Hidden Springs VC Gallbladder is moderately distended with anechoic bile as well as suspended and gravity dependent echogenic debris. The wall is smooth without visible thickening. There is no evidence of cystic or CBD dilation. There is no evidence of effusion or inflammation. A tortuous but not pathologically dilated common bile duct noted, which can be a normal anatomic variant in cats.

INVOICE

17276

Gastrointestinal

DATE The visible stomach wall is normal in thickness and layering. The lumen of the stomach is mildly distended with echogenic non-shadowing luminal contents and gas consistent with normal ingesta.

9/12/22



PATIENT

There is no evidence of obstruction, foreign material or infiltrative disease. Pyloric outflow tract appears patent.

Oliver Mac

SPECIES

The visible small intestines are normal in wall thickness and layering. Small intestinal motility appears adequate (1-3 contractions per min). The lumen of the small intestine is:

Feline

The visible small intestine demonstrates areas of thick muscularis layer relative to mucosa (disruption of the normal 1:3 muscularis:mucosa ratio). Small intestinal submucosa is slightly irregular, thick and hyperechoic, without evident loss of layering appreciated. The lumen of the small intestine is mildly distended with echogenic non-shadowing luminal contents and gas consistent with normal ingesta. There is no evidence of obstruction, foreign material or infiltrative disease.

BREED

DSH

The visible colon is normal in wall thickness and layering. Contents are consistent with normal formed feces and gas.

SEX

Pancreas

Neutered Male

Pancreas is prominent (enlarged) in size, hypoechoic to surrounding tissue and has a mildly irregular undulating contour. Parenchyma is coarse with mixed echogenic remodeling noted. Pancreatic duct dilation is noted.

AGE

6 Years

Free Abdomen

Mesenteric lymph nodes are prominent in size with swollen capsular contour. Normal elongated shape (length to width ratio) is maintained. There is no loss of parenchymal detail. No free fluid is appreciated in these images.

WEIGHT

9 Pounds 11 Ounces

ULTRASONOGRAPHIC FINDINGS

INTERPRETED BY

- Inflammatory bowel disease pattern – Thick muscularis has been reported with infiltrative bowel disease including both benign inflammatory disease as well as infiltrative neoplasia such as lymphoma. No aggressive lymphadenopathy, loss of layering, etc. is noted to make lymphoma more probable, but lymphoma cannot be definitively ruled out without tissue sampling.

Beth Johnson, DVM
DACVIM

IMAGING PERFORMED BY

- Reactive mesenteric lymph nodes – infiltrative neoplastic disease cannot be ruled out but is considered less likely.

Amy Mayhew, LVT

HOSPITAL NAME

- Chronic active pancreatitis is suspected.

SVS Imaging Michigan

REFERRING VET

- Hypoechoic hepatomegaly with liver nodule-This appearance is consistent with an acute hepatopathy or acute cholangiohepatitis. Infiltrative neoplasia (round cell neoplasia) should also be considered. * Differentials for a discrete liver nodule include primarily benign changes such as nodular hyperplasia, fibrosis of an old hematoma, granuloma, etc.; however, while considered less likely, primary hepatic neoplasia, infiltrative round cell neoplasia and metastatic disease can mimic benign lesions and cannot be definitively ruled out.

Hidden Springs VC

INVOICE

- Gallbladder debris – Cholecystic debris is of unknown clinical significance. It can be seen with biliary stasis from fasting or illness, however, it can also be associated with hepatobiliary disease in cats and should be interpreted in combination with clinical signs such as nausea, inappetence, cranial abdominal discomfort and/or laboratory changes such as increased ALP and/or increased Tbili.

17276

DATE

9/12/22



PATIENT

Oliver Mac

- Mild pyelectasia – Differentials for pyelectasia include pyelonephritis, diuresis, congenital malformation or ureteral or lower urinary tract obstruction.

INTERPRETATION OF THE FINDINGS & FURTHER RECOMMENDATIONS

SPECIES

Feline

Given this patient reported PU/PD and concurrent pyelectasia, urinalysis and, if indicated based on urinalysis results, urine culture are recommended. If protein is present in an otherwise quiet sediment, protein quantification with a urine protein to creatinine ration is recommended.

BREED

DSH

A blood pressure is also recommended, if not recently evaluated.

SEX

Neutered Male

A gastrointestinal malabsorption panel (including cobalamin, folate, TLI and PLI) to Texas A&M GI Laboratory is recommended for further evaluation of GI and pancreatic function.

AGE

6 Years

Ideally, biopsies of the GI tract, being sure to include ileum if possible, are recommended to definitively diagnose and therefore manage the infiltrative bowel disease.

If biopsies cannot be obtained, empirical therapies could include diet change, empirical deworming with a 5 day course of Panacur, cobalamin supplementation (unless cobalamin level is evaluated and supplementation is not warranted) and prednisolone (if not contraindicated based on patient contraindications, co-morbidities, etc.). Other supportive therapeutic considerations could include fiber supplementation, especially with large bowel diarrhea and/or a probiotic.

WEIGHT

9 Pounds 11 Ounces

INTERPRETED BY

Beth Johnson, DVM
DACVIM

IMAGING PERFORMED BY

Amy Mayhew, LVT

HOSPITAL NAME

SVS Imaging Michigan

REFERRING VET

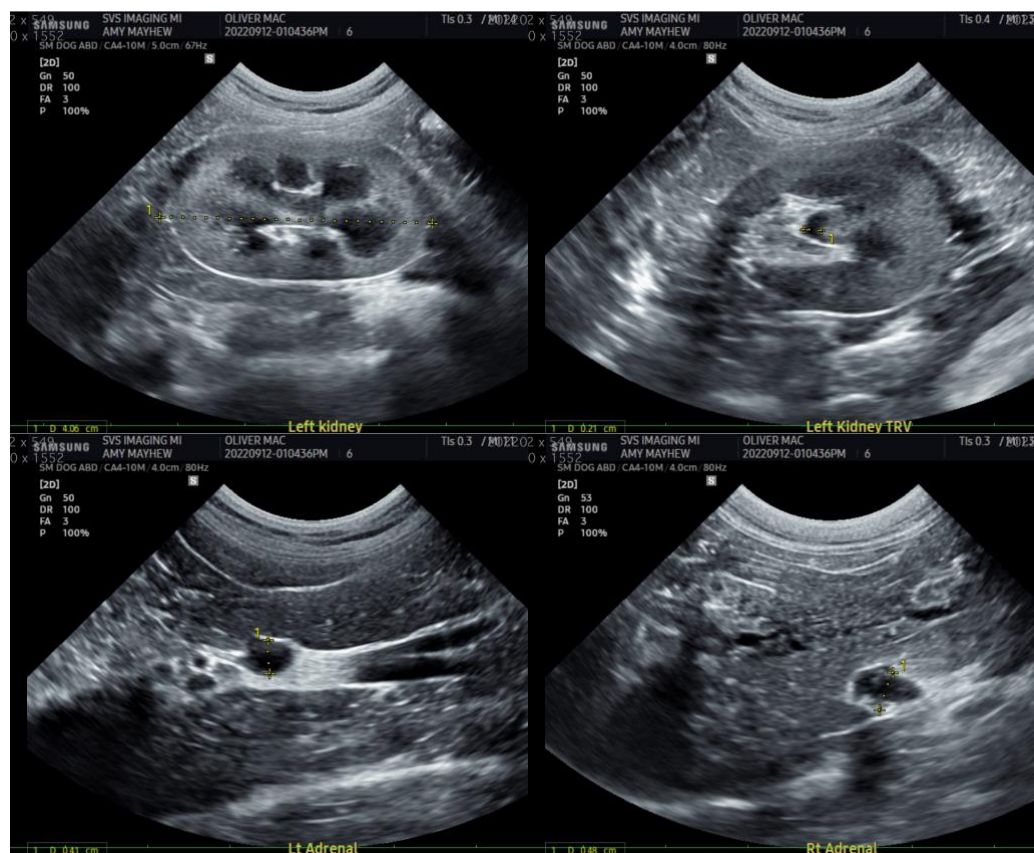
Hidden Springs VC

INVOICE

17276

DATE

9/12/22





PATIENT

Oliver Mac

SPECIES

Feline

BREED

DSH

SEX

Neutered Male

AGE

6 Years

WEIGHT

9 Pounds 11 Ounces

INTERPRETED BY

Beth Johnson, DVM
DACVIM

IMAGING PERFORMED BY

Amy Mayhew, LVT

HOSPITAL NAME

SVS Imaging Michigan

REFERRING VET

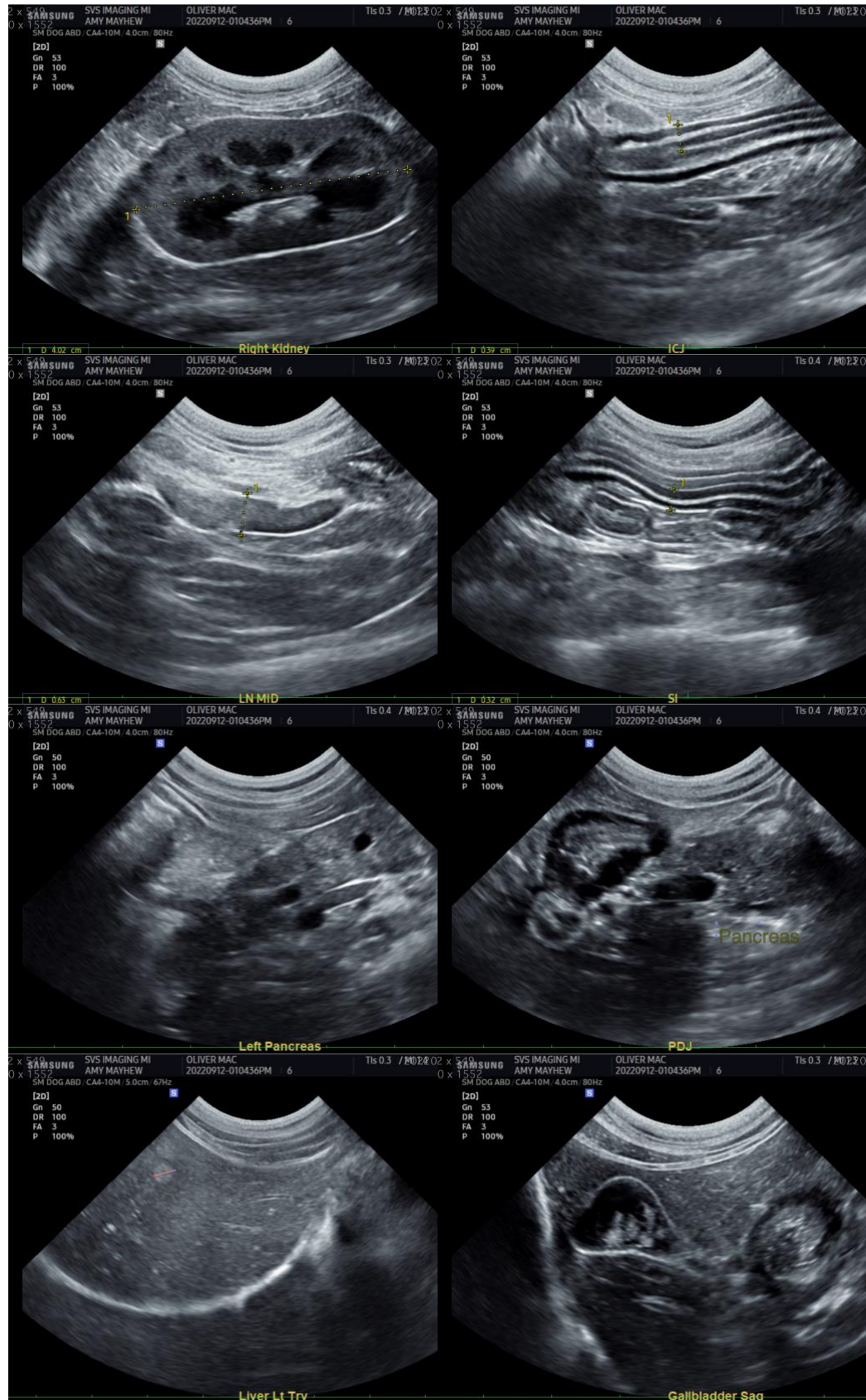
Hidden Springs VC

INVOICE

17276

DATE

9/12/22





PATIENT

Oliver Mac

SPECIES

Feline

BREED

DSH

SEX

Neutered Male

AGE

6 Years

WEIGHT

9 Pounds 11 Ounces

INTERPRETED BY

Beth Johnson, DVM
DACVIM

IMAGING PERFORMED BY

Amy Mayhew, LVT

HOSPITAL NAME

SVS Imaging Michigan

REFERRING VET

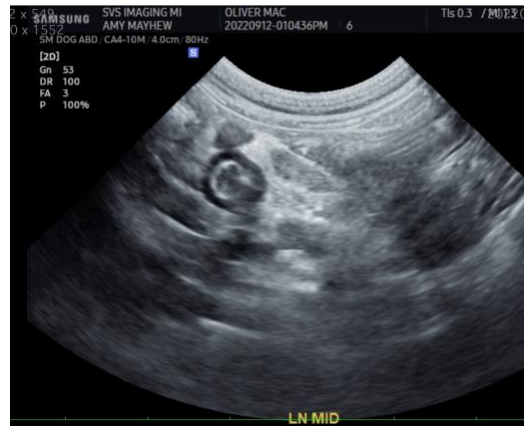Hidden Springs VC

INVOICE

17276

DATE

9/12/22



The information and recommendations provided are based on the images presented by the referring veterinarian. No evaluation can be communicated regarding pathology that was not visible in the image/video clips provided.

Thank you for this referral. If the clinical or image interpretation does not parallel your findings or if I can be of any further assistance please contact me.

Beth Johnson, DVM DACVIM

Beth.Johnson@SonoPath.com