

**DATE PRESENTING CLINICAL SIGNS**

9/12/22

Generally doing well at home, had recent 3 day episode of hyporexia following vaccines and history of pruritus but otherwise no additional medical history. On PE, palpating cranial organomegaly, mild dental disease, subq and dermal masses, otherwise PE wnl BW following PE findings showed elevated ALP (469)

**PATIENT**

Chase Klein

Current Medications: None currently.

Lab Results: 9/2/22 - ALP 469, triglycerides 581, remainder wnl

Date of Previous IntraPet Ultrasound: No previous.

**SPECIES**

Sedation: Not required to complete full diagnostic ultrasound.

Canine

Stat Report: Not requested.

**BREED**

Pit Bull

**Urinary System**

The urinary bladder is moderately distended with anechoic contents. No masses, inflammatory changes, echogenic sediment or cystoliths are observed. The urinary bladder, trigone and visible pelvic urethra are normal in thickness with a smooth mucosal surface.

**SEX**

Neutered Male

Prostate is normal in size, echotexture and echogenicity for a neutered male.

**AGE**

7/4/11

The right kidney is normal in size (6.25 cm), shape and echogenicity. It has smooth peripheral margination. There is a normal 1:3 cortex to medulla ratio with appropriate corticomedullary distinction. There is no evidence of pyelectasia or infarcts observed. Non-obstructive linear multifocal hyperechoic diverticular foci with acoustic shadowing are noted.

**WEIGHT**

69 Pounds

The left kidney is normal in size (7.14 cm), shape and echogenicity. It has smooth peripheral margination. There is a normal 1:3 cortex to medulla ratio with appropriate corticomedullary distinction. There is no evidence of pyelectasia or infarcts observed. Non-obstructive linear multifocal hyperechoic diverticular foci with acoustic shadowing are noted.

**INTERPRETED BY**Beth Johnson, DVM  
DACVIM**IMAGING PERFORMED BY**Stephanie Warga  
RDCS, RVT**HOSPITAL NAME**

Eastern AH

**Adrenal Glands**

The right adrenal gland is normal in size (3.16 cm long x 1.0 cm at the cranial pole and 0.58 cm at the caudal pole), shape and contour. Corticomedullary structure is unremarkable. Visible surrounding vasculature appears normal.

The left adrenal gland is normal in size (2.95 cm long x 0.61 cm at the cranial pole and 0.68 cm at the caudal pole), shape and contour. Corticomedullary structure is unremarkable. Visible surrounding vasculature appears normal.

**REFERRING VET**

Dr. Cusack

**Spleen**

The spleen is subjectively normal in size with a normal smooth capsular contour. Parenchyma is appropriately finely textured and homogenous with normal echogenicity relative to surrounding tissue (hyperechoic to liver). No focal nodules or masses are observed. Splenic vasculature appears normal.

**Liver**

The liver is subjectively normal in size with normal smooth curvilinear peripheral contour. Parenchyma is appropriately hypoechoic to the spleen in echogenicity and appropriately mildly coarse and homogenous in echotexture. No focal lesions are observed. Visible vasculature and biliary tree appear normal without distension or congestion.

**INVOICE**

41250

The gallbladder is non-distended in size. The wall is smooth without visible thickening. Luminal contents are primarily anechoic. There is no evidence of cystic or common bile duct dilation.

### ***Gastrointestinal***

The visible stomach wall is normal in thickness and layering. The stomach is moderately distended with echogenic non-shadowing luminal contents and gas consistent with normal ingesta. There is no evidence of obstruction, foreign material or infiltrative disease. However, given the reported history of fasting, delayed gastric emptying could be considered. Soft (cloth) fluid absorbing foreign material is considered less likely but cannot be definitively ruled out. If clinical signs are consistent (vomiting, etc.), recommendations include supportive medical care, 24 hours fasting and re-image.

The visible small intestines are normal in wall thickness and layering. Small intestinal motility appears adequate (1-3 contractions per min). The lumen of the small intestine is mildly distended with echogenic non-shadowing luminal contents and gas consistent with normal ingesta. There is no evidence of obstruction, foreign material or infiltrative disease.

The visible colon is normal in wall thickness (< 0.2 cm) and layering. Contents are consistent with normal formed feces and gas.

### ***Pancreas***

The pancreatic parenchyma is appropriately isoechoic to surrounding tissue. Visible capsule is smooth and normal in contour. There is no visible pancreatic duct dilation. There is no evidence of active peripancreatic inflammation.

### ***Free Abdomen***

There is no evidence of free peritoneal effusion noted in these images.

There is no apparent lymphadenopathy noted in these images.

## **ULTRASONOGRAPHIC FINDINGS**

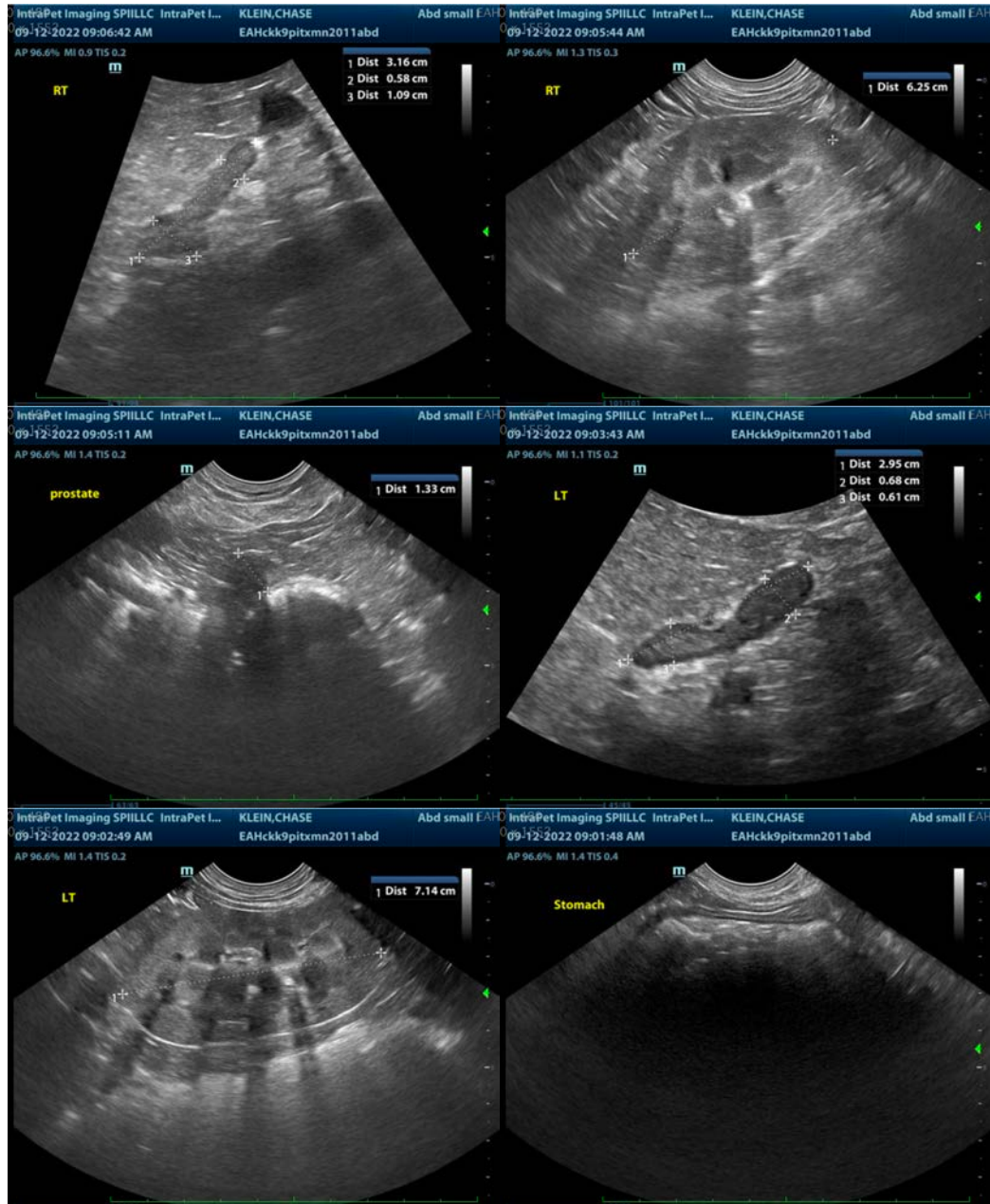
- Full stomach (see description above)
- Non-obstructive dystrophic mineralization bilaterally in the kidneys

## **INTERPRETATION OF THE FINDINGS & FURTHER RECOMMENDATIONS**

There is no obvious ultrasonographic reasons to explain this patient's reported increased alkaline phosphatase.

Differentials are vast and non-specific. Differentials include, but are not limited to, benign nodular hyperplasia which occurs in 70% of older dogs and often does not result in an abnormal ultrasound, reactive or idiopathic/vacuolar hepatopathy, cholestasis and/or hyperadrenocorticism as well as many chronic non-hepatobiliary diseases such as chronic infections/inflammation from dental disease, IBD, neoplasia, hyperlipidemia, hypothyroidism, chronic pancreatitis, chronic stress, etc.

There is no ultrasonographic evidence of cholestasis. Adrenocortical testing such as a low dose dexamethasone suppression test could be considered if clinical signs of hyperadrenocorticism are present. Ursodiol could be considered if gallbladder sludge is noted. A fine needle aspirate of the liver could be considered if patient's coagulation status is appropriate. Otherwise, recommendations include addressing any other concurrent disease and monitoring. If values are progressive, recheck imaging is recommended.



The information and recommendations provided are based on the images presented by the referring veterinarian/sonographer. No evaluation can be communicated regarding pathology that was not visible in the image/video clips provided.

Thank you for this referral. If the clinical or image interpretation does not parallel your findings or if I can be of any further assistance please contact me.

**Beth Johnson, DVM, DACVIM**  
 Beth.Johnson@sonopath.com