

DATE PRESENTING CLINICAL SIGNS

9/1/22 Dog presented for PE because he is dropping food and occasionally crying when chewing. Hx of Gr 3/6 systolic murmur. Referred to CVCA. Seen on 6/22/22 CVCA report: Mild degenerative valve dz, Mild Mitral regurg. Normal cardiac size and function. No cardiac medications at this time. Low risk for cardiac related anesthetic complications. Recommended repeat echo premeditation. Also has Hx of elevated liver enzymes (ALT/ALP/GGTP) X 1 year. Most recent labs 08/24/22: ALT (235) ALP (382) and GGTP (17) all elevated and higher than on prev panel 04/2022
Chol (576) also elevated and higher than prev panel in 4/2022. UA had USG of 1.010. Owner says dog is PU/PD and has been for at least 1 year or more. Recc AUS w/ Intrapet

PATIENT

Pablo Mejias

SPECIES

Canine

BREED

Jack Russell X

SEX

Neutered Male

AGE

8/27/07

WEIGHT

19.2 Pounds

INTERPRETED BY

Beth Johnson, DVM
DACVIM

IMAGING PERFORMED BY

Rachel Brillhart RDMS

HOSPITAL NAME

DocSide Veterinary
Medical Center

REFERRING VET

Dr. Tierney

INVOICE

40955

ULTRASONOGRAPHIC EXAMINATION OF THE ABDOMEN

Urinary System

The urinary bladder is moderately distended with anechoic contents. No masses, inflammatory changes, echogenic sediment or cystoliths are observed. The urinary bladder, trigone and visible pelvic urethra are normal in thickness with a smooth mucosal surface.

Prostate is normal in size, echotexture and echogenicity for a neutered male.

The right kidney is normal in size (3.95 cm), shape and echogenicity. It has smooth peripheral margination. There is a normal 1:3 cortex to medulla ratio with appropriate corticomedullary distinction. There is no evidence of pyelectasia, mineral or infarcts observed.

The left kidney is normal in size (4.32 cm), shape and echogenicity. It has smooth peripheral margination. There is a normal 1:3 cortex to medulla ratio with appropriate corticomedullary distinction. There is no evidence of pyelectasia, mineral or infarcts observed.

Adrenal Glands

Adrenal glands are plump/swollen in size. Normal shape and contour are maintained without evidence of capsular invasion. Corticomedullary structure is unremarkable. Visible surrounding vasculature appears normal. The left adrenal gland measures 2.5 cm long x 0.64 cm at the cranial pole and 0.87 cm at the caudal pole. The right adrenal gland measures 2.3 cm long x 0.75 cm at the cranial pole and 0.76 cm at the caudal pole

Spleen

The spleen is subjectively normal in size with a normal smooth capsular contour. Parenchyma is appropriately finely textured and homogenous with normal echogenicity relative to surrounding tissue (hyperechoic to liver). A 1.0 cm hypoechoic nodule is noted in the mid body, non-capsule disrupting. Splenic vasculature appears normal.

Liver

The liver is subjectively normal in size with normal smooth curvilinear peripheral contour. Parenchyma is appropriately hypoechoic to the spleen in echogenicity and appropriately mildly coarse and homogenous in

echotexture. A 4.0 cm x 6.0 cm, homogeneous, isoechoic mass is noted in the deep right liver. Visible vasculature and biliary tree appear normal without distension or congestion.

Gallbladder is moderately distended with anechoic bile as well as suspended and gravity dependent echogenic debris. The wall is smooth without visible thickening. There is no evidence of cystic or CBD dilation. There is no evidence of effusion or inflammation.

Gastrointestinal

The stomach wall is normal in thickness (canine < 0.5 cm and feline < 0.4 cm) and layering. The lumen of the stomach is empty with no evidence of obstruction, foreign material or infiltrative disease. Pyloric outflow tract appears patent.

The visible small intestines are normal in wall thickness and layering (canine duodenum < 0.5 cm and feline duodenum < 0.4 cm; other < 0.3 cm). Small intestinal motility appears adequate (1-3 contractions per min). The lumen of the small intestine is empty with no evidence of obstruction, foreign material or infiltrative disease.

The visible colon is normal in wall thickness (< 0.2 cm) and layering. Contents are consistent with normal formed feces and gas.

Pancreas

The observed pancreas appears appropriately isoechoic to surrounding omental fat. The capsule is mildly irregular in shape. Parenchyma is mildly heterogenous and coarse. There is no visible pancreatic duct dilation. There is no evidence of active peripancreatic inflammation.

Free Abdomen

There is no evidence of free peritoneal effusion noted in these images.

There is no apparent lymphadenopathy noted in these images.

PRIMARY FINDINGS

- **Isoechoic liver mass** – Differentials include a benign hepatoma or adenoma versus a well differentiated primary infiltrative hepatic neoplasia such as well differentiated hepatocellular carcinoma versus infiltrative round cell neoplasia, which is considered less likely.
- **Bilateral adrenomegaly** – consistent with adrenal hyperplasia secondary to pituitary dependent hyperadrenocorticism vs stress or normal variant. Interpret in combination with clinical signs of hyperadrenocorticism.
- **Hypo to anechoic splenic nodule** – likely represents a benign lesion such as a cyst, hematoma, nodular hyperplasia, extramedullary hematopoiesis, etc., however while considered less likely, infiltrative neoplasia can mimic benign lesions, and cannot be ruled out.

SECONDARY FINDINGS

- **Gallbladder debris** - Cholecystic debris is of unknown clinical significance. It can be seen with biliary stasis from fasting or illness. Cholecystic debris is not necessarily related to hepatobiliary disease. Echogenic bile is most commonly an incidental finding in dogs and should be interpreted in combination with clinical signs such as nausea, inappetence, cranial abdominal discomfort and/or laboratory changes such as increased ALP and/or increased Tbili.

- **Pancreatic age-related remodeling** – Mild irregularities are consistent with benign age-related change. Low-grade smoldering chronic pancreatitis cannot be ruled out and should be suspected in the face of appropriate clinical signs.

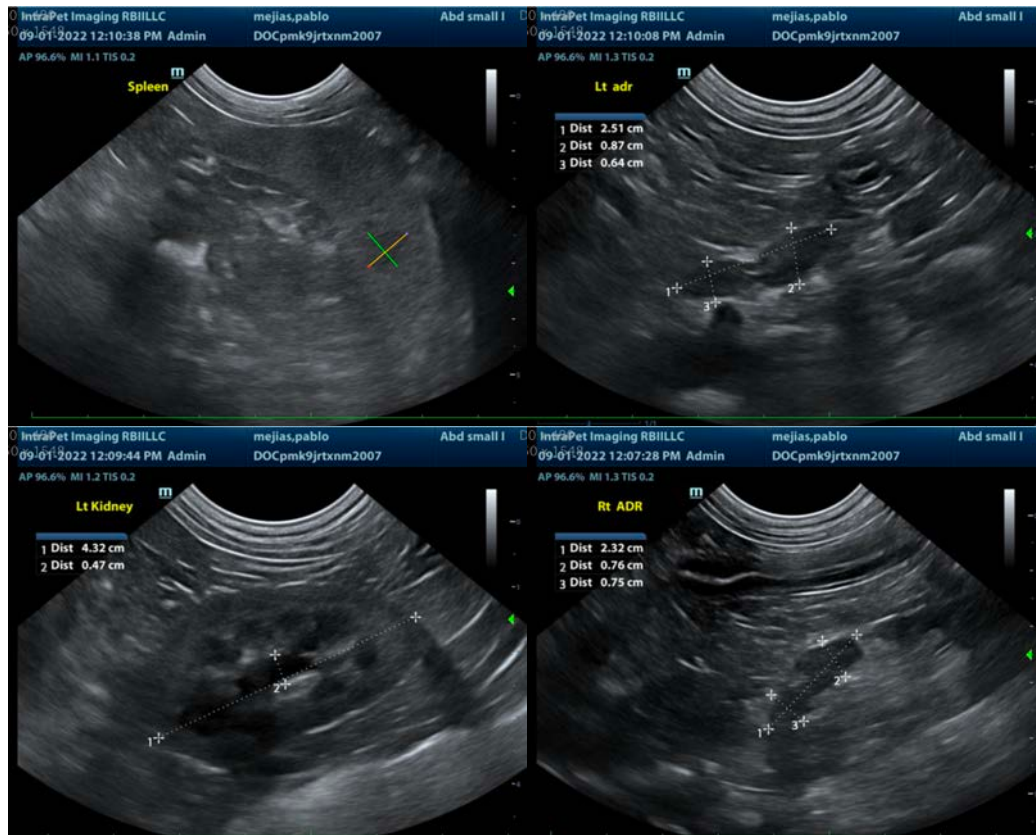
INTERPRETATION OF THE FINDINGS & FURTHER RECOMMENDATIONS

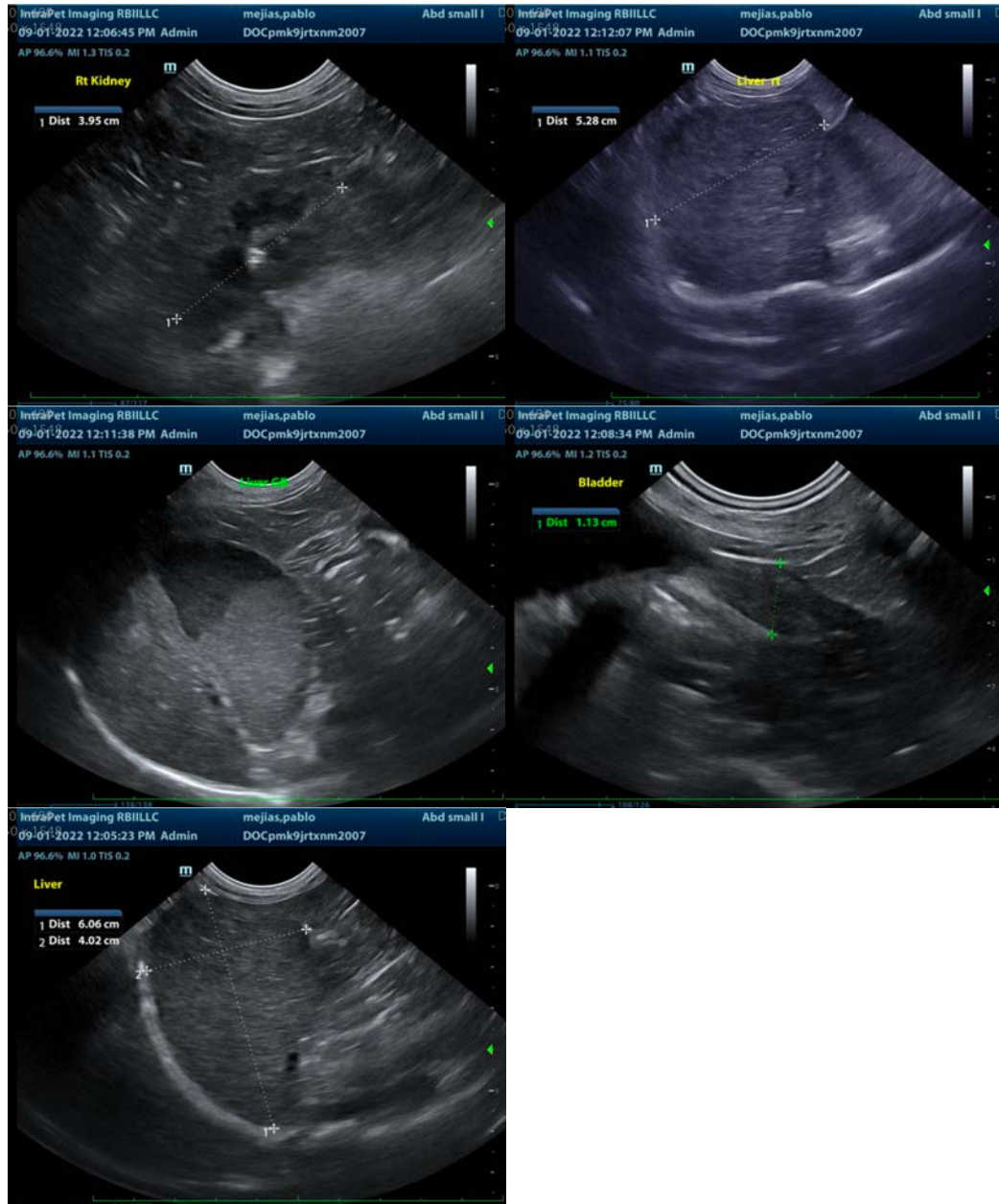
This patient's reported presenting complaint of painful difficulty chewing is likely not related to the pathology described in the abdomen, and should therefore be worked up separately with considerations given to TMJ pathology, masticatory myositis, etc.

Regarding the pathology noted in these images, a fine needle aspirate of the liver mass is recommended if patient's coagulation status is appropriate.

The described adrenal gland, liver and gallbladder changes are all suggestive of hyperadrenocorticism. If clinical signs of hyperadrenocorticism, such as polyuria, polydipsia, polyphagia, panting, hair loss, hypertension, etc. are present, testing for hyperadrenocorticism with a LDDS test is warranted. If clinical signs are not present, monitoring is recommended with testing pursued when/if clinical signs develop. If not recently evaluated, blood pressure is recommended. If not recently evaluated, a urinalysis and, if indicated based on urinalysis results, urine culture are also recommended. If protein is present in an otherwise quiet sediment, protein quantification with a urine protein to creatinine ratio is recommended.

Three view thoracic radiographs are recommended for further assessment of cardio-pulmonary status as well as to further evaluate for any evidence of metastatic disease, if not recently evaluated.





The information and recommendations provided are based on the images presented by the referring veterinarian/sonographer. No evaluation can be communicated regarding pathology that was not visible in the image/video clips provided.

Thank you for this referral. If the clinical or image interpretation does not parallel your findings or if I can be of any further assistance please contact me.

Beth Johnson, DVM, DACVIM
Beth.Johnson@sonopath.com