

**DATE PRESENTING CLINICAL SIGNS**

8/9/23

Patient presented for 2-3 month history of swollen scrotum. One testicle palpates enlarged, firm. Second teste apparently atrophied. Markedly enlarged prostate. Comfortable, no urinary issues

PATIENT

Rex Huesman
Baltimore County K9

Current Medications: None,
Lab Results: WNL.
Date of Previous IntraPet Ultrasound: No previous.
Sedation: Full.
Stat Report: Not requested.
Imaging Performed By: Rachel Brillhart, RDMS.

SPECIES

Canine

ULTRASONOGRAPHIC EXAMINATION OF THE ABDOMEN**BREED**

German Shepherd

Urinary System

Urinary bladder is adequately distended. It has a normal uniform wall thickness. Contents include primarily anechoic fluid with occasional echogenic non-shadowing debris, most consistent with exfoliated cells, mucous and/or small blood clots. Both sterile inflammation as well as urinary tract infection can also present with echogenic debris. No masses or cystoliths are observed. The trigone and visible pelvic urethra are normal in thickness with a smooth mucosal surface.

SEX

Intact Male

AGE

7/13/13

Prostate is symmetrically enlarged (6.15 cm thick) with smooth margins that are well differentiated from surrounding tissue. Normal bilobed shape is maintained. Parenchyma is diffusely hyperechoic. Several small anechoic cysts are noted. No mineral is noted.

WEIGHT

68.6 Pounds

The right kidney is normal in size (7.29 cm), shape and echogenicity. It has smooth peripheral margination. There is a normal 1:3 cortex to medulla ratio with appropriate corticomedullary distinction. There is no evidence of pyelectasia, mineral or infarcts observed.

INTERPRETED BY

Beth Johnson, DVM
DACVIM

The left kidney is normal in size (7.65 cm), shape and echogenicity. It has smooth peripheral margination. There is a normal 1:3 cortex to medulla ratio with appropriate corticomedullary distinction. There is no evidence of pyelectasia, mineral or infarcts observed.

HOSPITAL NAME

Paradise AH

Adrenal Glands

Adrenal glands are plump/swollen in size. Normal shape and contour are maintained without evidence of capsular invasion. Corticomedullary structure is unremarkable. Visible surrounding vasculature appears normal. The left adrenal gland measures 0.82 cm at the cranial pole and 1.4 cm at the caudal pole. The right adrenal gland measures 0.93 cm at the cranial pole and 0.87 cm at the caudal pole.

REFERRING VET

Dr. Pound

Spleen

The spleen is subjectively normal in size with a normal smooth capsular contour. Parenchyma is appropriately finely textured and homogenous with normal echogenicity relative to surrounding tissue (hyperechoic to liver). No focal nodules or masses are observed. Splenic vasculature appears normal.

INVOICE

44535

Liver

The liver is subjectively normal in size with normal smooth curvilinear peripheral contour. Parenchyma is appropriately hypoechoic to the spleen in echogenicity and appropriately mildly coarse and homogenous in echotexture. No focal lesions are observed. Visible vasculature and biliary tree appear normal without distension or congestion.

Gallbladder is moderately distended with anechoic bile as well as suspended and gravity dependent echogenic debris. The wall is smooth without visible thickening. There is no evidence of cystic or CBD dilation. There is no evidence of effusion or inflammation.

Gastrointestinal

The visible stomach wall is normal in thickness and layering. The lumen of the stomach is mildly distended with echogenic non-shadowing luminal contents and gas consistent with normal ingesta. There is no evidence of obstruction, foreign material or infiltrative disease. Pyloric outflow tract appears patent.

The visible small intestines are normal in wall thickness and layering (canine duodenum < 0.5 cm and feline duodenum < 0.4 cm; other < 0.3 cm). Small intestinal motility appears adequate (1-3 contractions per min). The lumen of the small intestine is empty with no evidence of obstruction, foreign material or infiltrative disease.

The visible colon is normal in wall thickness (< 0.2 cm) and layering. Contents are consistent with normal formed feces and gas.

Pancreas

The pancreatic parenchyma is appropriately isoechoic to surrounding tissue. Visible capsule is smooth and normal in contour. There is no visible pancreatic duct dilation. There is no evidence of active peripancreatic inflammation.

Free Abdomen

There is no evidence of free peritoneal effusion noted in these images.

There is no apparent lymphadenopathy noted in these images.

There is a 1.6 cm x 2.7 cm heterogeneous, partially cystic nodule within the right testicle. The left testicle appears normal yet small in size.

ULTRASONOGRAPHIC FINDINGS

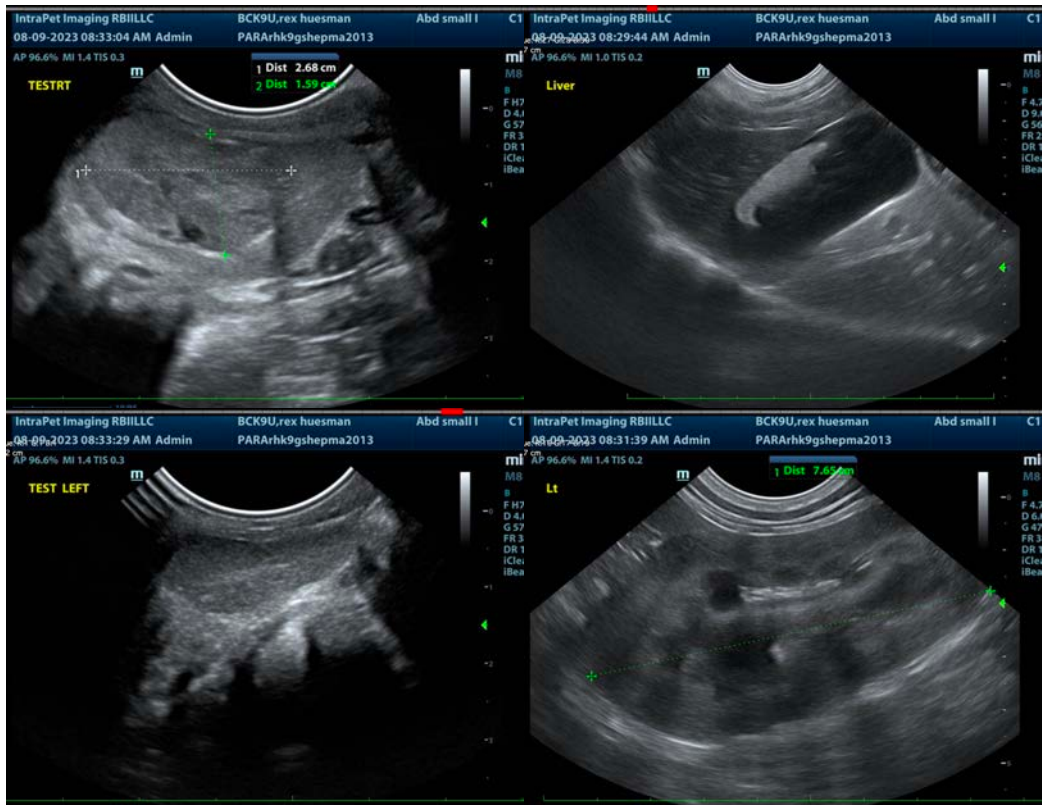
- Right testicular nodule with both benign and infiltrative neoplastic/malignant differentials possible.
- Benign Prostatic Hyperplasia with cysts – Prostatic findings are most consistent with Benign Prostatic Hyperplasia (BPH) and concurrent benign prostatic cysts. Active prostatitis cannot be ruled out. Infiltrative neoplasia cannot be ruled out but is considered less likely.
- Bilateral adrenomegaly – consistent with adrenal hyperplasia secondary to pituitary dependent hyperadrenocorticism vs stress or normal variant. Interpret in combination with clinical signs of hyperadrenocorticism.
- Mild to moderate gallbladder debris - Cholecystic debris is of unknown clinical significance. It can be seen with biliary stasis from fasting or illness. Cholecystic debris is not necessarily related to hepatobiliary disease. Echogenic bile is most commonly an incidental finding in dogs and should be interpreted in combination with clinical signs such as nausea, inappetence, cranial abdominal discomfort and/or laboratory changes such as increased ALP and/or increased Tbili.
- Urinary bladder debris

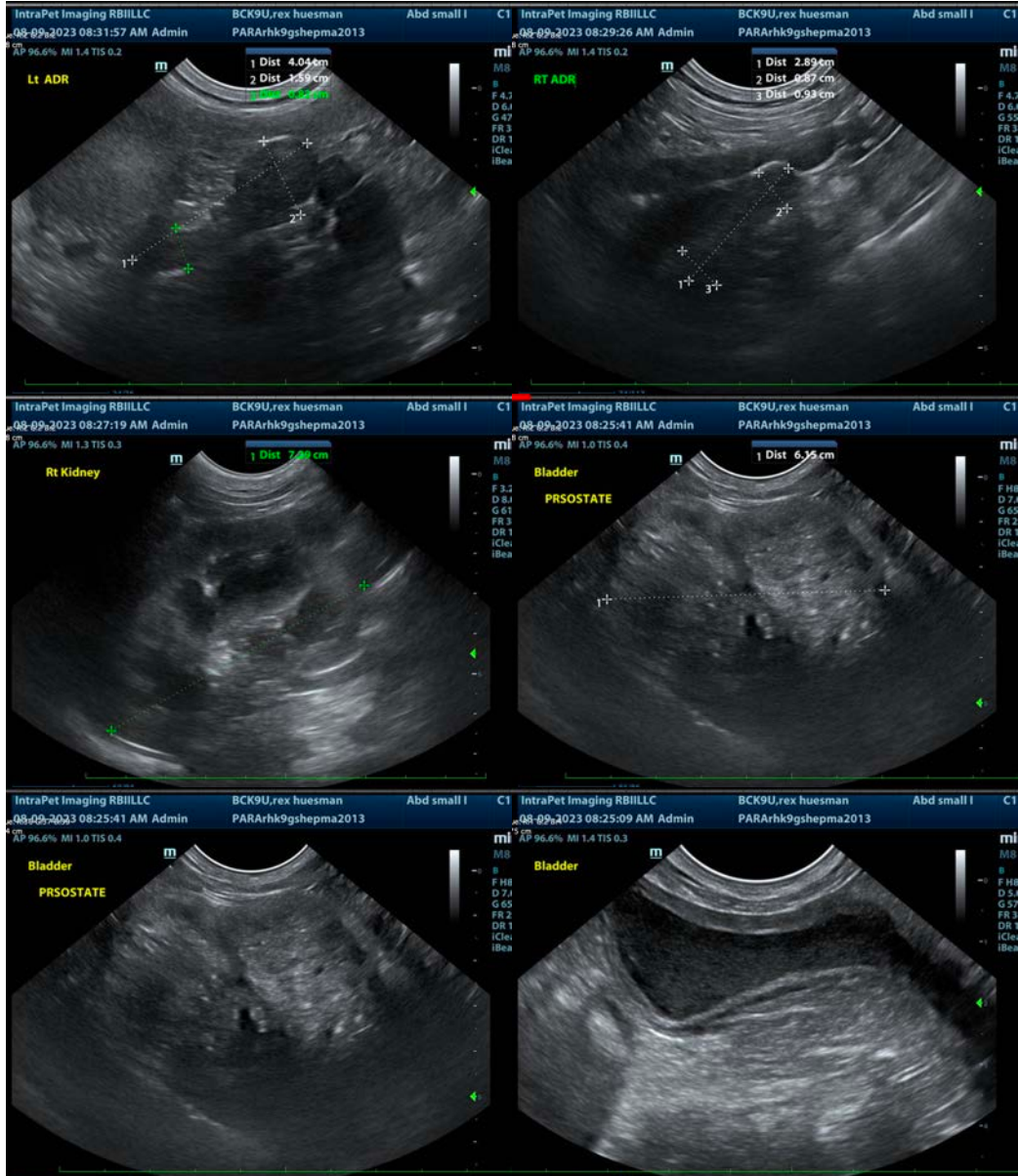
INTERPRETATION OF THE FINDINGS & FURTHER RECOMMENDATIONS

As was reportedly performed, patient neuter with submission of testicular nodule for histopath is recommended.

If not recently, a urinalysis and, if indicated based on urinalysis results, urine culture are recommended. If protein is present in an otherwise quiet sediment, protein quantification with a urine protein to creatinine ratio is recommended.

The remainder of the changes are mild and non-specific and should be interpreted in combination with clinical sign when/if they develop, but likely require no further intervention in an asymptomatic patient at this time.





The information and recommendations provided are based on the images presented by the referring veterinarian/sonographer. No evaluation can be communicated regarding pathology that was not visible in the image/video clips provided.

Thank you for this referral. If the clinical or image interpretation does not parallel your findings or if I can be of any further assistance please contact me.

Beth Johnson, DVM, DACVIM
info@sonopath.com