



**PATIENT PRESENTING CLINICAL SIGNS**

**George Dewalt**  
**SPECIES** History: Vomiting noted at home beginning in January of this year. Patient was evaluated with bloodwork due to history of hyperthyroidism well controlled on methimazole. Bloodwork in January 2023 WNL. P improved symptomatically with Cerenia, but vomiting has been persistently noted at home.

**Feline**  
**BREED** Abnormal PE/Chem/CBC/UA Results: No significant changes on lab-work (T4 0.8) Radiographs unremarkable

**DSH**  
**SEX** **ULTRASONOGRAPHIC EXAMINATION OF THE ABDOMEN**

**Urinary System**

**Neutered Male**  
**AGE** Urinary bladder is adequately distended. It has a normal uniform wall thickness. Contents include primarily anechoic fluid with a moderate to large amount of echogenic non-shadowing debris, which could be partially consistent with incidental suspended lipid in a cat, likely combined with exfoliated cells, mucous and/or small blood clots. Additionally, there is mineral/sand debris. Small, clumped cystoliths cannot be definitively ruled out. Both sterile inflammation as well as urinary tract infection can also present with echogenic debris. No masses are observed. The trigone and visible pelvic urethra are normal in thickness with a smooth mucosal surface.  
**13 years**  
**WEIGHT**

**7.44 lbs**  
**INTERPRETED BY** Left kidney is normal in size (3.90 cm), shape and echogenicity. It has smooth peripheral margination. There is a normal 1:3 cortex to medulla ratio with appropriate corticomedullary distinction. There is no evidence of pyelectasia, mineral or infarcts observed.

**Beth Johnson, DVM**  
**DACVIM** Right kidney is normal in size (3.75 cm), shape and echogenicity. It has smooth peripheral margination. There is a normal 1:3 cortex to medulla ratio with appropriate corticomedullary distinction. There is no evidence of pyelectasia, mineral or infarcts observed.

**IMAGING PERFORMED BY**

**Adrenal Glands**  
**Jack Reese** Left adrenal gland is normal in size (0.52 cm), shape and overall architecture, echogenicity and echotexture. Visible surrounding vasculature appears normal.

**HOSPITAL NAME** Right adrenal gland is normal in size (0.70 cm at cranial pole / 0.30 cm at caudal pole), shape and overall architecture, echogenicity and echotexture. Visible surrounding vasculature appears normal.

Willow Run VC

**Spleen**

**REFERRING VET**

Spleen is subjectively large in size with a mildly swollen but smooth capsule. Parenchyma is normal and homogenous in echogenicity and echotexture. No focal nodules or masses are observed. Splenic vasculature appears normal.

Katie Newcamp DVM

**Liver**

**INVOICE**

Liver is subjectively enlarged (swollen contour) without disruption of architecture. It has a normal homogenous echotexture. Parenchyma is diffusely hyperechoic characterized by less prominent than normal portal vein walls and increased echogenicity relative to the spleen and falciform fat. No focal lesions are observed. Visible vasculature and biliary tree appear normal without distension or congestion.

14016

**DATE**

Gallbladder is non-distended in size. The wall is smooth without visible thickening. Luminal contents are primarily anechoic. There is no evidence of cystic or common bile duct dilation.

8.9.23

**Gastrointestinal**

The visible stomach wall is normal in thickness and layering. The lumen of the stomach is empty with no evidence of obstruction, foreign material or infiltrative disease. Pyloric outflow tract appears patent.



**PATIENT**

The visible small intestine demonstrates areas of thick muscularis layer relative to mucosa (disruption of the normal 1:3 muscularis:mucosa ratio). Small intestinal submucosa is slightly irregular, thick and hyperechoic, without evident loss of layering appreciated. The lumen of the small intestine is empty with no evidence of obstruction or foreign material.

George Dewalt

**SPECIES**

Feline

The visible colon is normal in wall thickness and layering. Contents are consistent with normal formed feces and gas.

**BREED**

***Pancreas***

DSH

The observed pancreas appears appropriately isoechoic to surrounding omental fat. Visible capsule is smooth and normal in contour. Visible pancreatic parenchyma is homogenous and unremarkable. There is no visible pancreatic duct dilation. There is no evidence of active peripancreatic inflammation.

**SEX**

Neutered Male

***Free Abdomen***

A large amount of anechoic free fluid is noted. There is no apparent lymphadenopathy.

**AGE**

13 years

**ULTRASONOGRAPHIC FINDINGS**

**WEIGHT**

7.44 lbs

**Findings**

**INTERPRETED BY**

Beth Johnson, DVM  
DACVIM

- Hypersplenism – can be associated with congestion caused by sedation (if sedated) but can also be associated with diffuse infiltrative disease. Both benign conditions such as extramedullary hematopoiesis, lymphoid hyperplasia, amyloidosis (leave amyloidosis out if canine) as well as infiltrative neoplastic diseases such as round cell neoplasia should be considered.
- Hyperechoic hepatomegaly – This appearance is most consistent with benign hepatic lipidosis. Infiltrative disease such as amyloidosis or round cell neoplasia, such as mast cell tumor or less likely, lymphoma, is also possible.
- Mild/subtle inflammatory bowel disease (IBD) pattern – Thick muscularis has been reported with infiltrative bowel disease including both benign inflammatory disease as well as infiltrative neoplasia such as lymphoma. No aggressive lymphadenopathy, loss of layering, etc. is noted to make lymphoma more probable, but lymphoma cannot be definitively ruled out without tissue sampling.
- A large amount of free fluid is present and is of unknown origin, with differentials being paraneoplastic effusion vs the result of increased hydrostatic pressure from lymph obstruction, cardiac disease, etc., vs potentially decreased oncotic pressure if hypoalbuminemia is present, vasculitis, hemorrhage, viscus organ rupture, etc.
- Urinary bladder debris, including mineral/sand debris and potentially small cystoliths

**IMAGING PERFORMED BY**

Jack Reese

**HOSPITAL NAME**

Willow Run VC

**REFERRING VET**

Katie Newcamp DVM

**INVOICE**

14016

**DATE**

8.9.23

**INTERPRETATION OF THE FINDINGS & FURTHER RECOMMENDATIONS**

- Fluid sampling could be considered for cytology as well as a fine-needle aspirate of the spleen +/- the liver (if coagulation status of the patient is appropriate).
- If not recently evaluated, a urinalysis and (if indicated based on urinalysis results) urine culture are recommended. If protein is present in an otherwise quiet sediment, protein quantification with a urine protein to creatinine ration is recommended.
- A gastrointestinal malabsorption panel (including cobalamin, folate, TLI and PLI) to Texas A&M GI Laboratory is recommended for further evaluation of GI and pancreatic function.



**PATIENT**

George Dewalt

- Further recommendations, empirical therapies, etc. are dependent on above results. Pending fluid analysis/cytology results, an echocardiogram could be considered.

**SPECIES**

Feline

- In the meantime, in addition to the supportive/symptomatic medical management, a transition from oral to transdermal methimazole could also potentially help alleviate gastrointestinal signs while awaiting a diagnosis.

**BREED**

DSH

**SEX**

Neutered Male

**AGE**

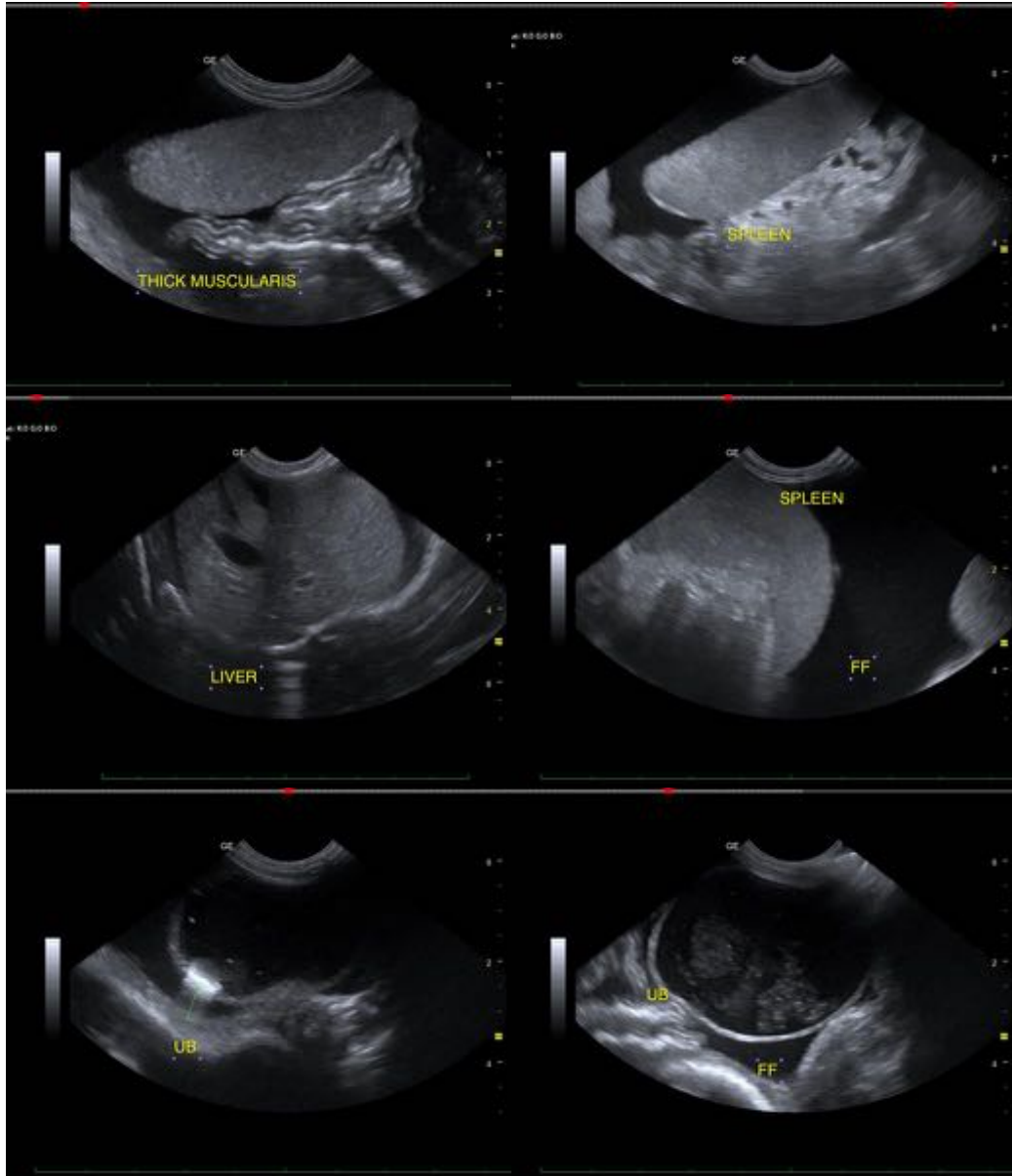
13 years

**WEIGHT**

7.44 lbs

**INTERPRETED BY**

Beth Johnson, DVM  
DACVIM



**IMAGING PERFORMED BY**

Jack Reese

**HOSPITAL NAME**

Willow Run VC

**REFERRING VET**

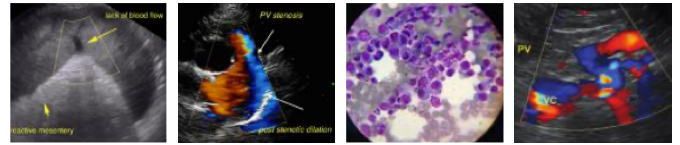
Katie Newcamp DVM

**INVOICE**

14016

**DATE**

8.9.23



**PATIENT**

George Dewalt

**SPECIES**

Feline

**BREED**

DSH

**SEX**

Neutered Male

**AGE**

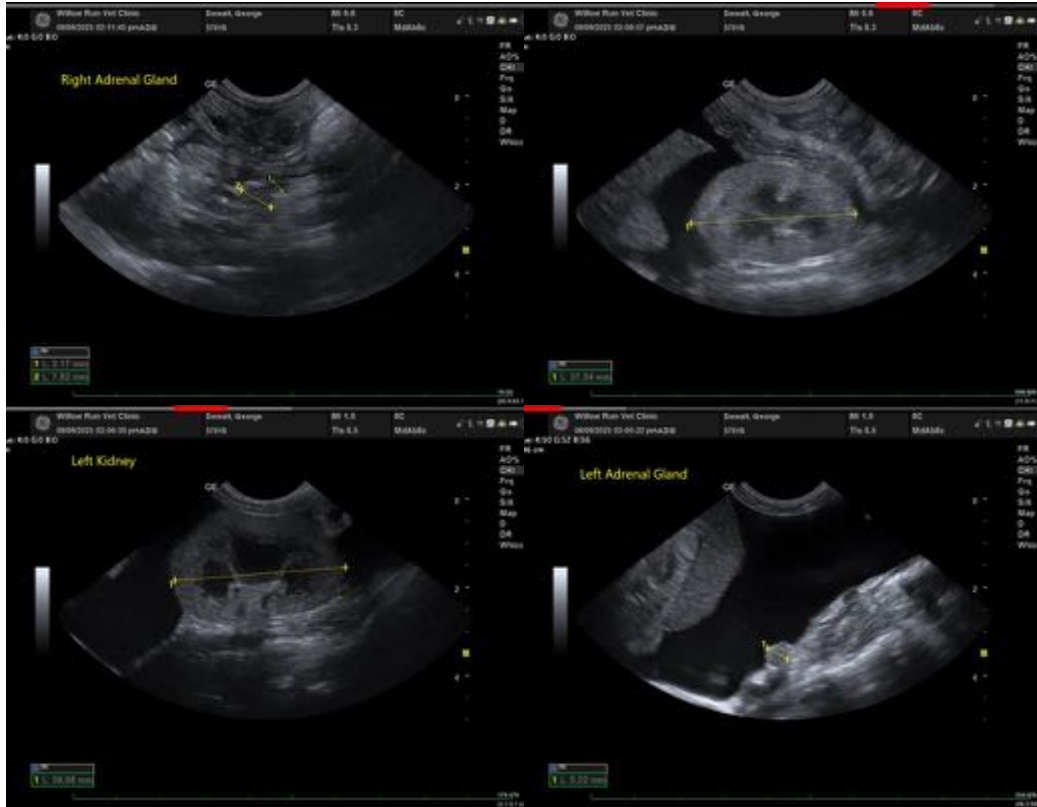
13 years

**WEIGHT**

7.44 lbs

**INTERPRETED BY**

Beth Johnson, DVM  
DACVIM



**IMAGING PERFORMED BY**

Jack Reese

The information and recommendations provided are based on the images presented by the referring veterinarian. No evaluation can be communicated regarding pathology that was not visible in the image/video clips provided.

**HOSPITAL NAME**

Willow Run VC

Thank you for this referral. If the clinical or image interpretation does not parallel your findings or if I can be of any further assistance, please contact me.

**REFERRING VET**

Katie Newcamp DVM

**Beth Johnson, DVM DACVIM**  
info@SonoPath.com

**INVOICE**

14016

**DATE**

8.9.23