



PATIENT

Jerry Mendez CAH

PRESENTING CLINICAL SIGNS

History: Weight loss, blood work NSF

SPECIES

Feline

ULTRASONOGRAPHIC EXAMINATION OF THE ABDOMEN

Urinary System

BREED

Domestic Shorthair

Urinary bladder is adequately distended. It has a normal uniform wall thickness. Contents include primarily anechoic fluid with occasional echogenic non-shadowing debris, most consistent with incidental suspended lipid in a cat, possibly combined with exfoliated cells, mucous and/or small blood clots. Both sterile inflammation as well as urinary tract infection can also present with echogenic debris. No masses or cystoliths are observed. The trigone and visible pelvic urethra are normal in thickness with a smooth mucosal surface.

SEX

Neutered male

Kidneys are overall normal in size and shape with smooth peripheral margination. A normal 1:3 cortex to medulla ratio is maintained. The medulla and cortices are uniform in texture with some mild increased cortical echogenicity and mild loss of corticomedullary distinction, expected in this age patient. There is no evidence of pyelectasia, mineral or infarcts observed. The left kidney measured 4.99 cm and the right kidney measured 4.33 cm.

AGE

13 years

WEIGHT

7 lbs

Adrenal Glands

The regions of the adrenal glands were visualized with no evidence of pathology.

INTERPRETED BY

Beth Johnson, DVM
DACVIM

Spleen

Spleen is subjectively normal in size with a normal smooth capsular contour. Parenchyma is appropriately finely textured and homogenous with normal echogenicity relative to surrounding tissue (hyperechoic to liver). No focal nodules or masses are observed. Splenic vasculature appears normal.

IMAGING PERFORMED BY

Dr. Petrone

Liver

Liver is subjectively normal in size with normal smooth curvilinear peripheral contour. Parenchyma is appropriately hypoechoic to the spleen in echogenicity and appropriately mildly coarse and homogenous in echotexture. No focal lesions are observed. Visible vasculature and biliary tree appear normal without distension or congestion.

HOSPITAL NAME

Long Branch AH

REFERRING VET

Dr. Petrone

Gallbladder is moderately distended with anechoic bile as well as suspended and gravity dependent echogenic debris. The wall is smooth without visible thickening. The cystic and common bile duct are tortuous, which is typically a normal, anatomic, non-pathologic variant in a senior cat. There is no pathological distension noted.

INVOICE

32242

DATE

8/9/22



PATIENT	<i>Gastrointestinal</i>
Jerry Mendez CAH	The visible stomach wall is normal in thickness and layering. The lumen of the stomach is mildly distended with echogenic non-shadowing luminal contents and gas consistent with normal ingesta. There is no evidence of obstruction, foreign material or infiltrative disease. Pyloric outflow tract appears patent.
SPECIES	
Feline	The visible small intestines are normal in wall thickness and layering. Small intestinal motility appears adequate (1-3 contractions per min). The lumen of the small intestine is mildly distended with echogenic non-shadowing luminal contents and gas consistent with normal ingesta. There is no evidence of obstruction, foreign material or infiltrative disease.
BREED	
Domestic Shorthair	The visible colon is normal in wall thickness (< 0.2 cm) and layering. Contents are consistent with normal formed feces and gas.
SEX	
Neutered male	<i>Pancreas</i>
AGE	The observed pancreas appears appropriately isoechoic to surrounding omental fat. Visible capsule is smooth and normal in contour. Visible pancreatic parenchyma is homogenous and unremarkable. There is no visible pancreatic duct dilation. There is no evidence of active peripancreatic inflammation.
13 years	
WEIGHT	<i>Free Abdomen</i>
7 lbs	There is a scant amount of anechoic free fluid between the bowel loops and enlarged, hypoechoic, partially cystic mesenteric lymphadenopathy is appreciated.
INTERPRETED BY	ULTRASONOGRAPHIC FINDINGS
Beth Johnson, DVM DACVIM	Primary Findings
IMAGING PERFORMED BY	Mesenteric lymphadenopathy. Differentials include reactive lymphadenopathy as well as infiltrative neoplasia.
Dr. Petrone	Scant amount of anechoic free fluid.
HOSPITAL NAME	Gallbladder debris – Cholecytic debris is of unknown clinical significance. It can be seen with biliary stasis from fasting or illness, however, it can also be associated with hepatobiliary disease in cats and should be interpreted in combination with clinical signs such as nausea, inappetence, cranial abdominal discomfort and/or laboratory changes such as increased ALP and/or increased Tbili.
Long Branch AH	Urinary bladder debris.
REFERRING VET	Age related renal changes.
Dr. Petrone	
INVOICE	<u>INTERPRETATION OF THE FINDINGS & FURTHER RECOMMENDATIONS</u>
32242	There is no obvious ultrasonographic reason to explain the patient's weight loss; however, occult maldigestive or malabsorptive gastrointestinal disease can be present without markedly abnormal ultrasounds. Further work-up is dependent on the patient's caloric intake.
DATE	If the patient's caloric intake is inadequate due to decreased appetite then further investigation of
8/9/22	



PATIENT

reasons for a decreased appetite such as dental disease, pain, behavior, etc. should be evaluated.

Jerry Mendez CAH

However, if the weight loss is in the face of a normal appetite then further suspicion is on gastrointestinal disease or hyperthyroidism. Therefore, recommendations include:

SPECIES

Feline

1. A gastrointestinal malabsorption panel (including cobalamin, folate, TLI and PLI) to Texas A&M GI Laboratory is recommended for further evaluation of GI and pancreatic function.
2. T4 and free T4 are also recommended.

BREED

Domestic Shorthair

Urinalysis and, if indicated based on urinalysis results, urine culture are recommended. If protein is present in an otherwise quiet sediment, protein quantification with a urine protein to creatinine ration is recommended.

SEX

Neutered male

FNA of the enlarged lymph nodes can be considered if the patient's coagulation status is appropriate especially if weight loss is in the face of a normal or increased appetite and the suspicion falls on gastrointestinal disease.

AGE

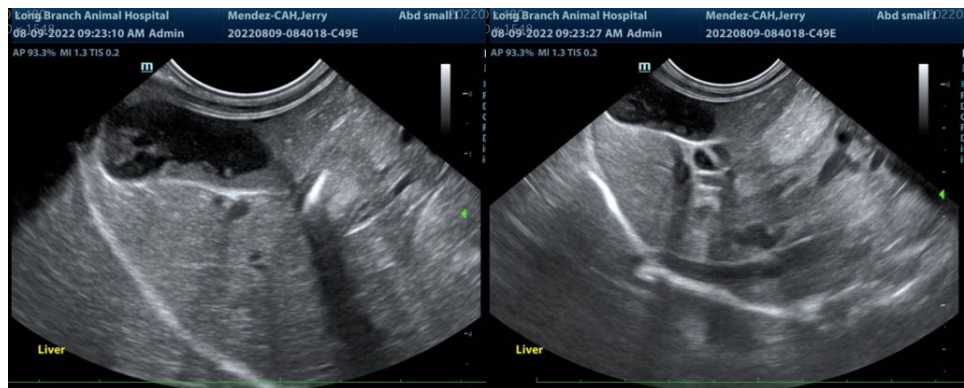
13 years

WEIGHT

7 lbs

INTERPRETED BY

Beth Johnson, DVM
DACVIM

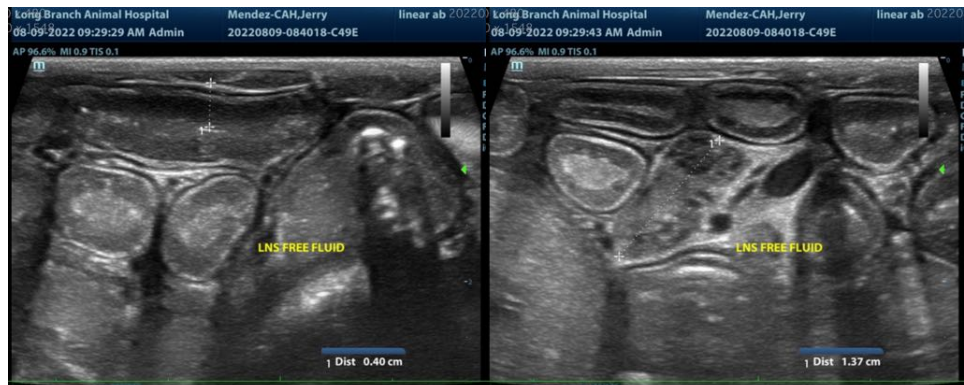


IMAGING PERFORMED BY

Dr. Petrone

HOSPITAL NAME

Long Branch AH



REFERRING VET

Dr. Petrone

INVOICE

32242

DATE

8/9/22



PATIENT

Jerry Mendez CAH

SPECIES

Feline

BREED

Domestic Shorthair

SEX

Neutered male

AGE

13 years

WEIGHT

7 lbs

INTERPRETED BY

Beth Johnson, DVM
DACVIM

IMAGING PERFORMED BY

Dr. Petrone

HOSPITAL NAME

Long Branch AH

REFERRING VET

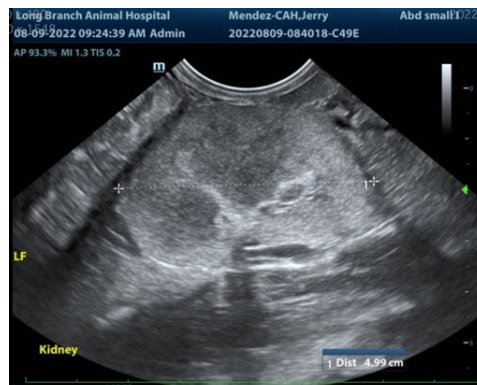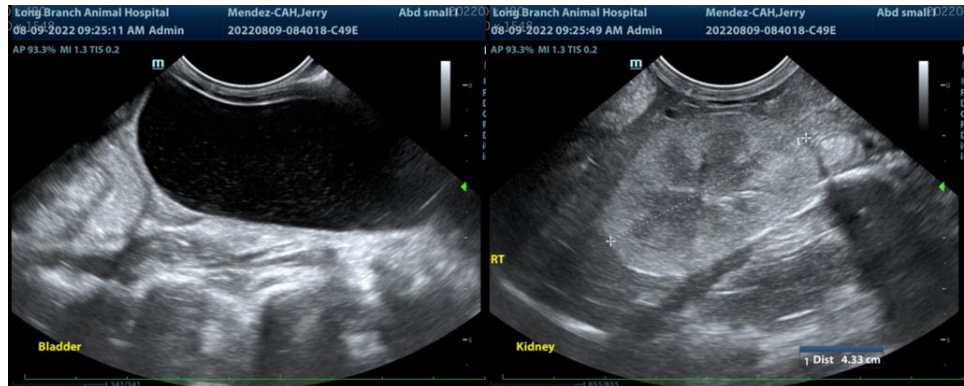
Dr. Petrone

INVOICE

32242

DATE

8/9/22



The information and recommendations provided are based on the images presented by the referring veterinarian/sonographer. No evaluation can be communicated regarding pathology that was not visible in the image/video clips provided.

Thank you for this referral. If the clinical or image interpretation does not parallel your findings or if I can be of any further assistance please contact me.

Beth Johnson, DVM DACVIM

Beth.Johnson@SonoPath.com