

**DATE**

8/8/22

PRESENTING CLINICAL SIGNS

History: 11m history of vomiting that recently has been daily but pet does not go through a week without vomiting since adoption. He has been able to gain weight while with this owner from skinny to correct body condition 4/9.

PATIENT

Meeko Dovel

Current Medications: Cerenia 60mg SID started 8/2/22.

Lab Results: superchem/cbc/t4 all nsf on 8-2-2022.

Date of Previous IntraPet Ultrasound: No previous.

Sedation: Patient was sedated with Dexdomitor.

Stat Report: Not requested.

Imaging Performed By: Andi Parkinson, BS, RDMS.

SPECIES

Canine

BREED

Pit Mix

ULTRASONOGRAPHIC EXAMINATION OF THE ABDOMEN**SEX**

Neutered Male

Urinary System

Urinary bladder is adequately distended with anechoic contents. No masses, inflammatory changes, echogenic sediment or cystoliths are observed. The urinary bladder, trigone and visible pelvic urethra are normal in thickness with a smooth mucosal surface.

AGE

11/30/20

The area of the prostate is examined without evident pathology.

WEIGHT

61 Pounds

Left kidney is normal is size (6.76 cm), shape and echogenicity. It has smooth peripheral margination. There is a normal 1:3 cortex to medulla ratio with appropriate corticomedullary distinction. There is no evidence of pyelectasia, mineral or infarcts observed.

Right kidney is normal is size (6.28 cm), shape and echogenicity. It has smooth peripheral margination. There is a normal 1:3 cortex to medulla ratio with appropriate corticomedullary distinction. There is no evidence of pyelectasia, mineral or infarcts observed.

INTERPRETED BYBeth Johnson, DVM
DACVIM**Adrenal Glands**

Left adrenal gland is normal in size (2.19 cm long x 1.52 cm at cranial pole and 0.55 cm at caudal pole), shape and overall architecture, echogenicity and echotexture. Visible surrounding vasculature appears normal.

HOSPITAL NAME

Everhart VH

Right adrenal gland is normal in size (2.0 cm long x 0.58 cm at cranial pole and 0.55 cm at caudal pole), shape and overall architecture, echogenicity and echotexture. Visible surrounding vasculature appears normal.

REFERRING VET

Dr. Farris

Spleen

Spleen is subjectively normal in size with a normal smooth capsular contour. Parenchyma is appropriately finely textured and homogenous with normal echogenicity relative to surrounding tissue (hyperechoic to liver). No focal nodules or masses are observed. Splenic vasculature appears normal.

INVOICE

16792

Liver

Liver is subjectively normal in size with normal smooth curvilinear peripheral contour. Parenchyma is appropriately hypoechoic to the spleen in echogenicity and appropriately mildly coarse and homogenous in echotexture. No focal lesions are observed. Visible vasculature and biliary tree appear normal without distension or congestion.

Gallbladder is non-distended in size. The wall is smooth without visible thickening. Luminal contents are primarily anechoic. There is no evidence of cystic or common bile duct dilation.

Gastrointestinal

The visible stomach wall is normal in thickness and layering. The lumen of the stomach is empty with no evidence of obstruction, foreign material or infiltrative disease. Pyloric outflow tract appears patent.

The visible small intestines are normal in wall thickness and layering. Small intestinal motility appears adequate (1-3 contractions per min). The lumen of the small intestine is empty with no evidence of obstruction, foreign material or infiltrative disease.

The visible colon is normal in wall thickness and layering. Contents are consistent with normal formed feces and gas. There is some strong acoustic shadowing consistent with residual barium most likely.

Pancreas

The observed pancreas appears appropriately isoechoic to surrounding omental fat. Visible capsule is smooth and normal in contour. Visible pancreatic parenchyma is homogenous and unremarkable. There is no visible pancreatic duct dilation. There is no evidence of active peripancreatic inflammation.

Free Abdomen

Cranial abdominal, mesenteric and sublumbar lymph nodes are prominent in size with swollen capsular contour. Normal elongated shape (length to width ratio) is maintained. There is no loss of parenchymal detail. No appreciable free fluid is noted in these images.

ULTRASONOGRAPHIC FINDINGS

- Reactive cranial abdominal, mesenteric and sublumbar lymph nodes – infiltrative neoplastic disease cannot be ruled out but is considered less likely. This may be normal age variant, however, chronic reactive lymphadenopathy, secondary to inflammatory infectious versus other GI disease cannot be ruled out.
- Otherwise, this is an unremarkable/normal abdomen with no visible foreign material, obstructive pattern, plication, etc. to indicate a chronic foreign body, hiatal hernia, etc., as was suspected based on radiographs. However, a chronic obstruction, hiatal hernia versus other cannot be definitively ruled out.

INTERPRETATION OF THE FINDINGS & FURTHER RECOMMENDATIONS

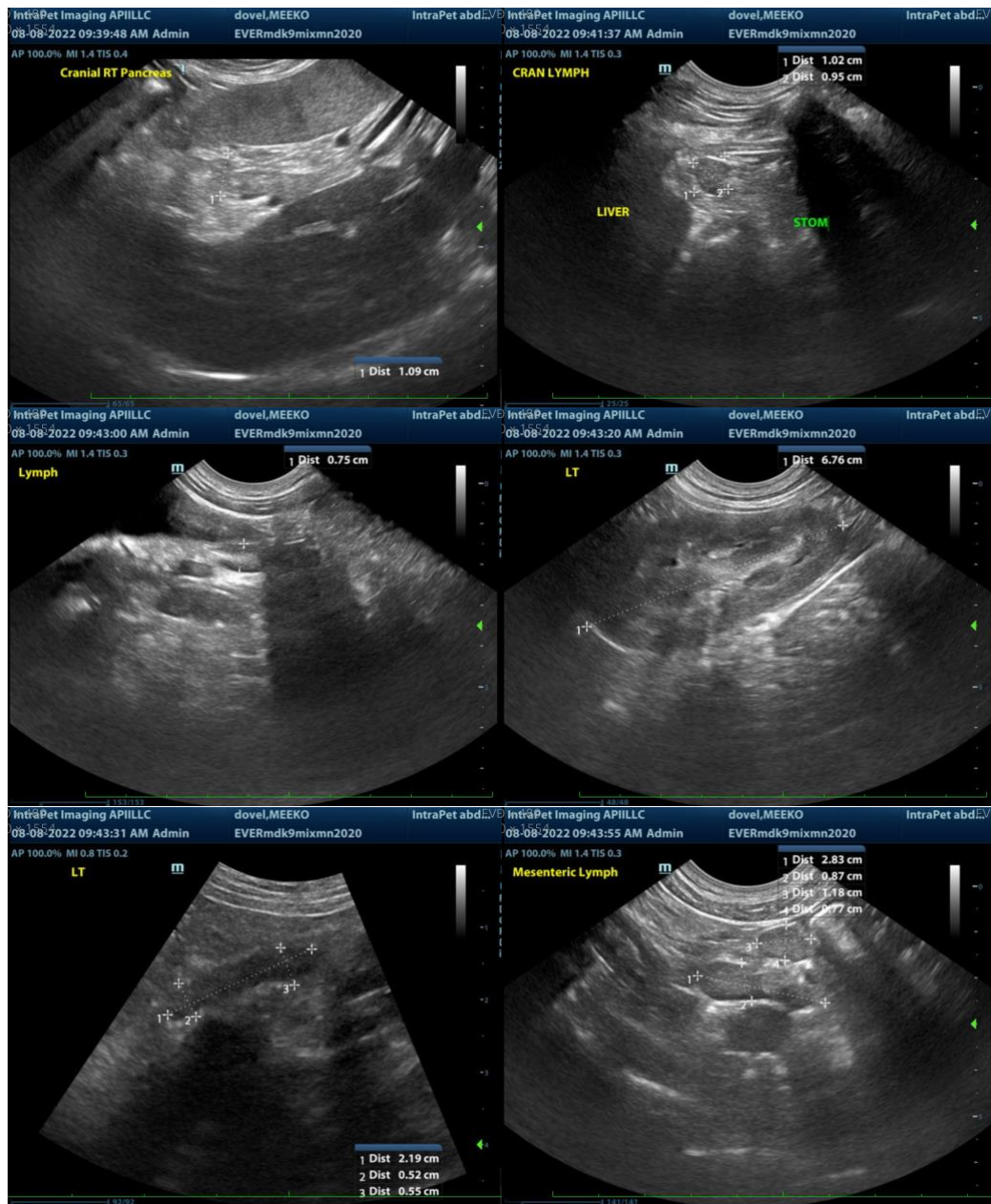
Recommendations for this patient include a workup of potential gastrointestinal disease contributing to the chronic vomiting with a gastrointestinal malabsorption panel (including cobalamin, folate, TLI and PLI) to Texas A&M GI Laboratory is recommended for further evaluation of GI and pancreatic function. A fecal enteropathogen PCR panel to Texas A&M GI Laboratory could be considered for further evaluation of possible infectious disease.

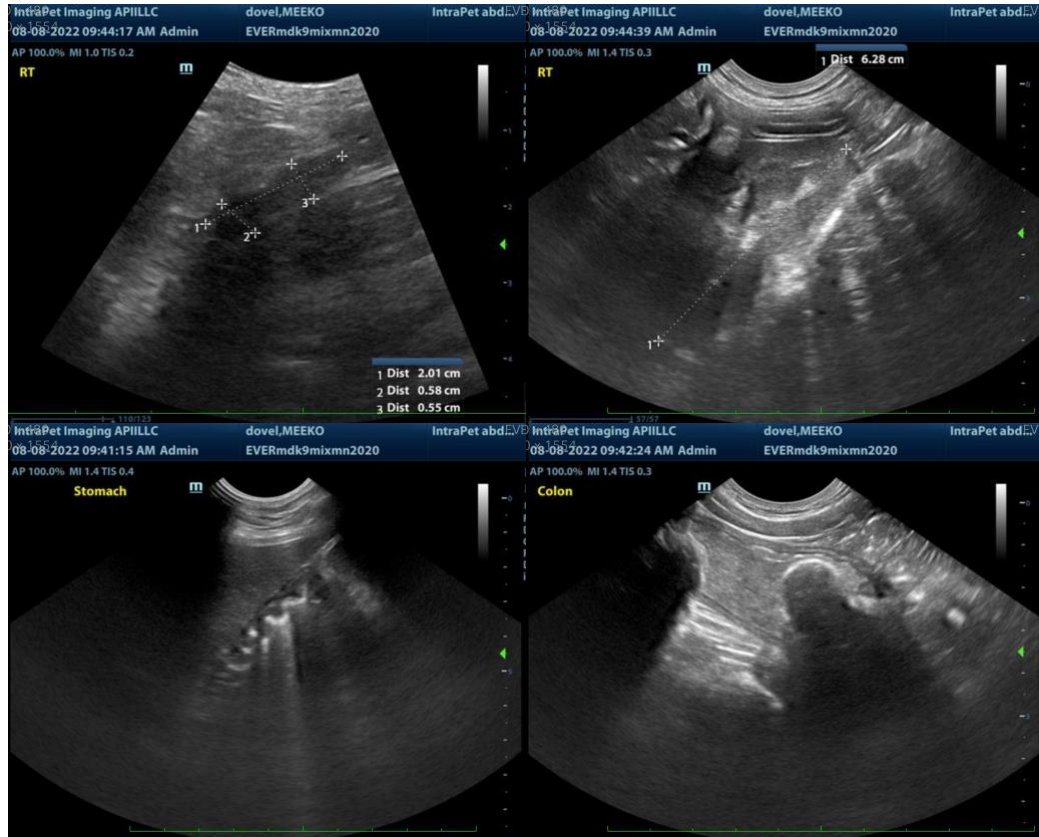
In the meantime, if not already tried, diet trials using patient response to gauge success are recommended. Diets to consider include a bland easy to digest diet, a low fat diet, a novel or hydrolyzed protein diet, and so on.

If an underlying infectious or parasitic disease is not diagnosed, especially if there is evidence of malabsorption or maldigestion on the gastrointestinal panel, and diet transitions don't help alleviate clinical signs, further investigation of the suspect chronic foreign body or hiatal hernia mentioned from the previous barium study, may be warranted in the form of an exploratory laparotomy, despite a relatively

normal ultrasound.

Full thickness biopsies of the stomach and bowel are recommended if surgery is pursued and an underlying cause for the vomiting is not determined at the time of surgery.





The information and recommendations provided are based on the images presented by the referring veterinarian. No evaluation can be communicated regarding pathology that was not visible in the image/video clips provided.

Thank you for this referral. If the clinical or image interpretation does not parallel your findings or if I can be of any further assistance please contact me.

Beth Johnson, DVM DACVIM

Beth.Johnson@SonoPath.com