

**DATE**

8/8/22

PRESENTING CLINICAL SIGNS

History: Patient presented for routine PE/update vaccines in March 2022. Per HX: He frequently Vomited, Labwork will be attached but CPL elevated and therapy for pancreatitis was started (while clinical omeprazole/cerenia) diet adjustment.

PATIENT

Maz Czaikowski

Current Medications: Welactin, Dasuquin, PPP -EN

Date of Previous IntraPet Ultrasound: No previous.

Sedation: Not required to complete full diagnostic ultrasound.

Stat Report: Not requested.

Imaging Performed By: Stephanie Warga RDCS, RVT..

SPECIES

Canine

BREED

Tree Walker
Coonhound

SEX

Neutered Male

AGE

2/21/16

WEIGHT

28 Pounds

ULTRASONOGRAPHIC EXAMINATION OF THE ABDOMEN**Urinary System**

Urinary bladder is adequately distended with anechoic contents. No masses, inflammatory changes, echogenic sediment or cystoliths are observed. The urinary bladder, trigone and visible pelvic urethra are normal in thickness with a smooth mucosal surface.

The prostate is normal for a neutered dog.

Left kidney is normal is size (5.78 cm), shape and echogenicity. It has smooth peripheral margination. There is a normal 1:3 cortex to medulla ratio with appropriate corticomedullary distinction. There is no evidence of pyelectasia, mineral or infarcts observed.

Right kidney is normal is size (6.49 cm), shape and echogenicity. It has smooth peripheral margination. There is a normal 1:3 cortex to medulla ratio with appropriate corticomedullary distinction. There is no evidence of pyelectasia, mineral or infarcts observed.

INTERPRETED BY

Beth Johnson, DVM
DACVIM

Adrenal Glands

Left adrenal gland is normal in size (2.67 cm long x 0.58 cm at cranial pole and 0.61 cm at caudal pole), shape and overall architecture, echogenicity and echotexture. Visible surrounding vasculature appears normal.

HOSPITAL NAME

Noah's Ark Vet & BR

Right adrenal gland is normal in size (2.1 cm long x 0.54 cm at cranial pole and 0.59 cm at caudal pole), shape and overall architecture, echogenicity and echotexture. Visible surrounding vasculature appears normal.

REFERRING VET

Dr. Martinez-
Hernandez

Spleen

Spleen is subjectively normal in size with a normal smooth capsular contour. Parenchyma is appropriately finely textured and homogenous with normal echogenicity relative to surrounding tissue (hyperechoic to liver). No focal nodules or masses are observed. Splenic vasculature appears normal.

INVOICE

16797

Liver

Liver is subjectively normal in size with normal smooth curvilinear peripheral contour. Parenchyma is appropriately hypoechoic to the spleen in echogenicity and appropriately mildly coarse and homogenous in echotexture. No focal lesions are observed. Visible vasculature and biliary tree appear normal without distension or congestion.

Gallbladder is moderately distended with anechoic bile as well as suspended and gravity dependent echogenic debris. The wall is smooth without visible thickening. There is no evidence of cystic or CBD dilation. There is no evidence of effusion or inflammation.

Gastrointestinal

The visible stomach wall is normal in thickness and layering. The lumen of the stomach is with no evidence of obstruction, foreign material or infiltrative disease. Pyloric outflow tract appears patent.

The visible small intestines are normal in wall thickness and layering. Small intestinal motility appears adequate (1-3 contractions per min). The lumen of the small intestine is empty with no evidence of obstruction, foreign material or infiltrative disease.

The visible colon is normal in wall thickness and layering. Contents are consistent with normal formed feces and gas.

Pancreas

The observed pancreas appears appropriately isoechoic to surrounding omental fat. Visible capsule is smooth and normal in contour. Visible pancreatic parenchyma is homogenous and unremarkable. There is no visible pancreatic duct dilation. There is no evidence of active peripancreatic inflammation.

Free Abdomen

There is no free fluid noted. The mesenteric lymph nodes are prominent in size with swollen capsular contour. Normal elongated shape (length to width ratio) is maintained. There is no loss of parenchymal detail.

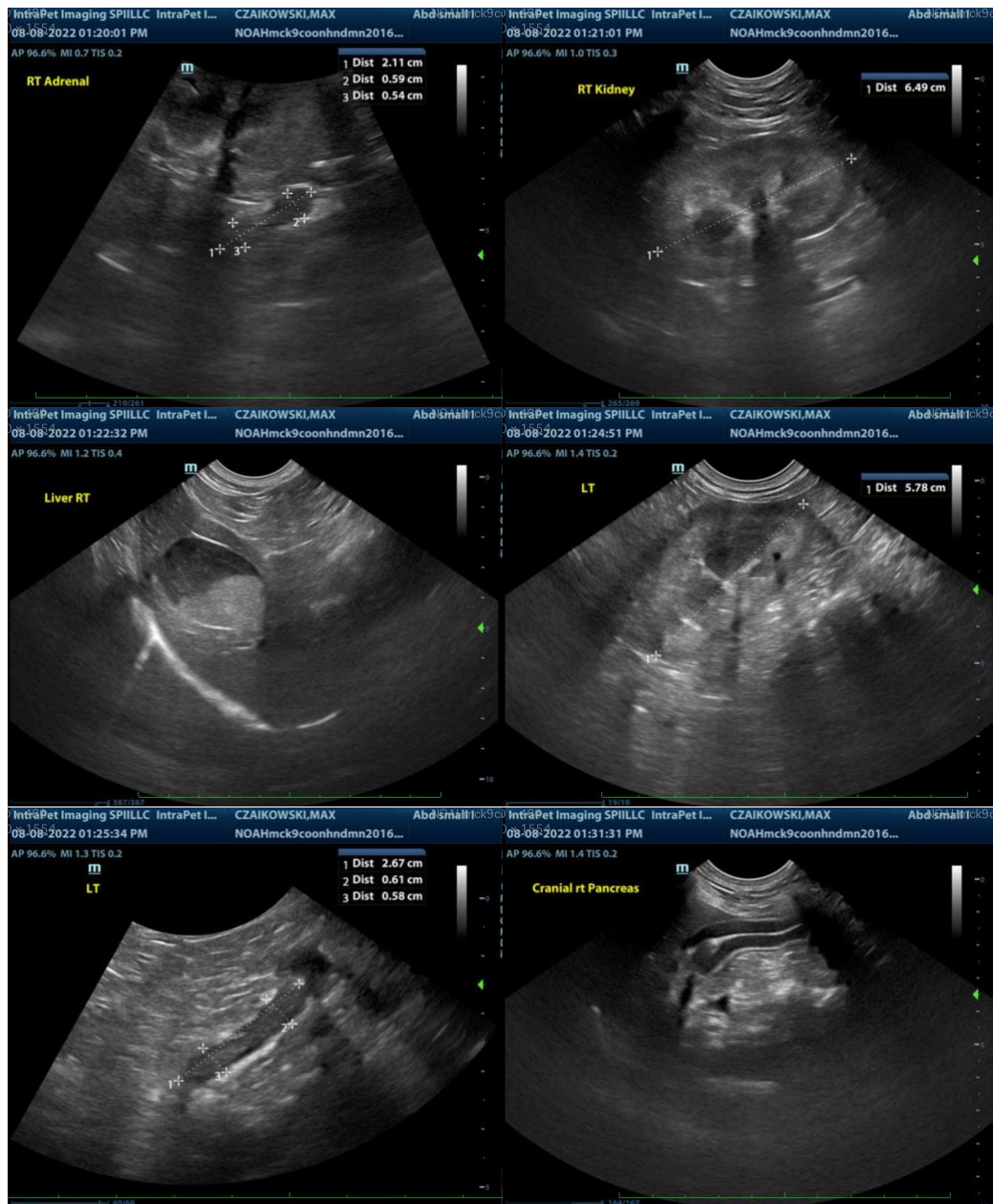
ULTRASONOGRAPHIC FINDINGS

- Gallbladder debris - Cholecystic debris is of unknown clinical significance. It can be seen with biliary stasis from fasting or illness. Cholecystic debris is not necessarily related to hepatobiliary disease. Echogenic bile is most commonly an incidental finding in dogs and should be interpreted in combination with clinical signs such as nausea, inappetence, cranial abdominal discomfort and/or laboratory changes such as increased ALP and/or increased Tbili.
- Reactive mesenteric lymph nodes – infiltrative neoplastic disease cannot be ruled out but is considered less likely

INTERPRETATION OF THE FINDINGS & FURTHER RECOMMENDATIONS

There is no ultrasonographically visible evidence of pancreatitis or gastrointestinal disease to explain this patient's chronic vomiting. However, chronic smoldering pancreatitis cannot be ruled out. Recommendations include:

- A gastrointestinal malabsorption panel (including cobalamin, folate, TLI and PLI) to Texas A&M GI Laboratory is recommended for further evaluation of GI and pancreatic function.
- Continuing the reportedly successful management with the diet change that was implemented.
- A CPL can be increased and even remain increased without pancreatic disease. Therefore, if this patient has returned to normal clinically and there is no evidence of malabsorption or maldigestive disease on the GI panel, no additional follow up is recommended, unless clinical signs return.



The information and recommendations provided are based on the images presented by the referring veterinarian. No evaluation can be communicated regarding pathology that was not visible in the image/video clips provided.

Thank you for this referral. If the clinical or image interpretation does not parallel your findings or if I can be of any further assistance please contact me.

Beth Johnson, DVM DACVIM
Beth.Johnson@SonoPath.com