



PATIENT

Chloe Dong-Nguyen

SPECIES

Canine

BREED

Yorkshire Terrier

SEX

Spayed Female

AGE

9 Years 2 Months

WEIGHT

10.4 Pounds

INTERPRETED BY

Beth Johnson, DVM
DACVIM

IMAGING PERFORMED BY

PMVU

HOSPITAL NAME

Banfield PH Leesburg

REFERRING VET

Dr. Cathy Jarret

INVOICE

16800

DATE

8/8/22

PRESENTING CLINICAL SIGNS

History: Elevated ALKP

Abnormal PE/Chem/CBC/UA Results: ALKP 424.

ULTRASONOGRAPHIC EXAMINATION OF THE ABDOMEN

Urinary System

Urinary bladder is adequately distended. It has a normal uniform wall thickness. Contents include primarily anechoic fluid with occasional echogenic non-shadowing debris, most consistent with exfoliated cells, mucous and/or small blood clots. Both sterile inflammation as well as urinary tract infection can also present with echogenic debris. No masses or cystoliths are observed. The trigone and visible pelvic urethra are normal in thickness with a smooth mucosal surface.

Left kidney is normal is size (3.68 cm), shape and echogenicity. It has smooth peripheral margination. There is a normal 1:3 cortex to medulla ratio with appropriate corticomedullary distinction. There is no evidence of pyelectasia or infarcts observed. Non-obstructive areas of mineralization/nephroliths are noted.

Right kidney is normal is size (4.06 cm), shape and echogenicity. It has smooth peripheral margination. There is a normal 1:3 cortex to medulla ratio with appropriate corticomedullary distinction. There is no evidence of pyelectasia or infarcts observed. Non-obstructive areas of mineralization/nephroliths are noted.

Adrenal Glands

Left adrenal gland is normal in size (0.57 cm at cranial pole and 0.49 cm at caudal pole), shape and overall architecture, echogenicity and echotexture. Visible surrounding vasculature appears normal.

Right adrenal gland is normal in size (0.63 cm at cranial pole and 0.4 cm at caudal pole), shape and overall architecture, echogenicity and echotexture. Visible surrounding vasculature appears normal.

Spleen

Spleen is subjectively normal in size with a normal smooth capsular contour. Parenchyma is appropriately finely textured and homogenous with normal echogenicity relative to surrounding tissue (hyperechoic to liver). No focal nodules or masses are observed. Splenic vasculature appears normal.

Liver

Liver is subjectively enlarged with mildly irregular margins. Parenchyma is heterogenous characterized by multiple poorly defined hypoechoic nodules within otherwise hyperechoic liver parenchyma. Visible vasculature and biliary tree appear normal without distension or congestion.

Gallbladder is moderately distended with anechoic bile as well as suspended and gravity dependent echogenic debris. The wall is smooth without visible thickening. There is no evidence of cystic or CBD dilation. There is no evidence of effusion or inflammation.

Gastrointestinal

The visible stomach wall is normal in thickness and layering. The lumen of the stomach is empty with no evidence of obstruction, foreign material or infiltrative disease. Pyloric outflow tract appears patent.



PATIENT	The visible small intestines are normal in wall thickness and layering. Small intestinal motility appears adequate (1-3 contractions per min). The lumen of the small intestine is empty with no evidence of obstruction, foreign material or infiltrative disease.
Chloe Dong-Nguyen	
SPECIES	The visible colon is normal in wall thickness and layering. Contents are consistent with normal formed feces and gas.
Canine	Pancreas
BREED	The observed pancreas appears appropriately isoechoic to surrounding omental fat. Visible capsule is smooth and normal in contour. Visible pancreatic parenchyma is homogenous and unremarkable. There is no visible pancreatic duct dilation. There is no evidence of active peripancreatic inflammation.
Yorkshire Terrier	Free Abdomen
SEX	There is no evidence of peritoneal effusion. There is no apparent lymphadenopathy.
Spayed Female	ULTRASONOGRAPHIC FINDINGS
AGE	Primary Findings
9 Years 2 Months	<ul style="list-style-type: none"> Heterogenous Liver – These changes are most consistent with benign processes such as nodular hyperplasia, steroid (vacuolar) hepatopathy, extramedullary hematopoiesis or possibly chronic inflammatory disease and less commonly infiltrative round cell or metastatic neoplasia. Gallbladder debris- Cholecystic debris is of unknown clinical significance. It can be seen with biliary stasis from fasting or illness. Cholecystic debris is not necessarily related to hepatobiliary disease. Echogenic bile is most commonly an incidental finding in dogs and should be interpreted in combination with clinical signs such as nausea, inappetence, cranial abdominal discomfort and/or laboratory changes such as increased ALP and/or increased Tbili.
WEIGHT	
10.4 Pounds	
INTERPRETED BY	Secondary Findings
Beth Johnson, DVM DACVIM	<ul style="list-style-type: none"> Nonobstructive nephroliths bilaterally Urinary bladder debris
IMAGING PERFORMED BY	INTERPRETATION OF THE FINDINGS & FURTHER RECOMMENDATIONS
PMVU	Differentials are vast and non-specific. Differentials include, but are not limited to, benign nodular hyperplasia which occurs in 70% of older dogs and often does not result in an abnormal ultrasound, reactive or idiopathic/vacuolar hepatopathy, cholestasis and/or hyperadrenocorticism as well as many chronic non-hepatobiliary diseases such as chronic infections/inflammation from dental disease, IBD, neoplasia, hyperlipidemia, hypothyroidism, chronic pancreatitis, chronic stress, etc.
HOSPITAL NAME	
Banfield PH Leesburg	
REFERRING VET	
Dr. Cathy Jarret	There is no ultrasonographic evidence of cholestasis. Adrenocortical testing such as a low dose dexamethasone suppression test could be considered if clinical signs of hyperadrenocorticism are present. Ursodiol could be considered if gallbladder sludge is noted. A fine needle aspirate of the liver could be considered if patient's coagulation status is appropriate. Otherwise, recommendations include addressing any other concurrent disease and monitoring. If values are progressive, recheck imaging is recommended.
INVOICE	
16800	
DATE	
8/8/22	



PATIENT

Chloe Dong-Nguyen

SPECIES

Canine

BREED

Yorkshire Terrier

SEX

Spayed Female

AGE

9 Years 2 Months

WEIGHT

10.4 Pounds

INTERPRETED BY

Beth Johnson, DVM
DACVIM

IMAGING PERFORMED BY

PMVU

HOSPITAL NAME

Banfield PH Leesburg

REFERRING VET

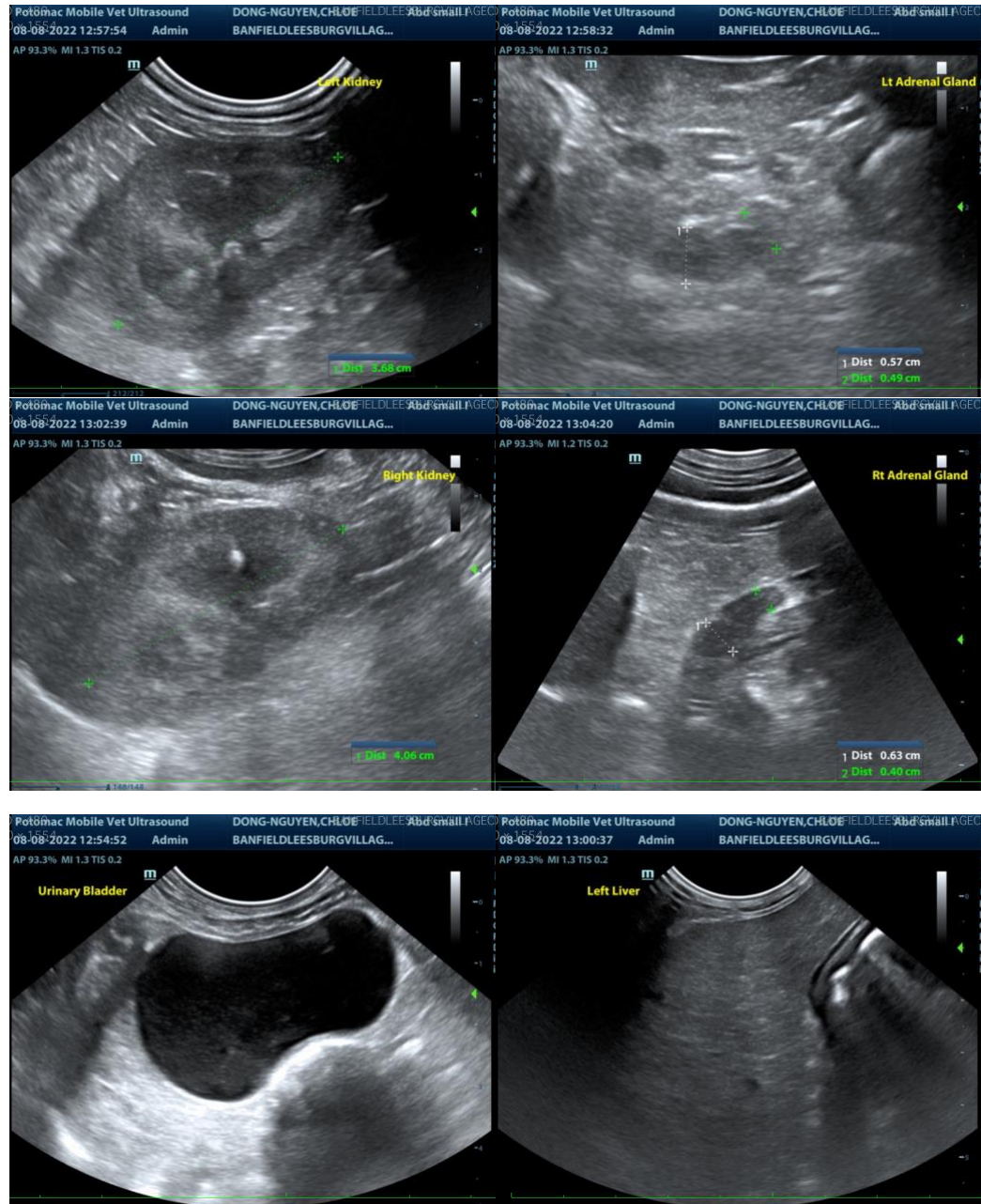
Dr. Cathy Jarret

INVOICE

16800

DATE

8/8/22





PATIENT

Chloe Dong-Nguyen

SPECIES

Canine

BREED

Yorkshire Terrier

SEX

Spayed Female

AGE

9 Years 2 Months

WEIGHT

10.4 Pounds

INTERPRETED BY

Beth Johnson, DVM
DACVIM

IMAGING PERFORMED BY

PMVU

HOSPITAL NAME

Banfield PH Leesburg

REFERRING VET

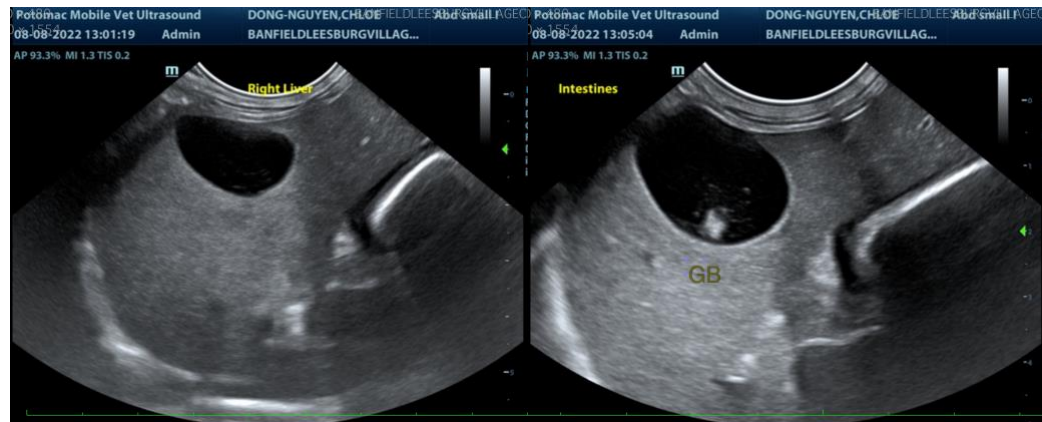
Dr. Cathy Jarret

INVOICE

16800

DATE

8/8/22



The information and recommendations provided are based on the images presented by the referring veterinarian. No evaluation can be communicated regarding pathology that was not visible in the image/video clips provided.

Thank you for this referral. If the clinical or image interpretation does not parallel your findings or if I can be of any further assistance please contact me.

Beth Johnson, DVM DACVIM

Beth.Johnson@SonoPath.com