

**DATE**

8/8/22

PRESENTING CLINICAL SIGNS

History: Hx of IBD and pancreatitis (Dr. Polf scanned in 2019). Inappetence, vomiting, diarrhea on/off since 7/26/22.

PATIENT

Cammie Rothschild

Current Medications: N/A.

Lab Results: ALT elevated 1482, FPLi >50 today (<3.5 normal).

Date of Previous IntraPet Ultrasound: No previous.

SPECIES

Feline

Sedation: Not required to complete full diagnostic ultrasound.

Stat Report: Not requested.

Imaging Performed By: Andi Parkinson, BS, RDMS.

BREED

DSH

ULTRASONOGRAPHIC EXAMINATION OF THE ABDOMEN**SEX**

Spayed Female

Urinary System

Urinary bladder is adequately distended. It has a normal uniform wall thickness. Contents include primarily anechoic fluid with occasional echogenic non-shadowing debris, most consistent with incidental suspended lipid in a cat, possibly combined with exfoliated cells, mucous and/or small blood clots. Both sterile inflammation as well as urinary tract infection can also present with echogenic debris. No masses or cystoliths are observed. The trigone and visible pelvic urethra are normal in thickness with a smooth mucosal surface.

AGE

11/1/08

Kidneys are overall normal in size and shape with smooth peripheral margination. A normal 1:3 cortex to medulla ratio is maintained. The medulla and cortices are uniform in texture with some mild increased cortical echogenicity and mild loss of corticomedullary distinction, expected in this age patient. There is no evidence of pyelectasia, mineral or infarcts observed. The left kidney measures 4.16 cm. The right kidney measures 4.09 cm.

WEIGHT

9.2 Pounds

INTERPRETED BYBeth Johnson, DVM
DACVIM**Adrenal Glands**

The area of the adrenal glands is examined without evident pathology.

HOSPITAL NAME

Timonium AH

Spleen

Spleen is subjectively normal in size with a normal smooth capsular contour. Parenchyma is appropriately finely textured and homogenous with normal echogenicity relative to surrounding tissue (hyperechoic to liver). No focal nodules or masses are observed. Splenic vasculature appears normal.

REFERRING VET

Dr. Stephens

Liver

Liver is subjectively enlarged (swollen contour) without disruption of architecture. It has a normal homogenous echotexture. Parenchyma is diffusely hyperechoic characterized by less prominent than normal portal vein walls and increased echogenicity relative to the spleen and falciform fat. No focal lesions are observed. Multifocal intrahepatic biliary mineral is noted.

INVOICE

16789

Gallbladder is moderately distended with anechoic bile as well as suspended and gravity dependent echogenic debris. The wall is smooth without visible thickening. The cystic and common bile duct are tortuous and contain mineral debris/sand, possibly a nonobstructive cholecystolith with no evidence of pathologic distention. There is no evidence of effusion or inflammation.

Gastrointestinal

The visible stomach wall is normal in thickness and layering. The lumen of the stomach is empty with no evidence of obstruction, foreign material or infiltrative disease. Pyloric outflow tract appears patent.

The visible small intestine demonstrates areas of thick muscularis layer relative to mucosa (disruption of the normal 1:3 muscularis:mucosa ratio). Small intestinal submucosa is slightly irregular, thick and hyperechoic. The small intestinal submucosa is slightly irregular, thick and hyperechoic with some early/hazy emerging loss of layering suspected in some bowel loops. The lumen of the small intestine is empty with no evidence of obstruction or foreign material.

The visible colon is normal in wall thickness and layering. Contents are consistent with normal formed feces and gas.

Pancreas

The observed pancreas is prominent (enlarged) in size, hypoechoic to surrounding tissue and irregular in shape with a swollen undulating contour. Pancreatic duct dilation is noted. Enhanced hyperechoic ill-defined surrounding fat is noted.

Free Abdomen

The mesenteric lymph nodes are prominent, hypoechoic and round in appearance, differentials for which include both infiltrative neoplasia, as well as reactive lymphadenopathy. No appreciable free fluid is noted.

ULTRASONOGRAPHIC FINDINGS

Primary Findings

- Acute pancreatitis with concurrent gallbladder debris and biliary sludge/mineral. This finding is consistent with cholangiohepatitis/"triaditis".
- Hyperechoic hepatomegaly – This appearance is most consistent with benign hepatic lipidosis. Infiltrative disease such as amyloidosis or round cell neoplasia, such as mast cell tumor or less likely, lymphoma, is also possible.
- Gastrointestinal lymphoma (suspect) pattern – Thick muscularis has been reported with infiltrative bowel disease including both benign inflammatory disease as well as infiltrative neoplasia such as lymphoma. Given the suspected early emerging loss of layering, infiltrative neoplasia is considered more likely, but benign IBD cannot be ruled out without tissue sampling.

Secondary Findings

- Urinary bladder debris
- Age-related kidney changes

INTERPRETATION OF THE FINDINGS & FURTHER RECOMMENDATIONS

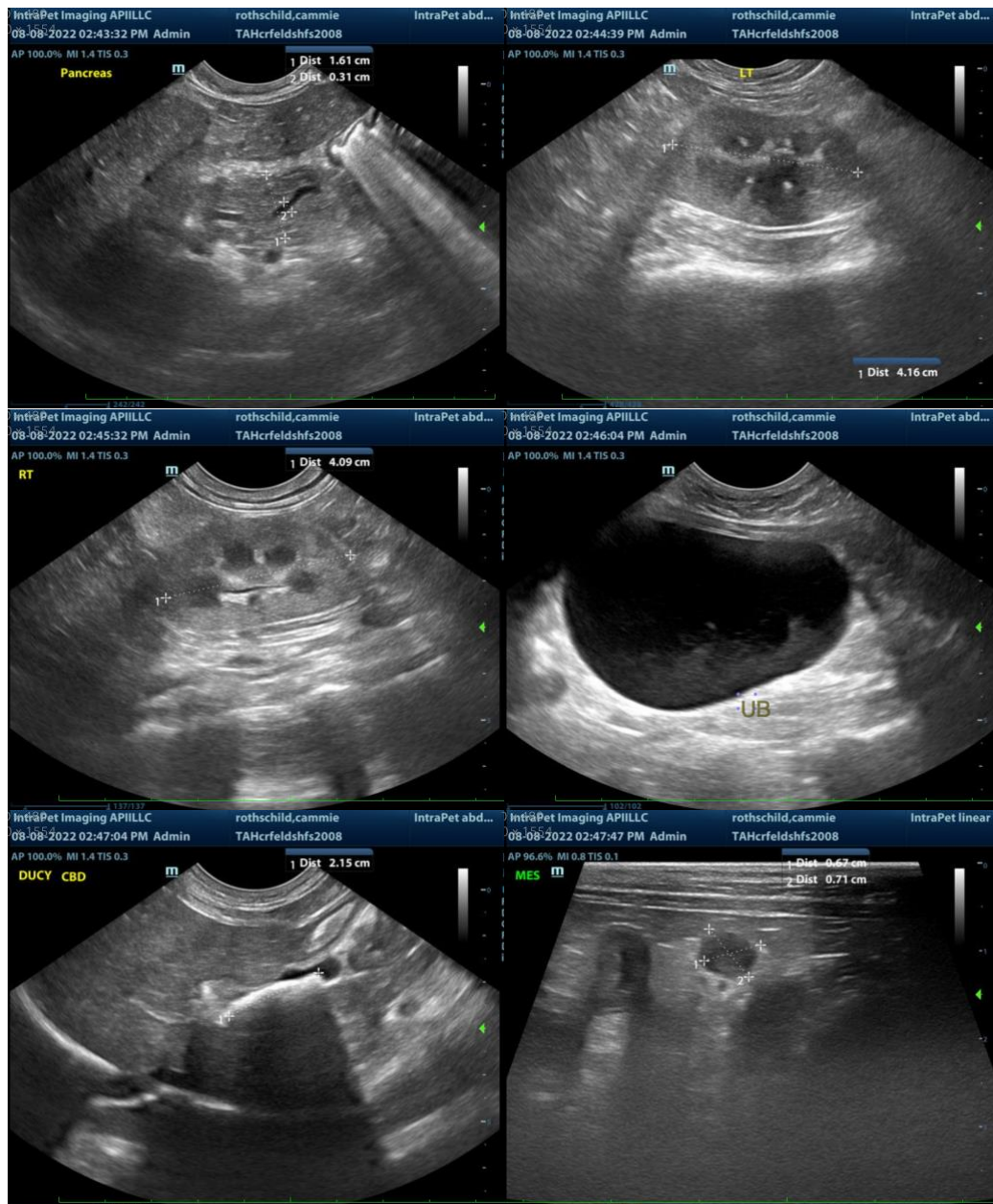
Diagnostic recommendations for this patient include:

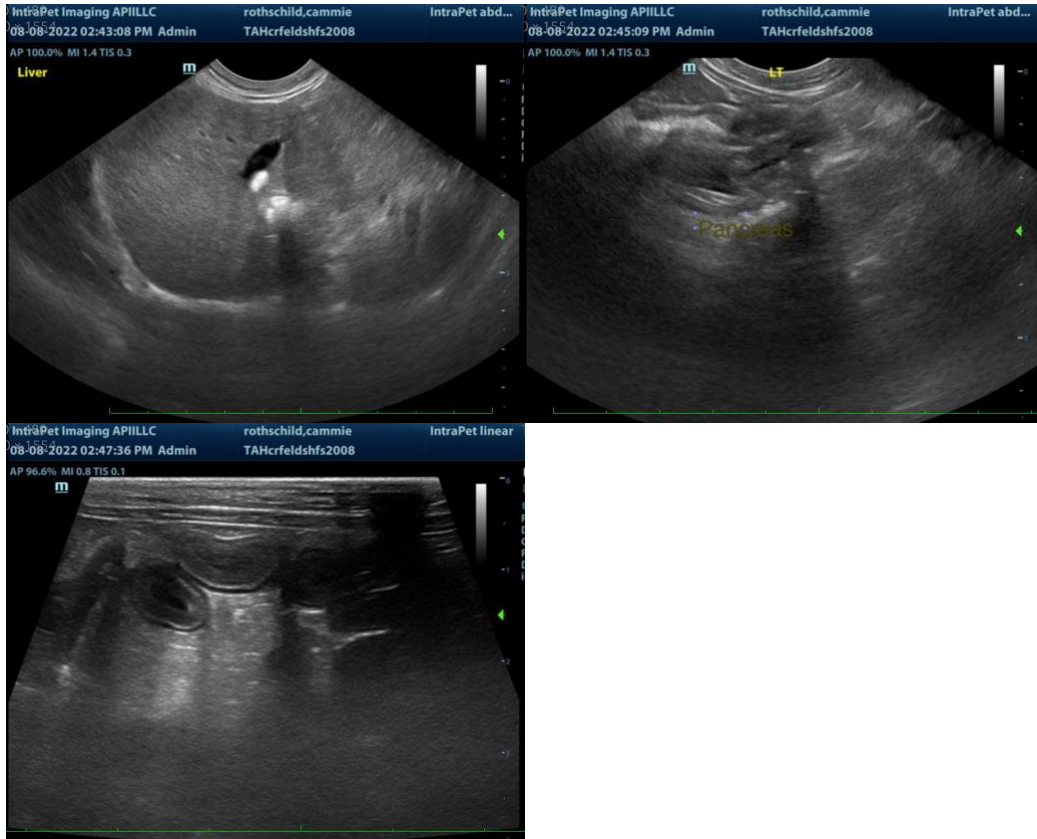
- A gastrointestinal malabsorption panel (including cobalamin, folate, TLI and PLI) to Texas A&M GI Laboratory is recommended for further evaluation of GI and pancreatic function.
- A fine needle aspirate of the liver, if patient coagulation status is appropriate.

- Urinalysis and, if indicated based on urinalysis results, urine culture are recommended. If protein is present in an otherwise quiet sediment, protein quantification with a urine protein to creatinine ration is recommended.

In the meantime, medical management of pancreatitis/cholangitis/"triaditis" with anti-emetics, gastroprotectants, appetite stimulants or nutritional support (including a feeding tube) as needed, pain management, broad spectrum antibiotics, and fluid therapy is recommended.

If a diagnosis is not obtained cytologically from the liver and/or improvement is not noted with medical management/supportive care, ultimately, biopsies of the gastrointestinal tract +/- liver, etc. may be necessary for a definitive diagnosis, and therefore appropriate medical management.





The information and recommendations provided are based on the images presented by the referring veterinarian. No evaluation can be communicated regarding pathology that was not visible in the image/video clips provided.

Thank you for this referral. If the clinical or image interpretation does not parallel your findings or if I can be of any further assistance please contact me.

Beth Johnson, DVM DACVIM
Beth.Johnson@SonoPath.com