

**DATE PRESENTING CLINICAL SIGNS**

8/7/23 History: Vomiting coffee ground material.

PATIENT

Sophie Fraistat

Current Medications: None listed.
 Date of Previous IntraPet Ultrasound: No previous.
 Sedation: Not required to complete full diagnostic ultrasound.
 Stat Report: Not requested.

SPECIES

Feline

Imaging Performed By: Stephanie Warga RDCS, RVT.

BREED

DSH

Urinary System

Urinary bladder is adequately distended with anechoic contents. No masses, inflammatory changes, echogenic sediment or cystoliths are observed. The urinary bladder, trigone and visible pelvic urethra are normal in thickness with a smooth mucosal surface. Except for, along the ventral apex, there is an approximately 1.2 cm long hyperechoic irregular density with an anechoic center that measures 0.4 cm long and appears to communicate with the lumen of the bladder.

AGE

4/15/14

Left kidney is normal in size (3.75 cm), shape and echogenicity. It has smooth peripheral margination. There is a normal 1:3 cortex to medulla ratio with appropriate corticomedullary distinction. There is no evidence of pyelectasia or infarcts observed. A nonobstructive nephrolith is observed.

WEIGHT

12.5 Pounds

Right kidney is normal in size (3.72 cm), shape and echogenicity. It has smooth peripheral margination. There is a normal 1:3 cortex to medulla ratio with appropriate corticomedullary distinction. There is no evidence of pyelectasia, mineral or infarcts observed.

INTERPRETED BYBeth Johnson, DVM
DACVIM**Adrenal Glands**

Left adrenal gland is normal in size (0.37 cm), shape and overall architecture, echogenicity and echotexture. Visible surrounding vasculature appears normal.

Right adrenal gland is normal in size (0.43 cm), shape and overall architecture, echogenicity and echotexture. Visible surrounding vasculature appears normal.

HOSPITAL NAME

North Laurel AH

Spleen

Spleen is subjectively normal in size with a normal smooth capsular contour. Parenchyma is appropriately finely textured and homogenous with normal echogenicity relative to surrounding tissue (hyperechoic to liver). No focal nodules or masses are observed. Splenic vasculature appears normal.

REFERRING VET

Dr. Steere

Liver

Liver is subjectively normal in size with normal smooth curvilinear peripheral contour. Parenchyma is appropriately hypoechoic to the spleen in echogenicity and appropriately mildly coarse and homogenous in echotexture. No focal lesions are observed. Visible vasculature and biliary tree appear normal without distension or congestion.

INVOICE

23841

Gallbladder is non-distended in size. The wall is smooth without visible thickening. Luminal contents are primarily anechoic. There is no evidence of cystic or common bile duct dilation.

Gastrointestinal

The visible stomach wall is normal in thickness and layering. The lumen of the stomach is empty with no evidence of obstruction, foreign material or infiltrative disease. Pyloric outflow tract appears patent.

The visible small intestine demonstrates areas of mildly thick muscularis layer relative to mucosa (disruption of the normal 1:3 muscularis:mucosa ratio). Small intestinal submucosa is slightly irregular, thick and hyperechoic, without evident loss of layering appreciated. The lumen of the small intestine is empty with no evidence of obstruction or foreign material.

The visible colon is normal in wall thickness and layering. Contents are consistent with normal formed feces and gas.

Pancreas

The observed pancreas appears appropriately isoechoic to surrounding omental fat. Visible capsule is smooth and normal in contour. Visible pancreatic parenchyma is homogenous and unremarkable. There is no visible pancreatic duct dilation. There is no evidence of active peripancreatic inflammation.

Free Abdomen

There is no evidence of peritoneal effusion. There is no apparent lymphadenopathy.

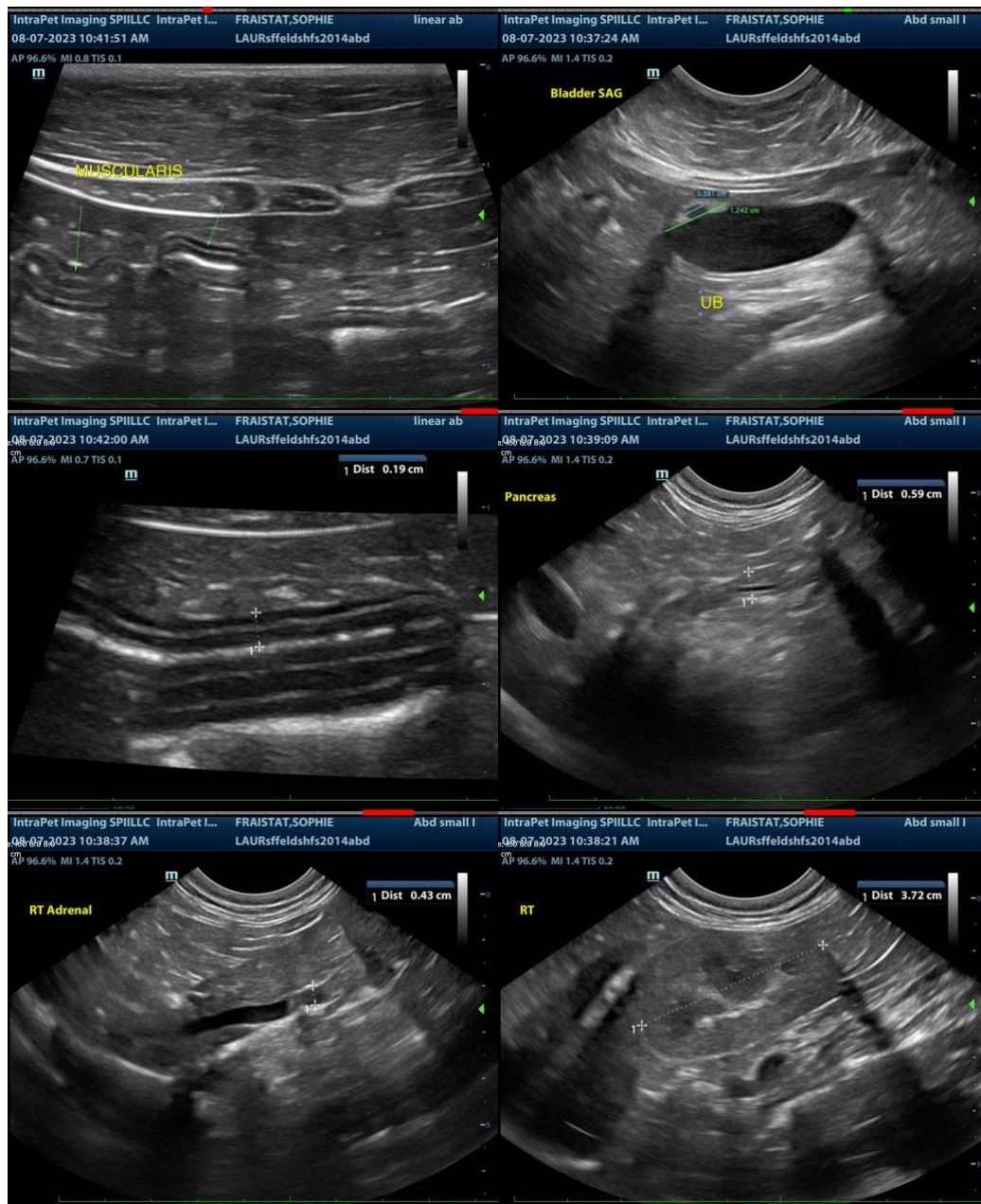
ULTRASONOGRAPHIC FINDINGS

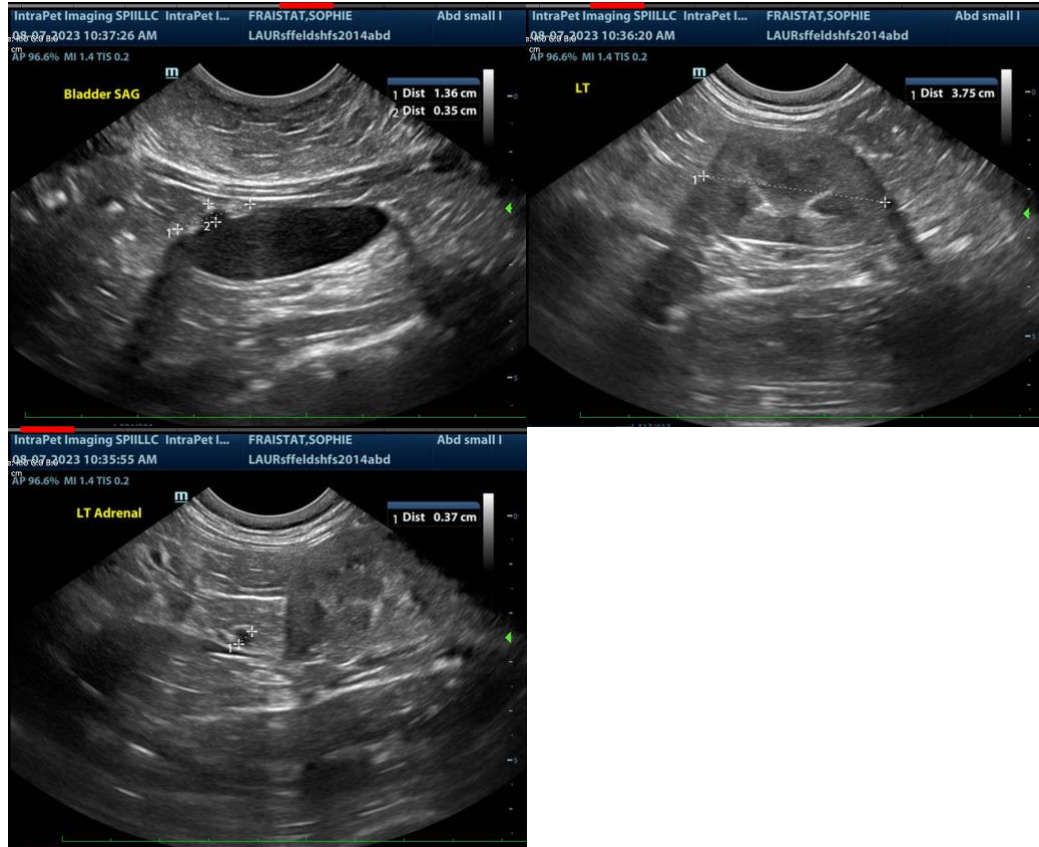
- There is no definitive evidence of ulcerative disease, however, microulceration cannot be definitively ruled out ultrasonographically, and is suspected based on patients reported history.
- Mild/subtle inflammatory bowel disease (IBD) pattern – Thick muscularis has been reported with infiltrative bowel disease including both benign inflammatory disease as well as infiltrative neoplasia such as lymphoma. No aggressive lymphadenopathy, loss of layering, etc. is noted to make lymphoma more probable, but lymphoma cannot be definitively ruled out without tissue sampling.
- The irregular area involving the urinary bladder wall, described above, could represent a persistent urachus vs diverticulum or even pseudodiverticulum, and if unknown clinical consequence, and should be interpreted in combination with further evaluation, as recommended below.
- Nonobstructive nephrolith in the left kidney.

INTERPRETATION OF THE FINDINGS & FURTHER RECOMMENDATIONS

- If not recently evaluated, a general metabolic health screen is recommended to include CBC/chemistry panel, electrolytes, and urinalysis and, if indicated based on urinalysis results, urine culture is recommended. If protein is present in an otherwise quiet sediment, protein quantification with a urine protein to creatinine ration is recommended.
- Assessment of this patients coagulation status should be considered.
- Given this patients reported hematemesis, a baseline cortisol is recommended. If baseline cortisol is less than 2, a full ACTH stimulation test is recommended to rule out hypoadrenocorticism.
- A gastrointestinal malabsorption panel (including cobalamin, folate, TLI and PLI) to Texas A&M GI Laboratory is recommended for further evaluation of GI and pancreatic function.
- Ultimately, pending results, further evaluation of the GI tract via upper GI gastroscopy/endoscopy for further visualization and biopsies may be necessary.

- In the meantime, empirical medical management recommendations include antiemetics, gastroprotectants, including sucralfate, appetite stimulation (if necessary) and empirical deworming with a 5-day course of Panacur.
- The bladder wall change is likely incidental and not related to this patient's gastrointestinal signs. Further considerations, pending urinalysis results, could include monitoring vs further imaging, including contrast study or even cystoscopy.





The information and recommendations provided are based on the images presented by the referring veterinarian. No evaluation can be communicated regarding pathology that was not visible in the image/video clips provided.

Thank you for this referral. If the clinical or image interpretation does not parallel your findings or if I can be of any further assistance please contact me.

Beth Johnson, DVM DACVIM
info@SonoPath.com