

**DATE PRESENTING CLINICAL SIGNS**

8/4/22 Weight loss, chronic vomiting, polyphagia for the last few months/year.

**PATIENT** Current Medications: None listed.

Lab Results: See attached.

Linx Jones Date of Previous IntraPet Ultrasound: No previous.

Sedation: Not required to complete full diagnostic ultrasound.

Stat Report: Not requested.

**SPECIES**

Feline

**ULTRASONOGRAPHIC EXAMINATION OF THE ABDOMEN****Urinary System****BREED**

The urinary bladder is moderately distended with anechoic contents. No masses, inflammatory changes, echogenic sediment or cystoliths are observed. The urinary bladder, trigone and visible pelvic urethra are normal in thickness with a smooth mucosal surface.

DSH

**SEX**

Neutered Male

The right kidney is normal in size (3.79 cm), shape and echogenicity. It has smooth peripheral margination. There is a normal 1:3 cortex to medulla ratio with appropriate corticomedullary distinction. There is no evidence of pyelectasia, mineral or infarcts observed.

**AGE**

7/19/07

The left kidney is normal in size (3.68 cm), shape and echogenicity. It has smooth peripheral margination. There is a normal 1:3 cortex to medulla ratio with appropriate corticomedullary distinction. There is no evidence of pyelectasia, mineral or infarcts observed.

**WEIGHT**

9.62 Pounds

**Adrenal Glands**

The right adrenal gland is normal in size (0.29 cm), shape and contour. Corticomedullary structure is unremarkable. Visible surrounding vasculature appears normal.

**INTERPRETED BY**

Beth Johnson, DVM  
DACVIM

The left adrenal gland is normal in size (0.35 cm), shape and contour. Corticomedullary structure is unremarkable. Visible surrounding vasculature appears normal.

**IMAGING PERFORMED BY**

Stephanie Warga  
RDMS, RVT

**Spleen**

Spleen is subjectively large in size with a swollen and scalloped/undulating capsular contour. Multifocal coalescing nodules are noted throughout the parenchyma. Splenic vasculature appears normal. Enhanced hyperechoic surrounding fat is noted.

**HOSPITAL NAME**

Bayside AMC

**Liver**

The liver is subjectively normal in size with normal smooth curvilinear peripheral contour. Parenchyma is appropriately hypoechoic to the spleen in echogenicity and appropriately mildly coarse and homogenous in echotexture. No focal lesions are observed. Visible vasculature and biliary tree appear normal without distension or congestion.

**REFERRING VET**

Dr. DeLozier

The gallbladder is non-distended in size. The wall is smooth without visible thickening. Luminal contents are primarily anechoic. There is no evidence of cystic or common bile duct dilation.

**INVOICE**

40181

**Gastrointestinal**

The stomach wall is normal in thickness (canine < 0.5 cm and feline < 0.4 cm) and layering. The lumen of the stomach is empty with no evidence of obstruction, foreign material or infiltrative disease. Pyloric outflow tract appears patent.

The visible small intestine demonstrates areas of thick muscularis layer relative to mucosa (disruption of the normal 1:3 muscularis:mucosa ratio). Small intestinal submucosa is slightly irregular, thick and hyperechoic, without evident loss of layering appreciated. The lumen is mildly fluid and gas distended.

The visible colon is normal in wall thickness (< 0.2 cm) and layering. Contents are consistent with normal formed feces and gas.

### ***Pancreas***

The observed pancreas appears appropriately isoechoic to surrounding omental fat. The capsule is mildly irregular in shape. Parenchyma is mildly heterogenous and coarse. There is no visible pancreatic duct dilation. There is no evidence of active peripancreatic inflammation.

### ***Free Abdomen***

There is no evidence of free peritoneal effusion noted in these images.

There is no apparent lymphadenopathy noted in these images.

No pericardial effusion or heart based tumors noted in these images.

## **PRIMARY FINDINGS**

- **Honeycomb Spleen** – This finding is strongly suggestive of infiltrative disease such as round cell neoplasia. Benign disease cannot be ruled out but is considered less likely.
- **Gastrointestinal lymphoma (suspect) pattern** – Thick muscularis has been reported with infiltrative bowel disease including both benign inflammatory disease as well as infiltrative neoplasia such as lymphoma. Given the concurrent pathology noted, infiltrative neoplasia is considered more likely, but benign IBD cannot be ruled out without tissue sampling.

## **SECONDARY FINDINGS**

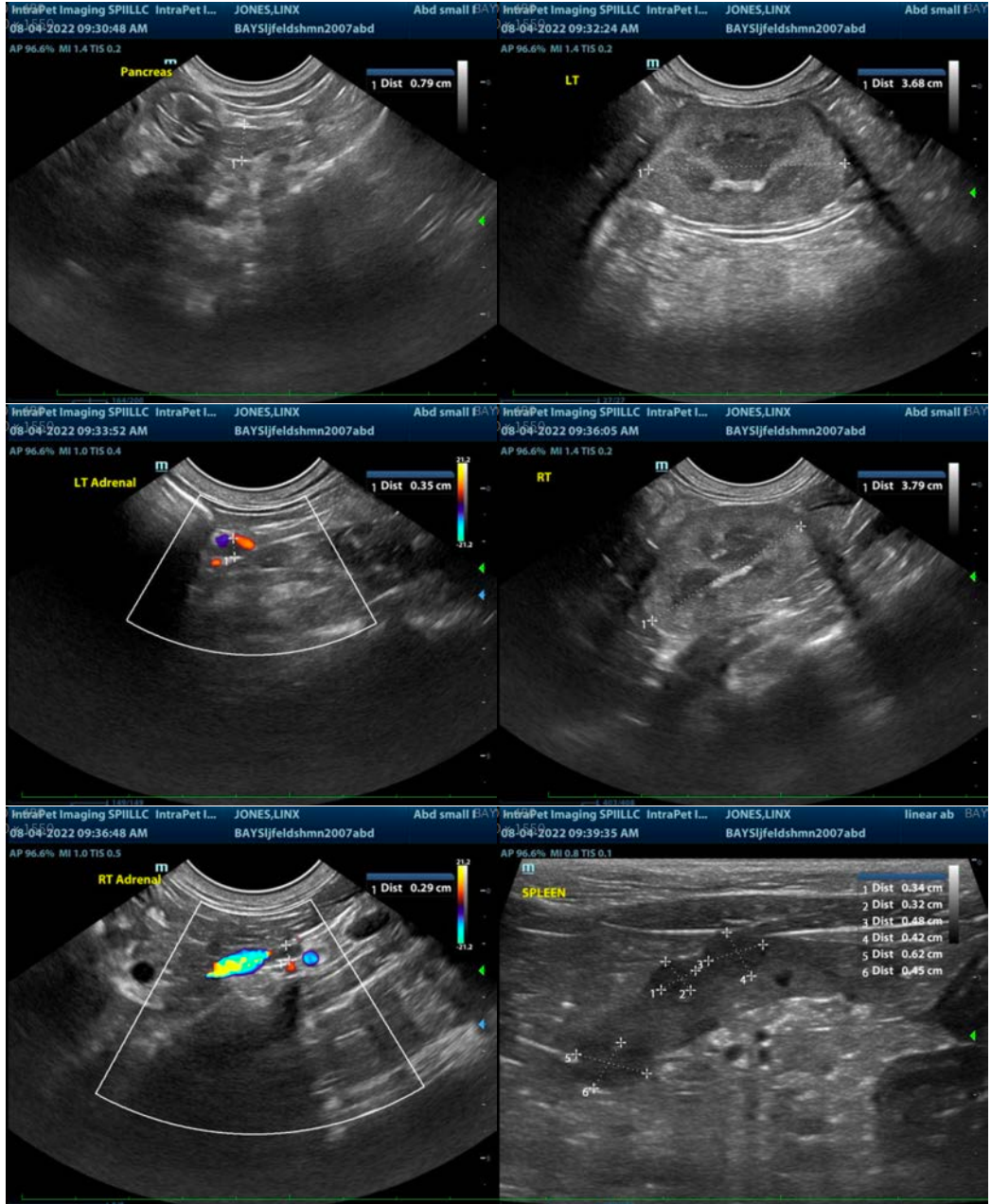
- **Pancreatic age-related remodeling** – Mild irregularities are consistent with benign age-related change. Low-grade smoldering chronic pancreatitis cannot be ruled out and should be suspected in the face of appropriate clinical signs.

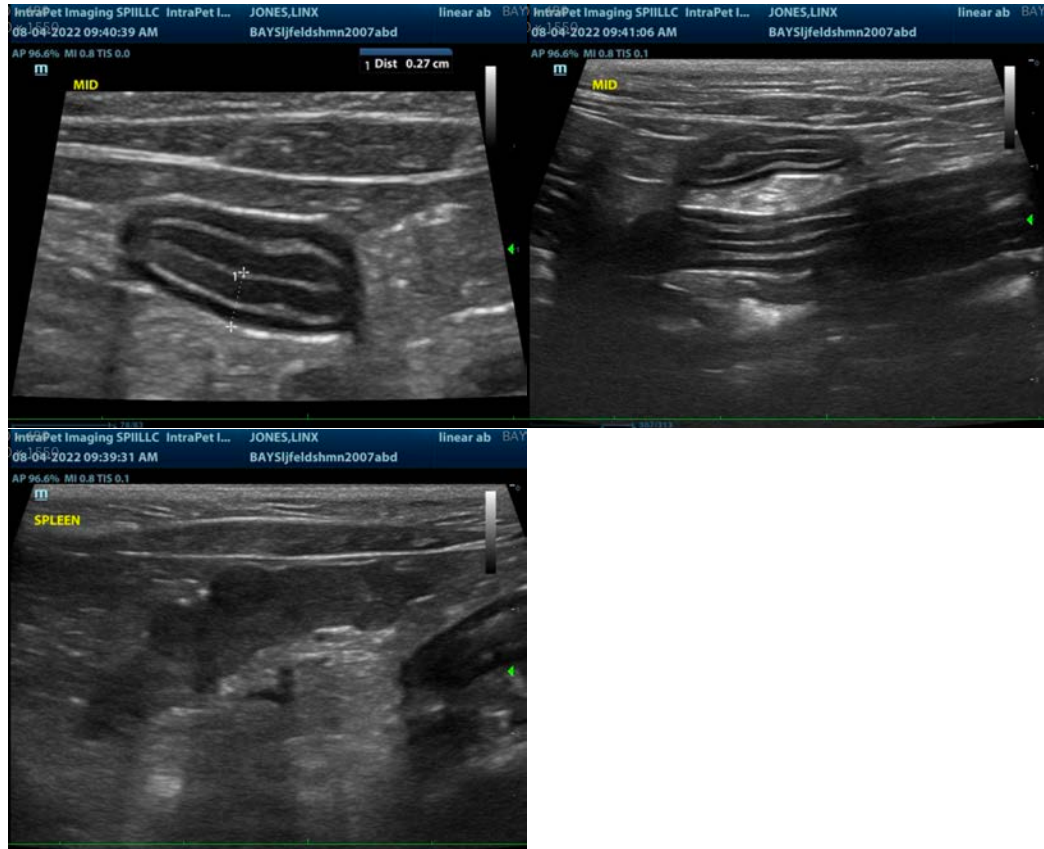
## **INTERPRETATION OF THE FINDINGS & FURTHER RECOMMENDATIONS**

The weight loss in the face of an increased appetite appears most likely secondary to infiltrative bowel disease with lymphoma being the top differential given the concurrent splenic pathology. However, given the reported T4 level with clinical signs, a free T4 is indicated to rule out early or concurrent hyperthyroidism.

A gastrointestinal malabsorption panel (including cobalamin, folate, TLI and PLI) to Texas A&M GI Laboratory is recommended for further evaluation of GI and pancreatic function.

A fine needle aspirate of the spleen is recommended if patient's coagulation status is appropriate. If lymphoma is not diagnosed cytologically, biopsies of the GI tract, being sure to include ileum, if possible, are recommended to definitively diagnose and therefore manage the infiltrative bowel disease.





The information and recommendations provided are based on the images presented by the referring veterinarian/sonographer. No evaluation can be communicated regarding pathology that was not visible in the image/video clips provided.

Thank you for this referral. If the clinical or image interpretation does not parallel your findings or if I can be of any further assistance please contact me.

**Beth Johnson, DVM, DACVIM**  
Beth.Johnson@sonopath.com