

**DATE PRESENTING CLINICAL SIGNS**

8/4/22

Presented to ER last week in July for ADR/vomiting/lethargy. ER treated supportively for pancreatitis. Patient was placed on insulin CRI d/t hyperglycemia while hospitalized, discharged w/ codeine, cerenia and entice. Presented to Bayside for vomiting and anorexia on 8/2/22. Treated supportively w/ LRS SQF, cerenia injectable, metronidazole, and clavamox. Per Owner no improvement noted.

PATIENT

Baby Kaltic

Current Medications: Clavamox, Metronidazole.
Lab Results: Attached.**SPECIES**

Canine

Date of Previous IntraPet Ultrasound: No previous.

Sedation: Not required to complete full diagnostic ultrasound.

Stat Report: Offered and declined.

Imaging Performed By: Stephanie Warga RDCS, RVT.

BREED

Pug Mix

ULTRASONOGRAPHIC EXAMINATION OF THE ABDOMEN**Urinary System**

Urinary bladder is only mildly distended (empty). Visible contents are anechoic. Urinary bladder wall is unable to be fully assessed for pathology without further distension. No visible masses or cystoliths are observed. The trigone and visible pelvic urethra are normal thickness with a smooth mucosal surface. If there are urinary signs and/or concern for urinary bladder pathology, reassessment after complete filling is recommended.

AGE

5/4/11

Left kidney is normal is size (4.65 cm), shape and echogenicity. It has smooth peripheral margination. There is a normal 1:3 cortex to medulla ratio with appropriate corticomedullary distinction. Multiple acute and chronic infarcts are noted in the left kidney. There is no evidence of pyelectasia, mineral or infarcts observed. The left kidney is surrounded by enhanced, hyperechoic fat and mesentery.

WEIGHT

24.8 lbs

Right kidney is normal is size (4.88 cm), shape and echogenicity. It has smooth peripheral margination. There is a normal 1:3 cortex to medulla ratio with appropriate corticomedullary distinction. There is no evidence of pyelectasia, mineral or infarcts observed.

INTERPRETED BYBeth Johnson, DVM
DACVIM**Adrenal Glands**

Left adrenal gland is unable to be well visualized due to the concurrent pathology of other organs in the area.

HOSPITAL NAME

Bayside AMC

Right adrenal gland is normal in size (1.56 cm long, 0.46 cm at cranial pole and 0.35 cm at caudal pole), shape and overall architecture, echogenicity and echotexture. Visible surrounding vasculature appears normal.

REFERRING VET

Dr. Beigel

Spleen

Spleen contains multiple, small, hypoechoic nodules as well as a well-demarcated, hypoechoic to anechoic lesion in the midbody at the end of a splenic vein thrombus.

INVOICE

32159

Liver

Liver is subjectively normal in size with normal smooth curvilinear peripheral contour. Parenchyma is appropriately hypoechoic to the spleen in echogenicity and appropriately mildly coarse and homogenous in echotexture. No focal lesions are observed. Visible vasculature and biliary tree appear normal without distension or congestion.

Gallbladder is non-distended in size. The wall is smooth without visible thickening. Luminal contents are primarily anechoic. There is no evidence of cystic or common bile duct dilation.

Gastrointestinal

Attached to the stomach appearing to be within the gastric wall there is a large, walled off, heterogenous, partially fluid filled lesion that is concerning for an intramural abscess. The lesion does not have good vascularity. The visible stomach wall is normal in thickness and layering.

The visible small intestines are normal in wall thickness and layering. Small intestinal motility appears adequate (1-3 contractions per min). The lumen of the small intestine is empty with no evidence of obstruction, foreign material or infiltrative disease.

The visible colon is normal in wall thickness (< 0.2 cm) and layering. Contents are consistent with normal formed feces and gas.

Pancreas

The observed pancreas is prominent (enlarged) in size, hypoechoic to surrounding tissue and irregular in shape with a swollen undulating contour. Enhanced hyperechoic ill-defined surrounding fat is noted.

Free Abdomen

There is no apparent lymphadenopathy noted in these images.

There is a large amount of enhanced, hyperechoic mesentery and a scant amount of anechoic free fluid surrounding the suspected gastric intramural abscess, the inflamed pancreas as well as the suspected infarct in the spleen.

ULTRASONOGRAPHIC FINDINGS

Primary Findings

- Large, avascular, heterogenous, partially cavitated intramural lesion associated with the stomach. This is most concerning for an intramural abscess versus other.
- Acute pancreatitis.
- Splenic vein thrombus with suspected splenic infarct. Splenic abscess versus other cannot be ruled out.
- Renal infarcts.
- Large amount of enhanced hyperechoic fat and mesentery surrounding these lesions and suggestive for focal peritonitis.

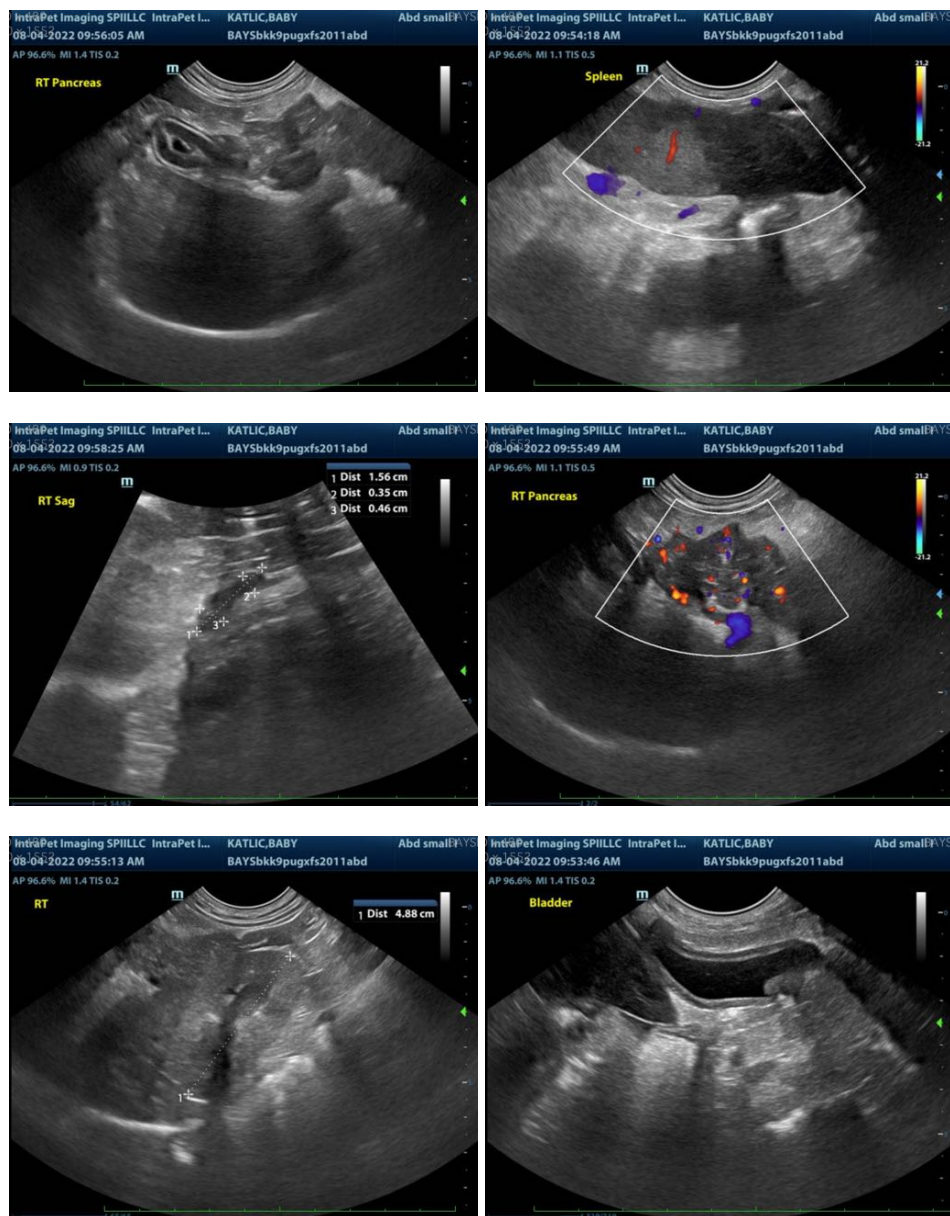
INTERPRETATION OF THE FINDINGS & FURTHER RECOMMENDATIONS

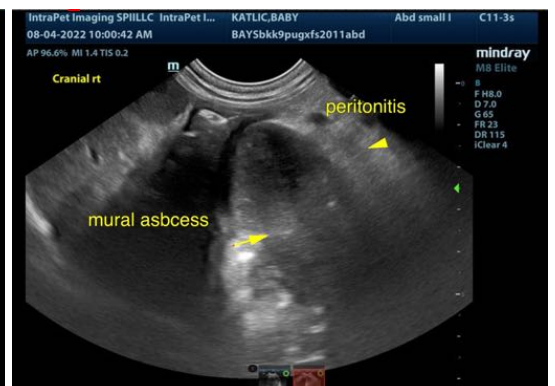
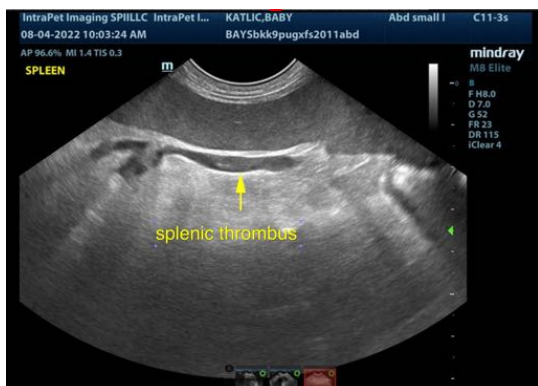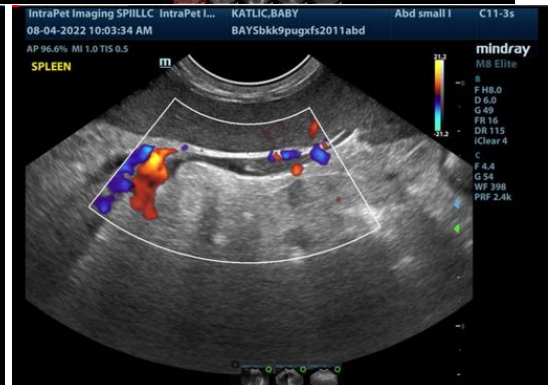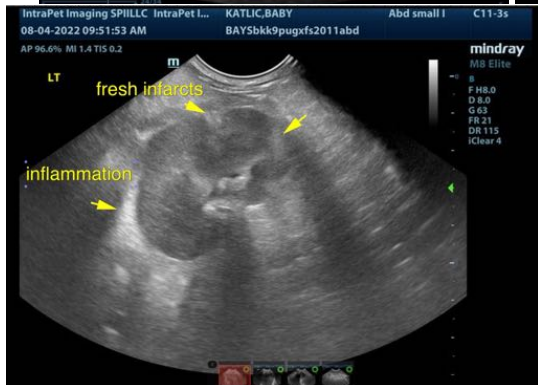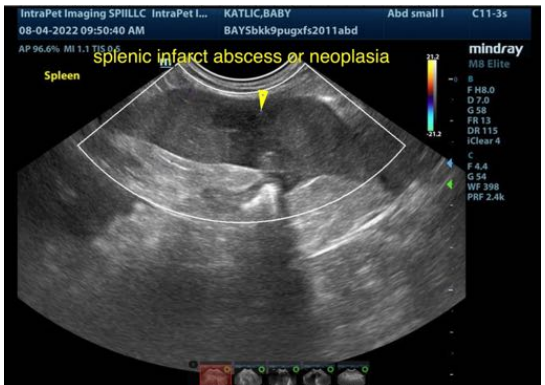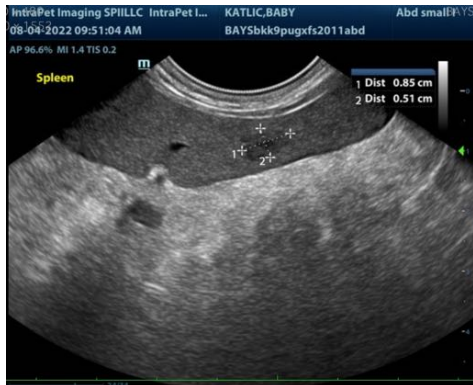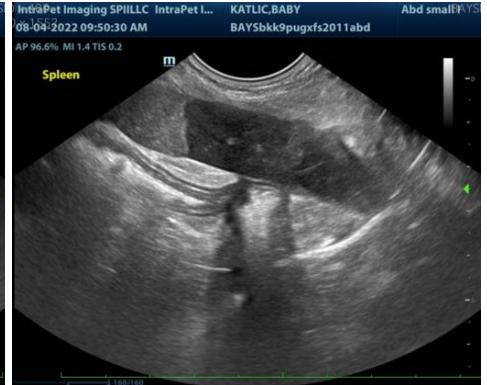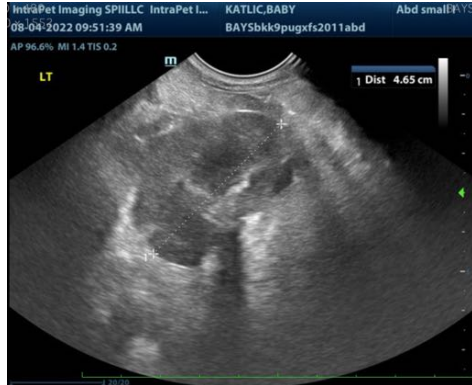The lesions described in this patient are severe. Therefore, aggressive medical management is recommended in the form of antiemetics, gastric protectants, appetite stimulants or nutritional support as needed, pain management, broad spectrum four quadrant antibiotic coverage and fluid therapy. If possible a fresh frozen plasma transfusion is recommended. Hyperbaric oxygen therapy could be beneficial.

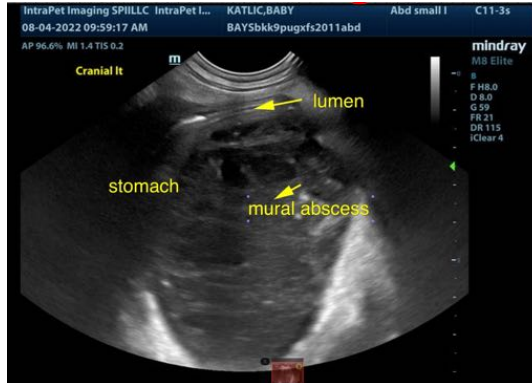
If possible prior to beginning antibiotic therapy a FNA of the suspected gastric abscess for cytology as well as culture is recommended. Given the suspected hypercoagulable state based on multiple infarcts noted a urinalysis is recommended with a follow-up urine protein to creatinine ratio if there is protein present in an

otherwise quiet urinalysis as well as a blood pressure if not recently evaluated. If coagulation status is appropriate anti-thrombotic such as low dose aspirin or Clopidogrel should be considered as part of this patient's acute therapy.

FNA of spleen and infarcted kidney could also be considered to look for evidence of neoplasia. Ultimately, pending results and after stabilization, surgery will likely be required for gastric wall resection, splenectomy, etc.







The information and recommendations provided are based on the images presented by the referring veterinarian. No evaluation can be communicated regarding pathology that was not visible in the image/video clips provided.

Thank you for this referral. If the clinical or image interpretation does not parallel your findings or if I can be of any further assistance please contact me.

Beth Johnson, DVM DACVIM
Beth.Johnson@SonoPath.com