

**DATE PRESENTING CLINICAL SIGNS**

8/30/22 8/1/22 - Presented for routine exam and vaccines. Owner stated she is eating. PE - Weight - 28.4 lbs, lost 5 lbs since last year; lenticular sclerosis, few dermal cysts, dental calculus/gingivitis

PATIENT

Coco Decker Current Medications: 8/1/22: Amoxicillin (250 mg) - 1 BID x 14 days
Metronidazole (250 mg) - 1/2 BID x 14 days, SAME - 200 mg PO SID
Milk Thistle - Give 500 mg PO SID.

SPECIES

Canine Lab Results: 8/1/22 - CBC/Chem 11 - ALT - 2405, ALKP - 1125; 4DX-negative. 8/24/22 - CBC/Chem 11 - PLT-559, ALT-1999, ALKP - 1751
Date of Previous IntraPet Ultrasound: No previous.
Sedation: Not required to complete full diagnostic ultrasound.
Stat Report: Not requested.

BREED

Mixed

ULTRASONOGRAPHIC EXAMINATION OF THE ABDOMEN**SEX**

Spayed Female **Urinary System**
The urinary bladder is moderately distended with anechoic contents. No masses, inflammatory changes, echogenic sediment or cystoliths are observed. The urinary bladder, trigone and visible pelvic urethra are normal in thickness with a smooth mucosal surface.

AGE

5/16/11 The right kidney is normal in size (5.62 cm), shape and echogenicity. It has smooth peripheral margination. There is a normal 1:3 cortex to medulla ratio with appropriate corticomedullary distinction. There is no evidence of pyelectasia, mineral or infarcts observed.

WEIGHT

28.4 Pounds The left kidney is normal in size (5.07 cm), shape and echogenicity. It has smooth peripheral margination. There is a normal 1:3 cortex to medulla ratio with appropriate corticomedullary distinction. There is no evidence of pyelectasia, mineral or infarcts observed.

INTERPRETED BY

Beth Johnson, DVM
DACVIM

Adrenal Glands

The right adrenal gland is normal in size (1.85 cm long x 1.0 cm at the cranial pole and 0.70 cm at the caudal pole), shape and contour. Corticomedullary structure is unremarkable. Visible surrounding vasculature appears normal.

IMAGING PERFORMED BY

Stephanie Warga
RDCS, RVT

The left adrenal gland is normal in size (2.3 cm long x 0.89 cm at the cranial pole and 0.71 cm at the caudal pole), shape and contour. Corticomedullary structure is unremarkable. Visible surrounding vasculature appears normal.

HOSPITAL NAME

Parkville AH

Spleen

The spleen is subjectively normal in size with a normal smooth capsular contour. Parenchyma is appropriately finely textured and homogenous with normal echogenicity relative to surrounding tissue (hyperechoic to liver). No focal nodules or masses are observed. Splenic vasculature appears normal.

REFERRING VET

Dr. Suter

Liver

The liver is subjectively normal in size with normal smooth curvilinear peripheral contour. Parenchyma is appropriately hypoechoic to the spleen in echogenicity and appropriately mildly coarse and homogenous in echotexture. Visible vasculature and biliary tree appear normal without distension or congestion.

INVOICE

40860

**Note, see other - the lesion appears to be attached to the liver.

The gallbladder is non-distended in size. The wall is smooth without visible thickening. Luminal contents are primarily anechoic. There is no evidence of cystic or common bile duct dilation.

Gastrointestinal

The stomach wall is normal in thickness (canine < 0.5 cm and feline < 0.4 cm) and layering. The lumen of the stomach is empty with no evidence of obstruction, foreign material or infiltrative disease. Pyloric outflow tract appears patent.

The visible small intestines are normal in wall thickness and layering (canine duodenum < 0.5 cm and feline duodenum < 0.4 cm; other < 0.3 cm). Small intestinal motility appears adequate (1-3 contractions per min). The lumen of the small intestine is empty with no evidence of obstruction, foreign material or infiltrative disease.

The visible colon is normal in wall thickness (< 0.2 cm) and layering. Contents are consistent with normal formed feces and gas.

Pancreas

The pancreatic parenchyma is appropriately isoechoic to surrounding tissue. Visible capsule is smooth and normal in contour. There is no visible pancreatic duct dilation. There is no evidence of active peripancreatic inflammation.

Free Abdomen

There is no evidence of free peritoneal effusion noted in these images.

There is no apparent lymphadenopathy noted in these images.

In the cranial mid abdomen, there is a large, at least 12 cm in diameter, mixed, heterogeneous, vascular mass that appears to be attached to and extending from the left lateral liver. Origination from the spleen or other cannot be definitively ruled out, but appears in these images less likely than the left liver.

ULTRASONOGRAPHIC FINDINGS

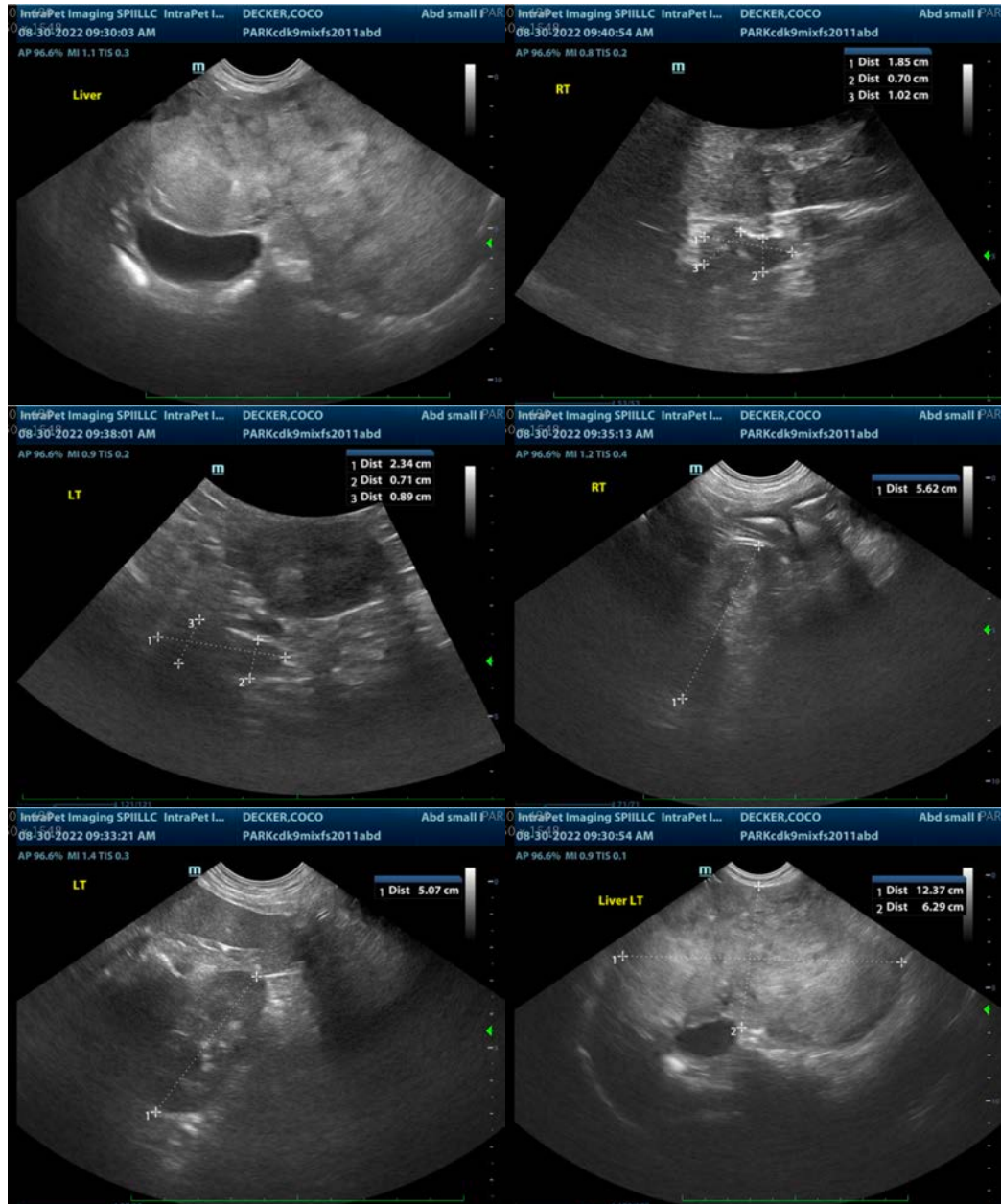
- Large, mixed cranial abdominal mass believed to be originating from the left lateral caudal liver – Top differential is infiltrative neoplasia such as primary hepatocellular carcinoma versus sarcoma versus infiltrative round cell neoplasia versus other. A benign lesion can't be ruled out without tissue sampling, but is considered much less likely.

INTERPRETATION OF THE FINDINGS & FURTHER RECOMMENDATIONS

Three view thoracic radiographs are recommended for further assessment of cardio-pulmonary status as well as to further evaluate for any evidence of metastatic disease, if not recently evaluated.

A fine needle aspirate of the mass is recommended if patient's coagulation status is appropriate.

Ultimately, an exploratory laparotomy for planned mass removal/liver lobectomy is likely necessary to treat this patient. Given the location combined with the normal appearing remaining liver, resectability seems probable, yet cannot be definitively guaranteed, and a pre-surgical staging abdominal CT scan could be considered if more definitive resectability guidance is desired prior to surgery.



The information and recommendations provided are based on the images presented by the referring veterinarian/sonographer. No evaluation can be communicated regarding pathology that was not visible in the image/video clips provided.

Thank you for this referral. If the clinical or image interpretation does not parallel your findings or if I can be of any further assistance please contact me.

Beth Johnson, DVM, DACVIM
Beth.Johnson@sonopath.com